

# Early Detection of Cerebral Ischemia During Carotid Endarterectomy Using Transcranial Doppler Sonography and Somatosensory Evoked Potentials

A. Thiel, W. Russ, H. W. Nestle\*, and G. Hempelmann

Department of Anaesthesiology and Intensive Care Medicine

\* Department of Cardiovascular Surgery  
Justus-Liebig-University, Giessen, FRG

## Summary

Cerebral function during carotid endarterectomy can reliably be monitored using somatosensory evoked potentials (SEP). Transcranial Doppler sonography (TCD) is a noninvasive method providing on-line data about cerebral hemodynamics. The combination of both techniques during carotid surgery is helpful in evaluating the hemodynamic ("input") and the functional ("output") consequences of carotid clamping within a short time.

In the present report, combined TCD and SEP monitoring early detected left hemispheric ischemia in a 68-year-old woman subjected to left carotid endarterectomy. The impairment of cerebral perfusion occurred before carotid clamping due to an intraoperative thrombosis of the left internal carotid artery as could be revealed after declamping. A temporary shunt was not inserted. Postoperatively, the patient had a new transient neurological deficit.

In this case, TCD correctly indicated cerebral ischemia as confirmed by SEP recording. For carotid artery surgery, combined TCD and SEP may be helpful in detecting those patients who will profit from temporary shunting if this is not done routinely.

## Früherkennung einer zerebralen Ischämie mittels transkranieller Dopplersonographie und somatosensorisch evozierten Potentialen während Karotisoperation

Die intraoperative Überwachung der Hirnfunktion bei Thrombendarterektomien der Karotisgabel basiert im wesentlichen auf hämodynamisch bzw. elektrophysiologisch orientierten Methoden. Die Ableitung der somatosensorisch evozierten Potentiale (SEP) nach Stimulation des N. medianus zeigt die funktionellen Auswirkungen einer drohenden zerebralen Ischämie mit hoher Sensitivität und Spezifität an. Mit der transkraniellen Dopplersonographie (TCD) steht seit einigen Jahren ein noninvasives Verfahren zur Verfügung, das durch Messung der

Blutflußgeschwindigkeit in basisnahen Hirngefäßen eine kontinuierliche Beurteilung der zerebralen Hämodynamik gestattet. Die Kombination beider Methoden erlaubt, sowohl die hämodynamischen ("input") als auch die funktionellen ("output") Effekte der Abklemmung der A. carotis int. innerhalb kurzer Zeit zu beurteilen.

Der vorliegende Bericht beschreibt die Anwendung der simultanen Ableitung von SEP und TCD bei einer 68jährigen Patientin, die sich aufgrund rezidivierender transitorisch ischämischer Attacken einer Desobliteration der linken Karotisgabel unterziehen mußte. Nach zunächst unauffälligen Ausgangsbefunden von SEP und TCD zu Beginn der Operation trat bereits vor Abklemmung der A. carotis int. eine kritische Veränderung der TCD-Parameter auf. Der so ermittelte Verdacht auf eine drohende Ischämie des linken Media-Stromgebietes wurde durch die Ableitung der SEP bestätigt. Die medikamentöse Anhebung des arteriellen Blutdruckes konnte diese Veränderungen nicht vollständig beseitigen. Die Abklemmung der A. carotis int. im weiteren Verlauf der Operation hatte keinen Einfluß auf die SEP- und TCD-Werte, so daß auf die Einlage eines temporären intraluminalen Shunts verzichtet wurde. Als Ursache dieser unerwartet aufgetretenen zerebralen Ischämie konnte eine intraoperativ entstandene Thrombose der A. carotis int. gesichert werden. Postoperativ hatte die Patientin ein neues neurologisches Defizit, das innerhalb von 24 Stunden fast vollständig reversibel war.

Der vorliegende Fall zeigt, daß mit der TCD eine drohende zerebrale Ischämie korrekt erkannt werden konnte. Im Rahmen der Karotischirurgie könnte die kombinierte Anwendung von SEP und TCD helfen, intraoperativ festzustellen, welcher Patient von der Einlage eines Shunts hämodynamisch profitieren würde. Dies gilt allerdings nur für den Fall, daß nicht routinemäßig „geschuntet“ wird.

## Key words

Carotid endarterectomy – Somatosensory evoked potentials – Transcranial Doppler sonography

## Introduction

New neurological deficits after carotid endarterectomy have remained a serious problem despite improved surgical and anaesthetic techniques. In order to monitor cerebral function intraoperatively, various methods have been proposed including the electroencephalogram (EEG) in its raw or computer-assisted forms. Compared to computerized EEG

analysis, somatosensory evoked potential (SEP) recording is more sensitive and specific in detecting cerebral ischemia during carotid endarterectomy and provides prognostic information concerning the postoperative neurological status (8). Whereas electrophysiological methods measure the functional "output" of cerebral ischemia, several studies have been undertaken to evaluate the "input" i.e. cerebral hemodynamics during carotid endarterectomy (6, 9).

Recently, transcranial Doppler sonography (TCD), as a noninvasive method providing on-line data about flow velocities in basal cerebral arteries, has been applied to carotid surgery (3, 7, 10). In the following case, combined SEP and TCD monitoring detected early during carotid endarterectomy cerebral ischemia caused by intraoperative thrombosis of the internal carotid artery distal to the clamp.

### Case presentation

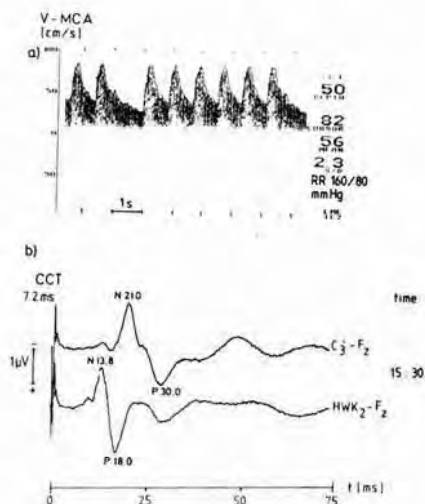
A 68-year-old woman (weight 78 kg, height 166 cm) was admitted for left carotid endarterectomy. She had had a reversible neurological deficit (RIND) 3 weeks before and multiple episodes of left-hemispheric transitory ischemic attacks (TIA). Preoperative angiography revealed a 90% stenosis of the left internal carotid artery and a 80% stenosis contralaterally. The EEG showed a mild focus on the right temporoprecentral region and cranial computed tomography revealed a subcortical infarction without clinical symptoms. Just prior to operation she suffered a TIA related to the right hemisphere.

After oral premedication with 10 mg diazepam, anesthesia was induced with 375 mg thiopentone and 2 mg vecuronium and maintained with isoflurane (0.5–1.0%). Intubation was facilitated using 80 mg succinylcholine. Further muscle relaxation required another 6 mg of vecuronium. Hypocapnic ventilation ( $\text{paCO}_2 = 30 \text{ mmHg}$ ) was controlled by endtidal  $\text{CO}_2$  recording (Capnolug, Draeger Co.) and arterial blood gas analysis. Arterial blood pressure was registered continuously via a 22G catheter placed in the right radial artery.

Somatosensory evoked potentials (SEP) were recorded after right median nerve stimulation at the wrist using a NICOLET CA 1000 averager. Stimulation rate was 3.1/s and duration 0.2 ms using constant current of 19.9 mA. Filters were set at 30 Hz and 1500 Hz. Analysis time was 75 ms after stimulus. According to the International 10-20-system, surface electrodes were placed to obtain cortical ( $\text{C}_3'$ ) and cervical (HWK2) SEP's both referenced to frontal central (F2). The right elbow served as a ground. Latencies and amplitudes of both cortical and cervical SEP were evaluated using an oscilloscope cursor. Central conduction time (CCT), which is the transit time of the afferent volley between cervical spine and cortex, was calculated as the difference of N20 (cortical) and N14 (cervical). Before clamping of the internal carotid artery, 256 responses were averaged to obtain baseline values. After clamping, 100 averages were sufficient to produce stable SEP. For further methodological information see (4) and (8).

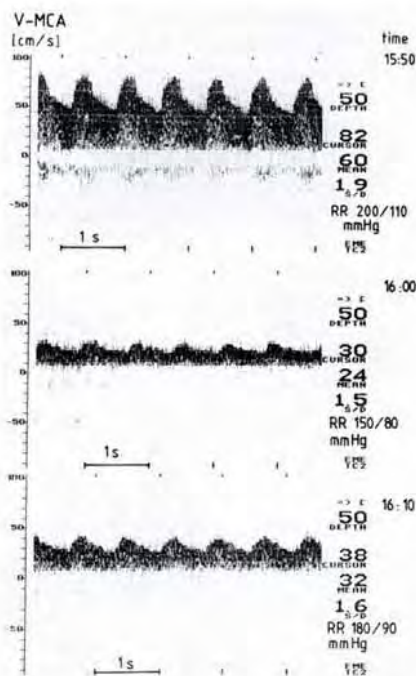
Transcranial Doppler sonography (TCD) was performed transtemporally by a pulsed 2-MHz device (TC 2-64, EME Co.). The blood flow velocity of the middle cerebral artery (MCA) was recorded using a handheld Doppler probe placed just above the zygomatic arch. Depth was set at 50 mm to obtain transcranial Doppler signals of the M1-segment of the MCA. We avoided an exact identification of the vessels insonated by carotid compression because of possible cerebral embolization. Time-averaged values of mean flow velocity (cm/s) and pulsatility (systolic/diastolic flow velocity) were calculated automatically, whereas systolic blood flow velocity was determined by setting a cursor on the TCD oscilloscope. Detailed information regarding TCD methods can be taken from the literature (1, 5).

Baseline values of SEP and TCD (MCA flow velocities of both sides) were recorded before surgery and showed no abnormalities (Fig. 1). At the beginning of surgery, the patient had arterial hypertension (RR 200/110 mmHg) which was treated with vasodilators (nitroglycerine 0.1 mg/min) thus lowering her arterial blood pressure to the post-induction level (RR 150/80 mmHg). 10 min later, during preparation of the carotid bifurcation, TCD showed a marked reduction of the ipsilateral MCA mean blood flow velocity compared to the preceding values. The pulsatility of the obtained ultrasound wave form was reduced from 1.9 to 1.5 (Fig. 2). A critical reduction of left MCA perfusion indicated by TCD was verified using SEP which now showed a marked depression of the primary cortical response with a complete loss of middle latency components (Fig. 3). With the internal carotid artery still under preparation and unclamped we had no explanation for this unexpected cerebral ischemia. Raising the patient's arterial blood pressure to 195/95 mmHg slightly improved both TCD and SEP parameters but could not normalize them. 13 min later, 7500 units of heparine were given i.v. and the internal carotid artery clamped for 24 min without any effects on TCD or SEP values (Fig. 3, Fig. 4). For this reason, we felt that temporary intraluminal shunting would not improve the situation. Carotid endarterectomy and patch enlargement as routinely done were performed without surgical problems. The internal carotid artery was then declamped to allow retrograde bleeding. Unexpectedly, no bleeding was seen until the vessel had been digitally massaged for a few seconds thus removing a thrombus which had totally occluded the lumen. After carotid declamping, TCD now showed a marked acceleration of MCA blood flow velocity which returned to near baseline values within the following 7 min (Fig. 5). These changes were associated with improved cortical SEP. However, the amplitude of the primary cortical complex was

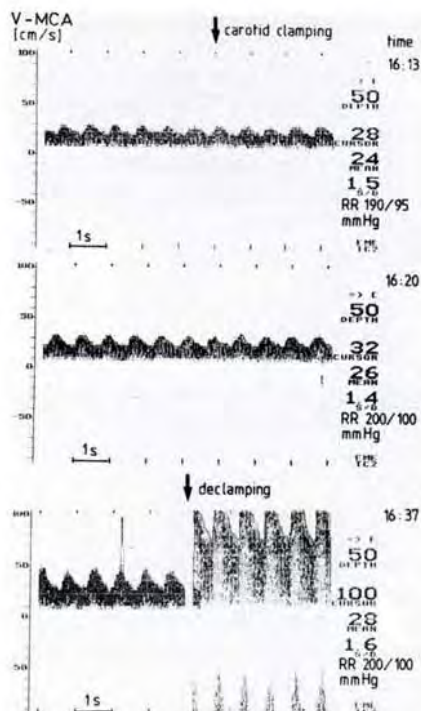


**Fig. 1** Baseline TCD (a) and SEP (b) recordings after induction of anaesthesia and before surgery. Blood flow velocity of the left middle cerebral artery (V-MCA) is within normal ranges (peak velocity 82 cm/s, mean velocity 56 cm/s). At the same time (15:30), normal SEP after right median nerve stimulation are registered (time base 75 ms). By convention, negativity is an upward deflection. The latencies of the primary cortical (upper trace) and the cervical response (below) are given in ms after stimulus. The central conduction time (CCT) (N21.0–N13.8) is slightly increased (7.2 ms) possibly due to the inhalation of 0.8% isoflurane

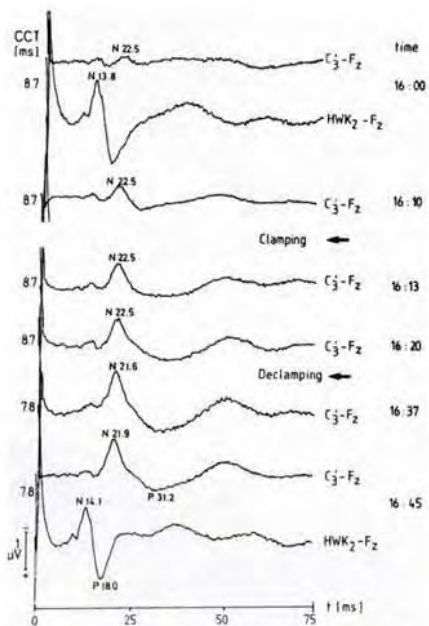




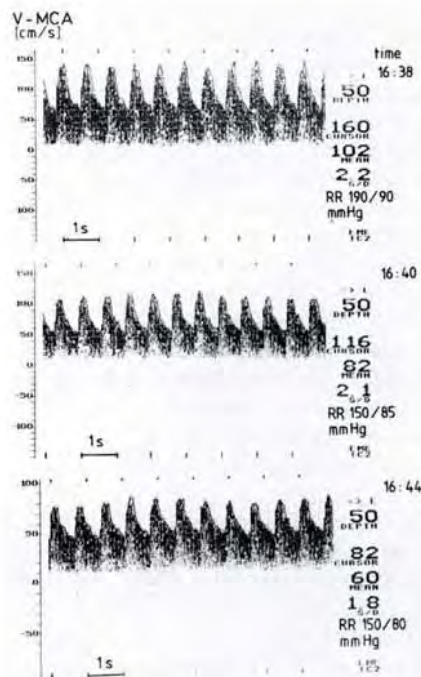
**Fig. 2** TCD records before carotid clamping. With arterial hypertension (RR 200/110 mm Hg) at the beginning of surgery, left V-MCA differs minimally from baseline values (top). 10 min later (16 : 00), V-MCA and the pulsatility of the obtained waveform are markedly reduced (middle) indicating a critical impairment of MCA perfusion with the internal carotid artery still unclamped. By raising the arterial blood pressure, V-MCA and pulsatility are slightly increased (bottom)



**Fig. 4** TCD registration reveals no effect of carotid clamping on MCA perfusion (top, middle). Thrombus removal after carotid declamping leads to a marked acceleration of V-MCA indicating postischemic hyperperfusion of the MCA territory (bottom)



**Fig. 3** Median nerve SEP in the course of the operation. Left hemispheric ischemia indicated by TCD is verified (upper trace). The primary cortical response is now markedly reduced in amplitude and prolonged in latency (N22.5) associated with an increase of CCT (8.7 ms). Re-establishing arterial hypertension improves the amplitude (16 : 10–16 : 20) without an effect on latency. Clamping of the left internal carotid artery does not further deteriorate the cortical SEP. After declamping and thrombus removal, the cortical response amplitude is still reduced and CCT increased compared to the baseline values



**Fig. 5** TCD records after carotid declamping. V-MCA returns to near baseline values within 7 min after declamping. Note the different graduation of the vertical scale in the bottom trace

reduced and CCT still increased compared to the preoperative recordings.

After surgery was completed, the patient awoke promptly but had a complete paresis of her right arm. She was admitted to the intensive care unit where she regained normal brachial function within 24 hours except for a mild sensory weakness of the right forearm as confirmed by neurological examination. On the first postoperative day, TCD investigation showed normal MCA velocities bilaterally.

## Discussion

The intraoperative detection of cerebral ischemia is mainly based upon registration of the brain's electrical activity (EEG, SEP) and/or evaluation of cerebral hemodynamics. For SEP monitoring during carotid endarterectomy, Russ and co-workers (8) showed that this method provides highly sensitive and specific data. Furthermore, defined SEP changes are of prognostic value regarding the patient's neurological outcome.

As one of the causes of cerebral ischemia during carotid endarterectomy is the deterioration of blood supply to the brain after carotid clamping, the evaluation of cerebral hemodynamics is "closer to the roots" than are electrophysiological methods. However, the measurement of regional cerebral blood flow (rCBF) is invasive and cannot provide on-line data. Transcranial Doppler sonography may solve this problem as it is a noninvasive method of measuring blood flow velocities in basal cerebral arteries. Comparative studies showed that changes in rCBF are highly correlated to changes in MCA flow velocities (2). Moreover, intracranial hemodynamics in patients suffering from carotid artery disease can be determined by TCD investigation (5).

Padayachee and co-workers applied TCD monitoring during carotid endarterectomy (7) in 19 patients. An intraluminal shunt was inserted in all cases. After carotid clamping, a significant decrease of MCA flow velocity of all patients occurred (range 0-30 cm/s) which reversed to near baseline values after shunt insertion. Electrophysiological monitoring was not performed in this study. So the functional relevance of the reported events remains obscure.

Büdingen and associates (3) examined 100 cases of carotid endarterectomy using TCD. In 10 patients, TCD could not be performed for technical reasons. After clamping, MCA flow velocity varied widely (0-Flow in 15 cases, no change in 13 cases). A temporary shunt was indwelled if MCA flow velocity was reduced less than 50% compared to baseline values. Again, no electrophysiological monitoring was undertaken in this study.

Using SEP during carotid endarterectomy, at least 1 minute is needed to detect cerebral ischemia after carotid clamping. As we could show in a previous report including 40 patients (10), mean MCA flow velocity reduction less than 60% after clamping is highly related to critical SEP changes. Therefore, combined TCD and SEP registration allows a more rapid evaluation of cerebral perfusion than does SEP monitoring alone.

In the present case, TCD registration revealed a critical impairment of left MCA perfusion even before carotid clamping. The functional relevance of this event was verified by SEP recording. Raising the patient's blood pressure in this situation was an attempt to increase MCA perfusion, and TCD and SEP parameters slightly improved.

Acute thrombosis of the internal carotid artery, as in this case, remains a rather rare cause of cerebral ischemia during carotid endarterectomy. It is worth noting that TCD monitoring throughout the operation was helpful in detecting an unexpected impairment of left MCA perfusion. Furthermore, the present case stresses the need for monitoring methods which provide on-line data about cerebral hemodynamics in order to initiate therapeutic procedures as early as possible if ischemia leads to functional impairment.

In this respect, further studies are necessary to evaluate how far TCD monitoring during carotid endarterectomy can provide reliable, sensitive, and specific data indicating cerebral ischemia of functional relevance.

## References

- 1 Aaslid, R. (ed.): *Transcranial Doppler Sonography*. Wien-New York, Springer (1986)
- 2 Bishop, C. C. R., S. Powell, D. Rutt, and N. L. Browse: Transcranial Doppler measurement of middle cerebral artery blood flow velocity: A validation study. *Stroke* 17 (1986) 913-915
- 3 Büdingen, H. J., C. Hoffmann, J. Knippschild, T. Staudacher, A. Zeides, and F. M. Grögler: Transcranial Doppler flow monitoring in the middle cerebral artery during carotid operations. In: Maurer, P. C., H. M. Becker, H. Heidrich, G. Hoffmann, A. Kriessmann, H. Müller-Wiefel, C. Prätorius (eds.): *What is new in angiology?* München-Bern-Wien, Zuckschwerdt, 1986, p. 290
- 4 Hume, A. L., and B. R. Cant: Conduction time in central somatosensory pathways in man. *Electroencephalogr. Clin. Neurophysiol.* 45 (1978) 361-375
- 5 Lindegaard, K. F., S. J. Bakke, P. Grolimund, R. Aaslid, R. Huber, and H. Nornes: Assessment of intracranial hemodynamics in carotid artery disease by transcranial Doppler ultrasound. *J. Neurosurg.* 63 (1985) 890-898
- 6 Messick, J. M., B. Casement, F. W. Sharbrough, L. N. Milde, J. D. Michenfelder, and T. M. Sundt: Correlation of regional cerebral blood flow (rCBF) with EEG changes during isoflurane anesthesia for carotid endarterectomy: Critical rCBF. *Anesthesiology* 66 (1987) 344-349
- 7 Padayachee, T. S., R. G. Gosling, C. C. R. Bishop, K. G. Burnand, and N. L. Browse: Monitoring middle cerebral artery blood velocity during carotid endarterectomy. *Br. J. Surg.* 73 (1986) 98-100
- 8 Russ, W., G. Fraedrich, F. W. Hehrlein, and G. Hempelmann: Intraoperative somatosensory evoked potentials as a prognostic factor of neurologic state after carotid endarterectomy. *Thorac. cardiovasc. Surgeon* 33 (1985) 392-396
- 9 Sundt, T. M., F. W. Sharbrough, and D. G. Ptegras: Correlation of cerebral blood flow and electroencephalographic changes during carotid endarterectomy. *Mayo Clin. Proc.* 56 (1981) 533-543
- 10 Thiel, A., W. Russ, W. A. Stertmann und G. Hempelmann: Intraoperative Monitoring bei desobliterierenden Eingriffen an der Karotisgabel mit somatosensorisch evozierten Potentialen (SEP) und transkranieller Dopplersonographie (TCD). *Thorac. cardiovasc. Surgeon* 36, Suppl. I (1988) 13

Dr. A. Thiel

Abteilung für Anästhesiologie  
und Operative Intensivmedizin  
Justus-Liebig-Universität  
Klinikstraße 29  
D-6300 Giessen/FRG