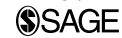

Temporal Bone Mucormycosis

Nicolas-George Katsantonis, MD¹, Jacob B. Hunter, MD¹,
Brendan P. O'Connell, MD¹, Jing He, MD²,
James S. Lewis, Jr., MD^{1,2}, and George B. Wanna, MD¹

Annals of Otolaryngology, Rhinology & Laryngology
2016, Vol. 125(10) 850–853
© The Author(s) 2016
Reprints and permissions:
sagepub.com/journalsPermissions.nav
DOI: 10.1177/0003489416654711
aor.sagepub.com



Abstract

Case Details: We present a case of temporal bone mucormycosis in a 71-year-old female with diabetes mellitus who presented to the emergency department with facial nerve paresis, otorrhea, and contralateral hemiparesis. After undergoing a tympanomastoidectomy, the patient's pathology exhibited fungal hyphae consistent with mucormycosis.

Discussion: To our knowledge, there have been 9 reported cases of temporal bone mucormycosis, 3 of which presented with facial nerve paresis, all with some subsequent improvement. In this case, facial paralysis persisted at the time of last follow-up (2 months) despite surgery and intravenous antifungals. We also review and summarize the temporal bone mucormycosis literature.

Conclusion: Temporal bone mucormycosis is a rare and morbid infectious disease, though its outcomes appear to be different for patients who present with isolated temporal bone disease as compared to those individuals who develop temporal bone mucormycosis secondary to a rhinologic source.

Keywords

infection, otitis media, facial nerve, temporal bone pathology

Introduction

Mucormycosis involving the ear is extremely rare. To our knowledge, only 9 cases of mucormycosis of the temporal bone have been reported in the literature.¹⁻⁹ Of these 9, two were reported in non-immunocompromised patients, and 3 patients demonstrated facial nerve palsies.³⁻⁵ We present the case of a 71-year-old woman with poorly controlled diabetes who presented with a seizure-like episode, otorrhea, and subsequent facial nerve weakness. She eventually underwent a tympanomastoidectomy with pathology demonstrating mucormycosis. The usual hallmarks of pale and necrotic tissue that are associated with mucormycosis within the nasal and oral cavities were not present. We report this case to highlight the presence and morbidity of mucormycosis within the temporal bone.

Case Report

A 71-year-old female with insulin-dependent diabetes presented to the emergency department for a seizure-like episode with left sided hemiplegia. According to the patient's daughter, the patient also had a 1-week history of purulent right-sided otorrhea and right-sided facial weakness that had been treated with oral levofloxacin, valacyclovir, and topical ciprofloxacin-dexamethasone drops. On physical exam, the patient was somnolent, with a right facial weakness (grade VI/VI on the House-Brackmann [HB] scale),

right external auditory canal (EAC) purulent otorrhea, and left hemiparesis. A CT temporal bone showed complete opacification of the right middle ear and mastoid, with ossicles present and without surrounding bony destruction (Figures 1, 2). A brain magnetic resonance imaging (MRI) without contrast showed punctate foci of acute infarcts in the paramedian and posterior right frontal and right parietal lobes, consistent with anterior cerebral artery/middle cerebral artery and middle cerebral artery/posterior cerebral artery watershed infarcts.

Laboratory studies showed a mild leukocytosis of 11,400 cells/ μ L and serum glucose of 256 mg/dL. A lumbar puncture (LP) was also obtained (nucleated cells 1; red blood cells 2; glucose 108 mg/dL; protein 42 mg/dL). Given the clinical exam, along with imaging demonstrating an opacified right middle ear and mastoid, the patient underwent a right-sided tympanomastoidectomy. Intraoperatively, extensive granulation tissue filled the middle ear, antrum, and

¹Department of Otolaryngology, Head and Neck Surgery, Vanderbilt University Medical Center, Nashville, Tennessee, USA

²Department of Pathology, Microbiology, and Immunology, Vanderbilt University Medical Center, Nashville, Tennessee, USA

Corresponding Author:

Jacob B. Hunter, MD, Department of Otolaryngology, Vanderbilt School of Medicine, Medical Center East, S. Tower, 1215 21st Ave. South, Suite 7302, Nashville, TN 37232-878, USA.
Email: jacob.b.hunter@vanderbilt.edu

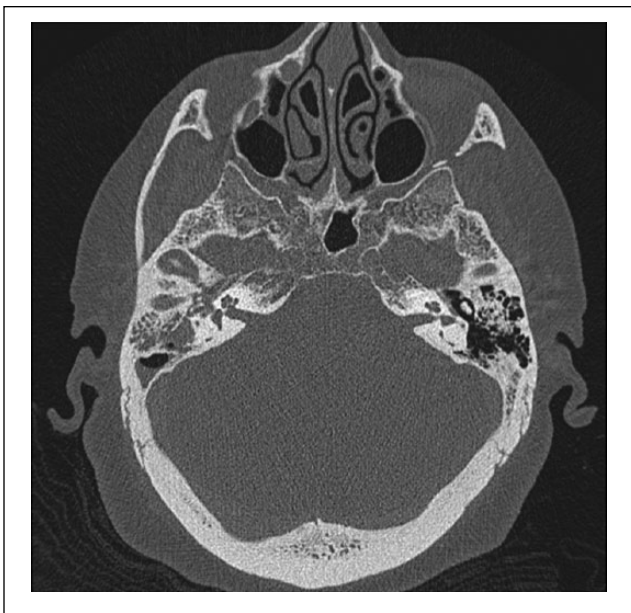

Figure 1. Contrasted computed tomographic axial image of temporal bones, showing an opacified right mastoid and middle ear cavity with ossicles in place.

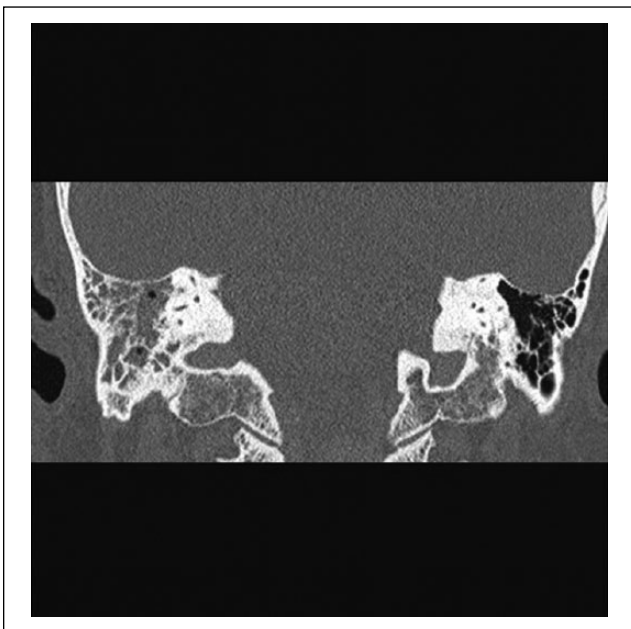


Figure 2. Contrasted computed tomographic coronal image of temporal bone study, demonstrating an opacified right mastoid cavity.

mastoid cavity. No pale or necrotic tissue was noted, and normal bleeding was encountered throughout. The malleus and incus were eroded and their remnants removed. No facial nerve dehiscence was appreciated. The mastoid and middle ear were debrided, the tympanic membrane

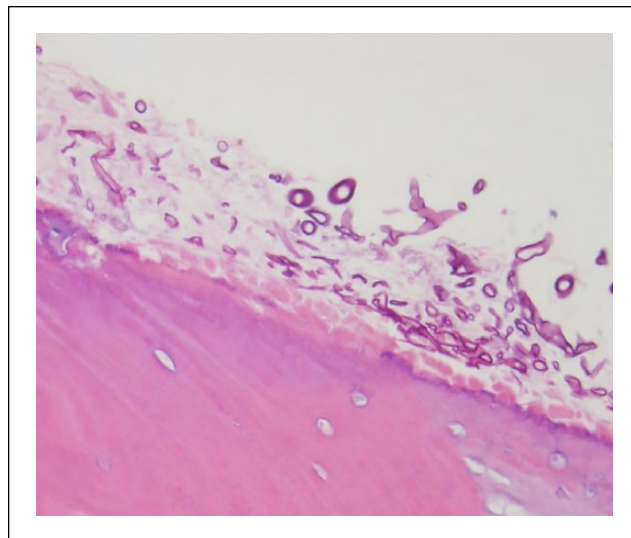


Figure 3. H&E stain of mastoid bowl specimen showing a bone fragment with numerous ribbon-shaped, irregular, aseptate hyphae with superficial erosion but without necrosis. 40 \times

reconstructed with a fascia graft, and a pressure equalization tube was placed. All cultures, LP, aerobic, anaerobic, and fungal demonstrated no growth. However, representative pathology slides of the mastoid contents (Figures 3) demonstrated irregularly shaped, thick-walled fungal hyphae with no obvious septation growing on and slightly eroding the small bone fragments (ossicles) that had been excised. Besides the noted erosion, the bone appeared viable without signs of osteomyelitis or profound inflammation. There was no evidence of necrosis or vasculitis. No soft tissue was present for histopathologic evaluation, however.

Discussion

Mucormycosis is typically encountered as a devastating invasive infection of the of the nose, paranasal sinuses, and oral cavity in immunocompromised patients.¹⁰ With attenuated immune systems, these patients become susceptible to invasive infections by ubiquitous and typically harmless fungi—most notably genera *Rhizopus*, *Mucor*, and *Absidia*—encountered by all humans as bread and fruit mold.^{1,11} The rhinologic diagnosis is suspected in immunocompromised patients with the clinicopathologic features described in Table 1. Even with proper treatment, however, the mortality of rhinocerebral mucormycosis is variable and ultimately reflects the ability to reverse the patient's underlying immunosuppression. Mortality rates in diabetic and nondiabetic patients are approximately 20% and 50%, respectively.¹⁰

While the differential diagnosis of otorrhea with facial nerve weakness includes complicated acute bacterial otomastoiditis and temporal bone osteomyelitis, the negative

Table 1. Clinicopathologic Features of Rhinocerebral Mucormycosis.

Etiology	- Poorly controlled diabetes mellitus - Blood dyscrasias - Pharmacologic immunosuppression (eg, transplant medications)
Signs and symptoms	- Fever - Acute sinusitis symptoms (eg, nasal obstruction, facial pressure/pain)
Endoscopic findings	- Necrotic nasal, sinus, or oral cavity mucosa
CT findings	- Paranasal sinus opacification with or without bony destruction
Natural history	- Rapid progression - Facial swelling - Cranial neuropathies - Skull base destruction and meningoencephalitis
Histopathologic findings	- Aseptate, broad, and ribbon-like hyphae - Angioinvasion - Soft tissue and osteonecrosis - Vasculitis with thrombosis and infarction
Treatment	- Reversal of immunocompromised state - Surgical debridement - IV antifungals (eg, liposomal Amphotericin B)

Abbreviation: CT, computed tomography; IV, intravenous.

bacterial and fungal cultures made these diagnoses less likely in this case. In addition, *Herpes zoster* oticus (Ramsay-Hunt syndrome), a selective reactivation of the varicella-zoster virus previously dormant in the geniculate ganglion of the facial nerve, can also present with facial weakness, though lack of vesicular lesions made this diagnosis also unlikely. Thus, the diagnosis is reliant on recognition of the distinct histopathologic appearance, outlined in Table 1.¹¹

Rhinocerebral mucormycosis results from inhalation of the fungal organisms onto the sinonasal mucosa of a susceptible, usually immunocompromised host. Despite the ubiquitous nature of the offending fungi, it is a relatively rare disease: Even in high-risk, immunocompromised patients, mucormycosis only accounts for a minority of all fungal infections.¹² For otologic mucormycosis, it has been suggested that the fungal spores enter either through the Eustachian tube or through a tympanic membrane perforation.¹ Reviewing previously described otologic mucormycosis within the literature, 5 of the 9 patients presented with purulent otorrhea and debris-filled external auditory canal, with intraoperative findings of middle ear and mastoid granulation tissue.¹⁻⁵ The remaining 4 cases exhibited no otologic signs or symptoms, all with evidence of a rhinologic origin of the mucormycosis, and have been the only cases that have resulted in death.⁶⁻⁹ For these cases, temporal bone pathology was noted on imaging and mucormycosis specifically on autopsy.

In regards to the 4 patients with rhinologic origin of their temporal bone mucormycosis, 1 case involved a 28-year-old male undergoing blood marrow transplantation for acute myelogenous leukemia (AML). He presented with numerous acute cranial nerve neuropathies (including cranial nerves VI, X, XI, and XII, though with an intact facial nerve), along with a nasopharyngeal eschar and the presence of mucormycosis in bilateral petrous apices. He died of elevated intracranial pressure secondary to meningoencephalitis.⁸ The second patient had a history of advanced AML and presented with frontal pain and pressure with ipsilateral frontal sinusitis on imaging. He eventually died of meningoencephalitis with the histologic finding of mucormycosis of the ipsilateral temporal bone on autopsy, involving the tympanic membrane, middle ear, mastoid cavity, and inner ear.⁶ Lastly, the remaining 2 cases occurred in diabetic patients with cranial neuropathies and nasopharyngeal lesions. Both patients died of mycotic aneurysms of the internal carotid artery and had extensive mucormycosis of the temporal bones on autopsy.^{7,9}

Only 1 published case reported positive culture data, which was obtained from a nasal debridement specimen in a stem cell transplant patient.⁸ The remaining 8 of cases did not report culture results.^{1-7,9} It is not uncommon for zygomycete fungus to fail to grow in cultures, even from obviously infected tissues, but for unknown reasons.¹³ Interestingly, histologic findings of necrosis, vasculitis, angioinvasion, and infarction, the hallmarks of mucormycosis, were infrequently noted. A few reports have demonstrated necrotizing inflammatory pathology, while Biniyam et al⁵ specifically comment on the surprising absence of tissue vasculitis or invasion in their study. Similar to this latter finding, our case failed to show evidence of osteonecrosis or osteomyelitis. However, soft tissue was not available for evaluation.

In general, the reported mortality rate of temporal bone mucormycosis is approximately 45%. However, when looking at *isolated* temporal bone mucormycosis—cases that appeared to originate in the temporal bone without evidence of progression from a rhinologic source—there were no deaths. This difference suggests that isolated temporal bone mucormycosis is perhaps a naturally less fulminant disease than the rhinologic form that may involve the temporal bones as it progresses. The mechanism behind this difference is unclear but may relate to decreased vasculature of the middle ear (compared to the paranasal sinus) limiting angioinvasion and spread of infection, differences in the middle ear and paranasal microbiome that limit primary mucormycosis infection in the middle ear, or simply a reflection of the small number of cases.

For all reported cases, including the one herein, the infection was treated with surgical debridement and intravenous (IV) antifungals (typically, liposomal amphotericin B). Given the paucity of cases, the duration of antifungal

therapy for isolated temporal bone mucormycosis has not been established. In our patient, after infectious disease consultation, she was treated with 3 weeks of IV liposomal amphotericin B and transitioned to oral isavuconazole for a total treatment duration of 3 months.

Of the 3 previously reported cases of facial nerve paresis with isolated temporal bone mucormycosis, all patients were middle-aged, poorly controlled diabetics, and presented with otorrhea and facial asymmetry.²⁻⁴ Each patient underwent a tympanomastoidectomy and was treated with IV antifungals postoperatively. Two patients, in contrast to our case, demonstrated improvement in their facial function at last follow-up. While 1 patient presented with “complete paralysis” that improved to “mild facial asymmetry” 8 months postoperatively, in the other case, the patient had facial weakness graded as an HB IV/VI at presentation, which had improved to eye closure immediately following her tympanomastoidectomy.^{2,3} The third patient, who presented with 1 month duration of facial weakness, had only mild improvement of his asymmetry and eye closure postoperatively with no ultimate change in his HB grade of IV/VI.⁴ All 3 patients survived.

Though our patient was lost during extended follow-up, her left-sided hemiparesis had improved at 7 weeks postoperatively, and her right facial weakness remained a HB VI/VI. She subsequently underwent a right eyelid gold weight placement and lateral canthoplasty 4 and 7 weeks postoperatively, respectively.

Conclusion

This case highlights the need to include temporal bone mucormycosis in the differential of immunocompromised hosts who present with purulent otorrhea and facial nerve paresis. Submission of tissues resected for fungal culture and for histologic examination should be performed. Patients with infection isolated to the temporal bone appear to have improved outcomes as compared to those with disease originating from the nose or paranasal sinuses. Although previous reports of patients with facial weakness documented improvement in their facial function following surgical debridement and IV antifungals, not all patients exhibit complete resolution of their weakness.

Declaration of Conflicting Interests

The author(s) declared no potential conflicts of interest with respect to the research, authorship, and/or publication of this article.

Funding

The author(s) received no financial support for the research, authorship, and/or publication of this article.

References

1. Hazarika P, Zachariah J, Victor J, John M, Devi C, Abraham P. Mucormycosis of the middle ear: a case report with review of literature. *Indian J Otolaryngol Head Neck Surg.* 2012;64(1):90-94.
2. Yun MW, Lui CC, Chen WJ. Facial paralysis secondary to tympanic mucormycosis: case report. *Am J Otol.* 1994;15(3):413-414.
3. Sathish Kumar KNN. Mucormycosis of the temporal bone with facial nerve palsy: a rare case report. *Indian J Oto.* 2015;21(1):61-63.
4. Shah V, Ganapathy H, Gopalakrishnan R, Geetha N. A rare case of facial palsy due to mucormycosis. *International Journal of Otolaryngology and Head & Neck Surgery.* 2015;4(03):224.
5. Biniyam K, Bhat V, Bhandary SKB, Aroor R. Asymptomatic mucormycosis of middle ear: an incidental finding during tympanoplasty. *Indian J Otol.* 2014;20(2):83.
6. Nomiya R, Nomiya S, Paparella MM. Mucormycosis of the temporal bone. *Otol Neurotol.* 2008;29(7):1041-1042.
7. Gussen R, Canalis RF. Mucormycosis of the temporal bone. *Ann Otol Rhinol Laryngol.* 1982;91(1 Pt 1):27-32.
8. Oo MM, Kutteh LA, Koc ON, Strauss M, Lazarus HM. Mucormycosis of petrous bone in an allogeneic stem cell transplant recipient. *Clin Infect Dis.* 1998;27(6):1546-1547.
9. McGill TJ. Mycotic infection of the temporal bone. *Arch Otolaryngol.* 1978;104(3):140-144.
10. Cummings CW. *Cummings Otolaryngology Head & Neck Surgery.* 4th ed. Philadelphia, PA: Elsevier Mosby; 2005.
11. Ribes JA, Vanover-Sams CL, Baker DJ. Zygomycetes in human disease. *Clin Microbiol Rev.* 2000;13(2):236-301.
12. Petrikkos G, Skiada A, Lortholary O, Roilides E, Walsh TJ, Kontoyiannis DP. Epidemiology and clinical manifestations of mucormycosis. *Clin Infect Dis.* 2012;54(suppl 1):S23-S34.
13. Hofman V, Castillo L, Betis F, Guevara N, Gari-Toussaint M, Hofman P. Usefulness of frozen section in rhinocerebral mucormycosis diagnosis and management. *Pathology.* 2003;35(3):212-216.