

# Reversible Edema-Like Changes Along the Optic Tract Following Pipeline-Assisted Coiling of a Large Anterior Communicating Artery Aneurysm

Biagia La Pira, MD, Waleed Brinjikji, MD, Christopher Hunt, MD, John J. Chen, MD, PhD, Giuseppe Lanzino, MD

**Abstract:** Aneurysmal volume expansion after endovascular treatment is caused by intra-aneurysmal thrombosis in the early postembolization period. Although postembolization mass effect on cranial nerves and other adjacent structures has been previously reported, we are unaware of reports involving the anterior visual pathway. A 66-year-old woman with a 2-week history of blurred vision without headache was found to have a large, unruptured anterior communicating artery aneurysm. One month after endovascular treatment of the aneurysm with coiling and flow diversion, the patient developed decreased vision in her right eye and a left homonymous hemianopia. Magnetic resonance imaging demonstrated compression of the right optic nerve, chiasm, and edema of the right optic tract. The patient was treated with a course of high dose corticosteroids, and over the course of several weeks, her vision improved and the optic tract edema resolved. We alert clinicians to this rare but potentially reversible visual complication of endovascular treatment of intracranial aneurysms.

**Journal of Neuro-Ophthalmology** 2017;37:154–158

doi: 10.1097/WNO.0000000000000412

© 2016 by North American Neuro-Ophthalmology Society

**I**ncreased T2 signal on magnetic resonance imaging (MRI) following the course of the optic tract associated with visual loss has been reported in patients with cranio-pharyngiomas compressing the optic apparatus, and initially was considered to be a specific finding for this type of tumor (1–4). Subsequently, these changes were documented in

Departments of Neurosurgery (BLP, CH), Radiology (WB, GL), and Neurology (JC), Mayo Clinic, Rochester, Minnesota.

Supported in part by an unrestricted grant to the Department of Ophthalmology by Research to Prevent Blindness, Inc, New York, New York.

The authors report no conflicts of interest.

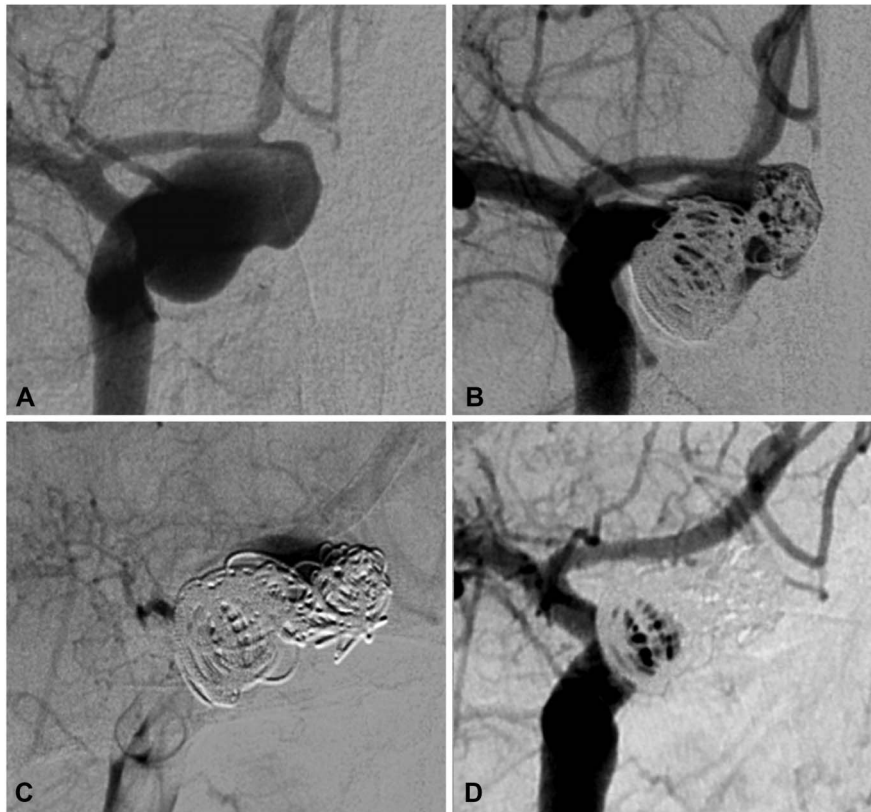
Address correspondence to Waleed Brinjikji, MD, Department of Radiology, 200 1st Street SW, Mayo Clinic, Rochester, MN 55905; E-mail: brinjikji.waleed@mayo.edu

a variety of neoplasms of the sellar region, including meningioma, pituitary tumor, germ cell tumor, lymphoma, pituitary metastasis, and foreign-body compression (5,6). We report a patient who suffered delayed visual deterioration and edema changes involving the optic tract one month after pipeline-assisted coiling of a large anterior communicating artery (Acom) aneurysm in the absence of perianeurysmal edema or contrast enhancement. The imaging changes and visual deterioration partially reversed after treatment with systemic corticosteroids.

## CASE REPORT

A 66-year-old woman was evaluated in the emergency department with a 2-week history of blurred vision without headache. Although neurological assessment did not reveal any focal findings, brain computed tomography (CT) detected an Acom aneurysm which was confirmed by CT angiography. Ophthalmologic testing showed no objective signs of optic nerve compression, including 20/20 visual acuity in each eye, intact color vision, and normal pupillary reactions, confrontation visual fields, and funduscopy. Cerebral catheter angiography confirmed a 17-mm bilobed aneurysm of the right A1-2 junction with delayed contrast stasis late in the venous phase (Fig. 1A). Given the aneurysm size, location, and the patient's symptoms, it was decided to proceed with endovascular treatment consisting of staged, relatively loose coiling with platinum coils (Fig. 1B) followed 3 days later by flow diversion with a pipeline embolization device (Fig. 1C). The patient was prescribed clopidogrel and aspirin before flow-diverter therapy. She was discharged home 2 days after the last procedure with the recommendation to continue dual antiplatelet therapy for 3 months.

One month after embolization, the patient noticed progressive worsening of her vision. Brain MRI showed evolving T2 changes along the right optic tract in the



**FIG. 1.** Angiographic images of a large anterior communicating aneurysm before treatment (**A**), immediately after coiling (**B**), and flow diversion (**C**), and at follow-up (**D**). After pipeline embolization device placement across the aneurysm neck, there is marked stasis within the aneurysm sac (**C**). At follow-up, there is markedly less filling of the aneurysm neck (**D**), consistent with progressive endothelialization across the pipeline stent and no residual filling of the sac, confirming intraneurysmal thrombosis related to the combined effect of the coils and the flow diverter.

absence of perianeurysmal enhancement or more widespread cerebral edema (Fig. 2A). Magnetic resonance angiography demonstrated near-complete obliteration of the aneurysm with only a small persistent neck remnant. Because of patient's visual complaints, an MRI done 6 days later demonstrated compression at the junction of the right optic nerve, chiasm, and right optic tract from the thrombosed aneurysm and hyperintensity involving the right optic tract on fluid attenuation inversion recovery (FLAIR) imaging (Fig. 2B, C). Visual acuity was 20/100 right eye, and 20/25 left eye. Color vision was reduced in right eye; there was a right relative afferent pupillary defect and a left homonymous hemianopia (Fig. 3A). The fundi appeared normal.

Cerebral angiography revealed complete occlusion of the aneurysm sac with a small neck remnant and delayed emptying of the small residual (Fig. 1D). The patient was treated with 1,000-mg intravenous methylprednisolone and discharged home 2 days later on dexamethasone 4 mg BID.

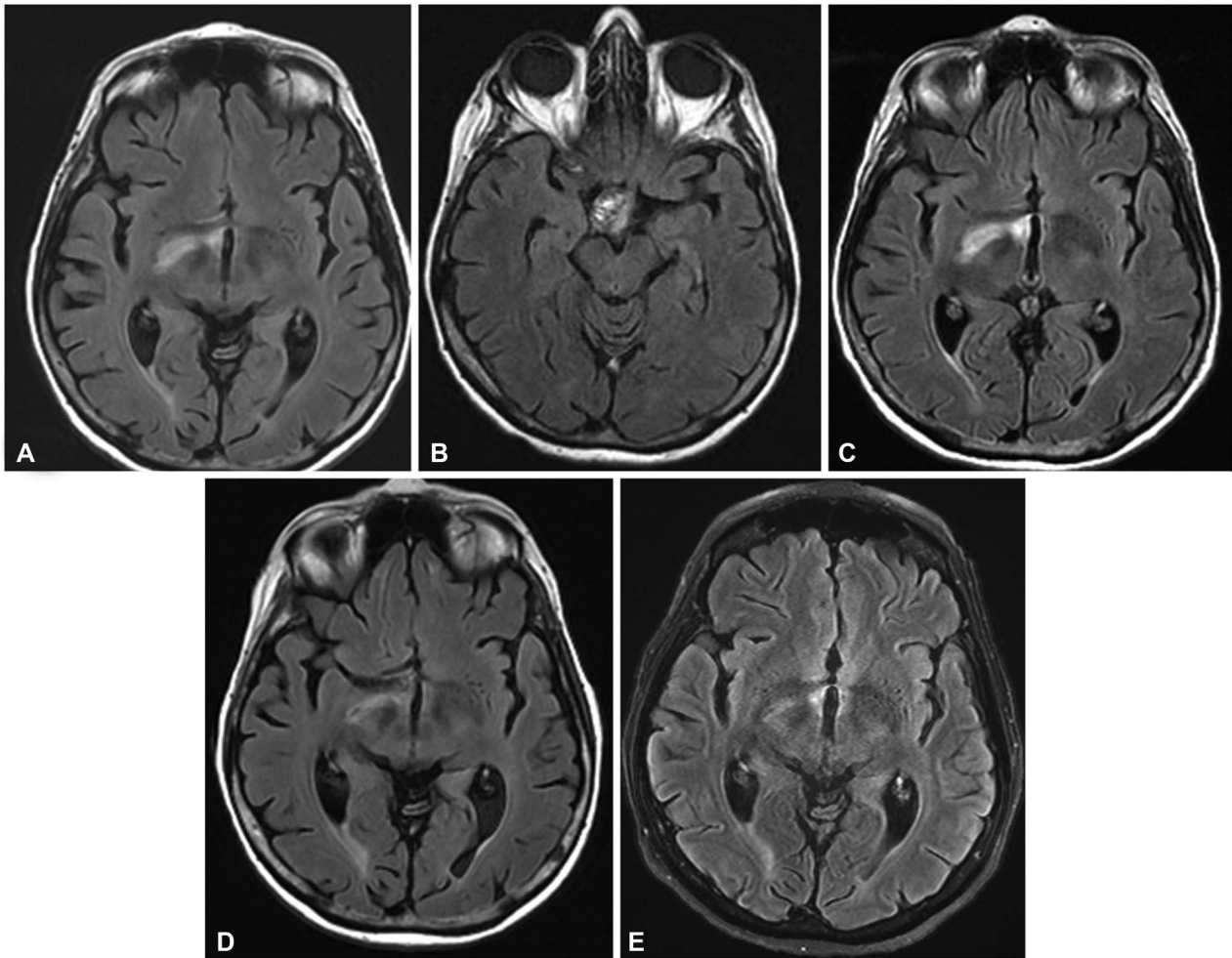
Two weeks later while still on oral steroids, the patient's MRI showed decreased hyperintensity in the right optic tract (Fig. 2D), and improvement in the left homonymous hemianopia (Fig. 3B).

Oral corticosteroids were tapered over 2 weeks with near complete resolution of the T2 signal within the right optic tract (Fig. 2E). Visual acuity was 20/40 right eye and remained 20/20 left eye. Six weeks after discontinuation of steroids, visual acuity further improved to 20/25 right eye, with normal pupillary testing and significant visual field recovery (Fig. 3C). Mild temporal pallor of the optic discs was observed at the most recent follow-up.

## DISCUSSION

Our patient experienced delayed visual deterioration and transient edema-like changes along the right optic tract 1 month after pipeline-assisted coiling of a large Acom aneurysm. Although brain MRI was not performed before or immediately after endovascular treatment, we were able to document progressive MRI changes starting 1 month after treatment. The neuroimaging studies were prompted by the patient's visual complaints and occurred in a delayed fashion after endovascular treatment.

Edema-like changes, as observed in our patient, were originally reported in patients with craniopharyngiomas compressing the optic apparatus and were considered



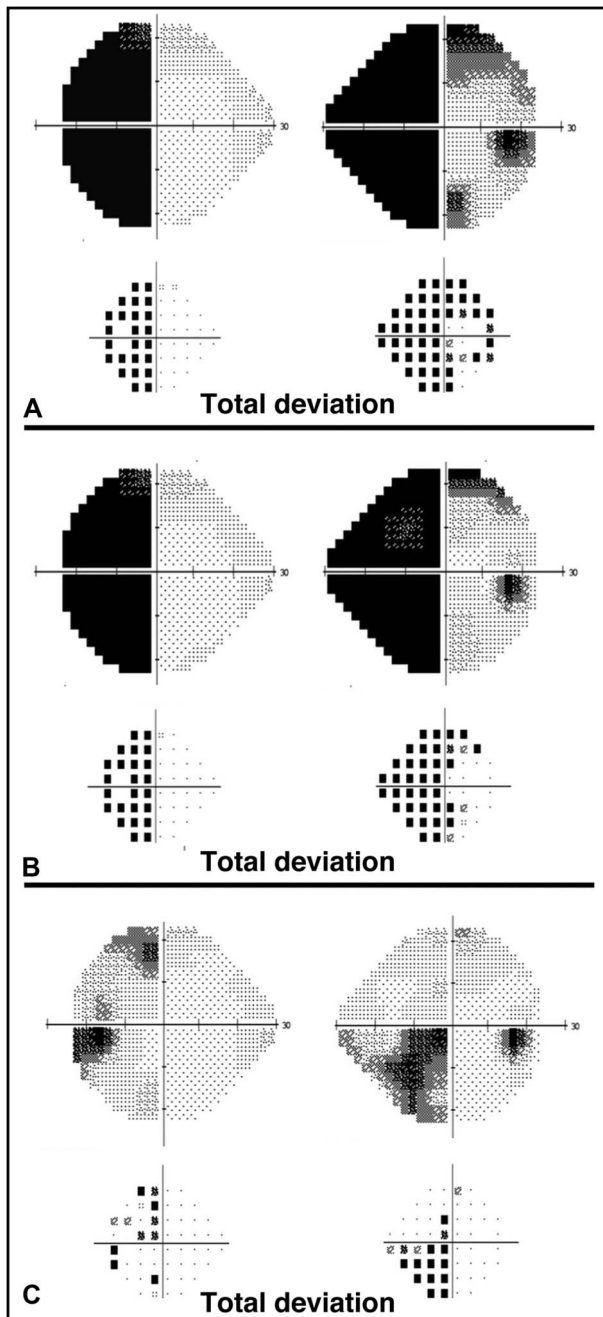
**FIG. 2.** **A.** Initial axial fluid attenuation inversion recovery (FLAIR) imaging shows edema along the right optic tract. Six days later, axial FLAIR scan demonstrates aneurysmal compression at the junction of the right optic nerve, chiasm, and right optic tract (**B**) and increasing hyperintensity along the right optic tract (**C**). After 2 weeks of steroid therapy, the hyperintensity of the right optic tract is decreasing (**D**). Ten days after completion of a 1 month course of steroids, the left optic tract hyperintensity continues to resolve (**E**).

characteristic of this tumor (2). Subsequently, similar changes were observed in other compressive lesions of the anterior visual pathway including pituitary tumor and Rathke cleft cyst (3,5). These T2 changes are not necessarily associated with the presence of visual symptoms in the case of benign, slow-growing tumors (3), but may accompany the onset of visual symptoms in rapidly growing neoplasms (7), and inflammation due to foreign body reactions (8).

Volume expansion after endovascular treatment of large and giant intracranial aneurysms has been described previously and is thought to occur secondary to thrombus formation within the aneurysm sac, induced from coil embolization and/or flow diversion (9,10). However, this volume expansion rarely leads to new neurologic symptoms. McAuliffe et al (11) documented this complication in 13 of 15 patients and many experienced visual symptoms due to brainstem compression. Our patient's symptoms were due to compression of the junction of the right optic nerve,

chiasm, and right optic tract (12). The corticosteroids likely temporized the vision loss, which allowed time for the intraluminal thrombus in between the coil loops to reorganize and retract leading to a delayed recovery in vision. Consistent with other reports, our patient experienced improvement in her visual symptoms after treatment with systemic corticosteroids.

Characteristic features of the Virchow–Robin spaces surrounding the optic tract may have led to the MRI changes observed in our patient and others (3). This hypothesis has been advanced to explain similar changes seen with benign tumors of the sellar region, where the edema-like changes along the optic tract are thought to be due to dilation of pre-existing Virchow–Robin spaces from sellar/parasellar tumors blocking the outward drainage from these spaces. However, the majority of these patients were visually asymptomatic, which suggests a different mechanism of vision loss in our patient. An alternative hypothesis for



**FIG. 3.** **A.** Initial automated visual fields reveal a dense left homonymous hemianopia and temporal field loss in the right eye consistent with right optic nerve/chiasmatal compression. **B.** After 2 weeks of steroid treatment, there is improvement in visual field testing, which continues 4 weeks later (**C**).

the development of these optic tract changes on MRI is that coiling and flow diversion resulted in inflammation within the aneurysm wall which disrupted local autoregulation and caused perianeurysmal vasogenic edema. However, this explanation is less likely because there was no perianeurysmal enhancement on MRI, and no clinical signs of inflammation such as headache. In addition, the gradual, delayed

improvement in vision after steroid therapy argues against a predominantly inflammatory etiology, where more rapid improvement would be expected. A transient ischemic phenomenon related to loss of antegrade flow to perforator vessels supplying the optic tract is another possibility. However, in general, ischemic complications related to flow diverters are permanent in nature, and in our patient there was improvement in visual acuity and visual fields. Lastly, these changes may have been related to the pulsation of the aneurysm, but this hypothesis also is unlikely, because the patient's visual complaints progressed as the aneurysm was undergoing progressive, near-total obliteration. In addition, we would have expected changes related to the pulsation mechanical effect to be much more prevalent at the time of presentation before treatment, and become less as the aneurysm underwent progressive involution after embolization.

#### STATEMENT OF AUTHORSHIP

Category 1: Conception and design, acquisition of data, analysis and interpretation of data: W. Brinjikji, G. Lanzino, J. Chen, C. Hunt, and B. La Pira. Category 2: a. Drafting the manuscript: B. La Pira and W. Brinjikji; b. Revising it for intellectual content: W. Brinjikji, G. Lanzino, J. Chen, C. Hunt, and B. La Pira. Category 3: Final approval of the completed manuscript: W. Brinjikji, G. Lanzino, J. Chen, C. Hunt, and B. La Pira.

#### REFERENCES

1. **Hirunpat S**, Tanomkiat W, Sriprung H, Chetpaophon J. Optic tract edema: a highly specific magnetic resonance imaging finding for the diagnosis of craniopharyngiomas. *Acta Radiol.* 2005;46:419–423.
2. **Nagahata M**, Hosoya T, Kayama T, Yamaguchi K. Edema along the optic tract: a useful MR finding for the diagnosis of craniopharyngiomas. *AJNR Am J Neuroradiol.* 1998;19:1753–1757.
3. **Saeki N**, Uchino Y, Murai H, Kubota M, Isobe K, Uno T, Sunami K, Yamaora A. MR imaging study of edema-like change along the optic tract in patients with pituitary region tumors. *AJNR Am J Neuroradiol.* 2003;24:336–342.
4. **Youl BD**, Plant GT, Stevens JM, Kendall BE, Symon L, Crockard HA. Three cases of the craniopharyngioma showing optic tract hypersignal on MRI. *Neurology.* 1990;40:1416–1419.
5. **Asaeda M**, Kurosaki M, Kambe A, Takenobu A, Horie Y, Yamane Y, Murakami Y, Watanabe T. MR imaging study of edema along the optic tract in patient with Rathke's cleft cyst [in Japanese]. *No To Shinkei.* 2004;56:243–246.
6. **Sklar EM**, Schatz NJ, Glaser JS, Sternau L, Seffo F. Optic tract edema in a meningioma of the tuberculum sellae. *AJNR Am J Neuroradiol.* 2000;21:1661–1663.
7. **Saeki N**, Murai H, Kubota M, Fujimoto N. Oedema along the optic tracts due to pituitary metastasis. *Br J Neurosurg.* 2001;15:523–526.
8. **Bhatti MT**, Holder CA, Newman NJ, Hudgins PA. MR characteristics of muslin-induced optic neuropathy: report of two cases and review of the literature. *AJNR Am J Neuroradiol.* 2000;21:346–352.
9. **Sim KJ**, Yan B, Dowling RJ, Mitchell PJ. Intracranial aneurysms with perianeurysmal edema: long-term outcomes post-endovascular treatment. *J Neuroradiol.* 2015;42:72–79.

10. **Carneiro A**, Rane N, Küker W, Cellerini M, Corkhill R, Byrne JV. Volume changes of extremely large and giant intracranial aneurysms after treatment with flow diverter stents. *Neuroradiology*. 2014;56:51–58.
11. **McAuliffe W**, Wycoco V, Rice H, Phatouros C, Singh TJ, Wenderoth J. Immediate and midterm results following treatment of unruptured intracranial aneurysms with the Pipeline Embolization Device. *AJNR Am J Neuroradiol*. 2012;22:164–170.
12. **Anderson DR**, Trobe JD, Hood TW, Gebarski SS. Optic tract injury after anterior temporal lobectomy. *Ophthalmology*. 1989;96:1065–1070.