



## Acute mental change and hemiplegia after autologous fat injection

Jun Ho Kang, Kyung Hye Park & Jung Soo Park

To cite this article: Jun Ho Kang, Kyung Hye Park & Jung Soo Park (2016): Acute mental change and hemiplegia after autologous fat injection, Journal of Cosmetic and Laser Therapy, DOI: [10.1080/14764172.2016.1197400](https://doi.org/10.1080/14764172.2016.1197400)

To link to this article: <http://dx.doi.org/10.1080/14764172.2016.1197400>



Accepted author version posted online: 28 Jun 2016.  
Published online: 28 Jun 2016.



Submit your article to this journal [↗](#)



Article views: 1



View related articles [↗](#)



View Crossmark data [↗](#)



## Acute mental change and hemiplegia after autologous fat injection

Jun Ho Kang, Kyung Hye Park, Jung Soo Park

Doi: 10.1080/14764172.2016.1197400

### **Abstract**

Autologous fat injection is a common procedure used for skin augmentation. Although it is believed to be a safe and simple procedure, severe complications have been reported sometimes. The authors experienced the patient with acute large cerebral infarction including the territories of the anterior and middle cerebral arteries and optic nerve infarction developing after autologous fat transplantation. A 32-year-old woman was referred to the emergency room of our hospital due to sudden stupor. Thirty minutes earlier, she was undergoing cosmetic autologous fat injection into the glabella area by a plastic surgeon at private clinic. The cause was confirmed to be anterior and middle cerebral arteries infarction on brain imaging studies. When patient present abrupt mental change, hemiplegia, ocular pain, or blindness after autologous fat particle injection, physicians must consider cerebral infarction and combined retinal artery occlusion.

# Acute mental change and hemiplegia after autologous fat injection

Jun Ho Kang<sup>1</sup>, Kyung Hye Park<sup>2</sup>, Jung Soo Park<sup>1</sup>

<sup>1</sup>College of Medicine, Chungbuk National University, Emergency Medicine, Cheongju, Republic of Korea; <sup>2</sup>Inje University Haeundae Paik Hospital, Emergency Medicine, Busan, Republic of Korea

Corresponding Author: Kyung Hye Park, Inje University Haeundae Paik Hospital, Emergency Medicine, 875, Haeundae-ro, Haeundae-gu, Busan, 612-030, Republic of Korea. E-mail: erdoc74@gmail.com

## Abstract

Autologous fat injection is a common procedure used for skin augmentation. Although it is believed to be a safe and simple procedure, severe complications have been reported sometimes. The authors experienced the patient with acute large cerebral infarction including the territories of the anterior and middle cerebral arteries and optic nerve infarction developing after autologous fat transplantation. A 32-year-old woman was referred to the emergency room of our hospital due to sudden stupor. Thirty minutes earlier, she was undergoing cosmetic autologous fat injection into the glabella area by a plastic surgeon at private clinic. The cause was confirmed to be anterior and middle cerebral arteries infarction on brain imaging studies. When patient present abrupt mental change, hemiplegia, ocular pain, or blindness after autologous fat particle injection, physicians must consider cerebral infarction and combined retinal artery occlusion.

## Introduction

Recently, cosmetic soft-tissue augmentation of the face by filler injections, such as autologous fat, has dramatically increased in popularity in Korea. Besides pain at the puncture site, autologous fat injection is generally associated with several complications (1, 2). Severe complications such as brain infarction and unilateral visual loss have been reported (1, 3-8). We herein present a rare case of acute large cerebral infarction including the territories of the anterior and middle cerebral arteries and optic nerve infarction developing after autologous fat transplantation.

## Case

A 32-year-old woman was referred to the emergency room of our hospital due to sudden mental change. Thirty minutes earlier, she was undergoing cosmetic autologous fat injection into the glabella area by a plastic surgeon at private clinic. Emulsified pure fat was injected with 18 gauge cannula, and there was no hematoma after the procedure. When she transported to emergency room by ambulance, she had global aphasia and right complete sensorimotor hemiplegia with stuporous mentality. She had no history of systemic disease, previous surgery, or recent trauma. Her vital signs were normal. The neck vessel and heart auscultations were normal. Her left eye was midline fixed; the pupil was dilated and unresponsive to direct light stimulation, and a relative afferent pupillary defect was detected. Brain perfusion computed tomography showed asymmetrically decreased perfusion involving the left cerebral hemisphere, including the territories of the anterior and middle cerebral arteries (ACA and MCA, respectively); and the ischemic penumbra involving the precentral portion of the left MCA territory (Fig. 1). Brain angiography computed tomography revealed intraarterial filling defect, and occlusion and partial occlusion of the distal portions of the left M2 superior division branch and A2, respectively (Fig. 2). In addition, diffusion-weighted imaging revealed hyperacute and embolic infarctions involving the anterior and posterior portions of the left MCA territory, respectively; and hyperacute infarction of the cortex of the left ACA territory. Subtle

hypointensity was noted in the corresponding regions on the apparent diffusion coefficient map (Fig. 3). Ophthalmologic examinations showed no pupillary reflex, pallid optic disc swelling, and widespread retinal whitening in the left eye. Fundus examination revealed severe corneal opacity, ischemic retina, and a cherry red spot with intra-arterial yellowish emboli in several retinal arteries. The intraocular pressure was zero. Because the artery occlusion likely resulted from autologous fat embolization, we speculated that it would not respond well to pharmacologic thrombolysis. However, given the lack of other therapeutic options, thrombolytic agents were administered. As suspected, the treatment was ineffective. During hospitalization, anti-cardiolipin IgM Ab, protein C, protein S, antiphospholipid Ab, and antithrombin III test were evaluated. The results were all negative or within the normal range. Three months later, the patient was able to walk and raise her arm with minimal resistance. She still had no light perception in the left eye.

## **Discussion**

Autologous fat injection is a common procedure used for skin augmentation, which involves the subcutaneous injection of a patient's fatty tissue containing insignificant quantity of blood (4, 5). The most common complications associated with autologous fat injection are pain, infection, and sepsis. Conversely, patients rarely experience acute and serious complications such as acute visual loss or cerebral infarction (1, 3, 4, 9-13). The face is composed of highly vascularized tissues and many functionally inactive anastomoses between the external and internal carotid arteries, and the excessive force and velocity of the subcutaneous fat injection may cause increase in local pressure like this case (3, 14, 15). Accordingly, locally increased pressure and well-vascularized tissues could be proposed as risk factors for the intravasation of autologous fat particles (1, 4, 10). Particles accidentally injected into arterioles can migrate to the proximal site of the arterial system by reversed flow

against the arterial flow through the ocular and facial vessels and branches of the external carotid arteries, and can subsequently move distally to obstruct the ophthalmic or retinal artery, or other cerebral arteries branching from the internal carotid artery (3, 4, 13, 15). In the present case, we assumed that the autologous fat particles were injected into a distal branch of the ophthalmic artery, such as the supratrochlear artery, and then increased tissue pressure allowed the fat particles to pass through the anastomoses and reach the choroidal and retinal circulation, thereby sending the emboli into the upper division of the middle cerebral artery (Fig. 4). Subsequently, the fat particles likely moved distally into a branch of the ophthalmic artery and induced vision loss. Because the peripheral arteries of the face are small and collapsible, blood may not appear in the delivering syringe during aspiration despite entry of the needle into an arterial lumen (3). Moreover, as the materials injected are fat, blood, and saline solution, thrombolytic agents such as intra-arterial thrombolysis with urokinase would play only a limited role in the recanalization process.

The physician must be careful to exert minimal force with the lowest possible pressure while injecting fat into the glabella and periorbital areas (3, 16, 17). In addition, when patients undergoing filler injection at face develop abrupt mental change, hemiplegia, ocular pain, or blindness, physicians must consider cerebral infarction and combined retinal artery occlusion caused by autologous fat particle injection. Moreover, the patient should be given the explanation of complications before procedure.

## References

1. Egido JA, Arroyo R, Marcos A, Jiménez-Alfaro I. Middle cerebral artery embolism and unilateral visual loss after autologous fat injection into the glabellar area. *Stroke*. 1993;24:615-616.
2. Chajchir A, Benzaquen I. Fat grafting injection for soft tissue augmentation. *Plast Reconstr Surg*. 1989;84:921-934.
3. Park SW, Woo SJ, Park KH, Huh JW, Jung CK, Kwon OK. Iatrogenic retinal artery occlusion caused by cosmetic facial filler injections. *Am J Ophthalmol*. 2012;154:653–662.
4. Park SJ, Woo SJ, Park KH, Hwang JM, Hwang GJ, Jung CK, et al. Partial recovery after intraarterial pharmacomechanical thrombolysis in ophthalmic artery occlusion following nasal autologous fat injection. *J Vasc Interv Radiol*. 2011; 22:251–254.
5. Chajchir A. Fat injection: long-term follow-up. *Aesthetic Plast Surg*. 1996; 20:291–296.
6. Mori K, Ohta K, Nagano S, Toshinori M, Yago T, Ichinose Y. A case of ophthalmic artery obstruction following autologous fat injection in the glabellar area. *Nippon Ganka Gakkai Zasshi*. 2007;111:22–25.
7. Dreizen NG, Framm L. Sudden unilateral visual loss after autologous fat injection into the glabellar area. *Am J Ophthalmol*. 1989;107:85– 87.
8. Feinendegen DL, Baumgartner RW, Vuadens P, Schroth G, Mattle HP, Regli F, et al. Autologous fat injection for soft tissue augmentation in the face: a safe procedure? *Aesthetic Plast Surg*. 1998;22:163–167.

9. Teimourian B. Blindness following fat injections. *Plast Reconstr Surg.* 1988; 82:361.
10. Feinendegen DL, Baumgartner RW, Schroth G, Mattle HP, Tschopp H. Middle cerebral artery occlusion and ocular fat embolism after autologous fat injection in the face. *J Neurol.* 1998; 245:53–54.
11. Yoon SS, Chang DI, Chung KC. Acute fatal stroke immediately following autologous fat injection into the face. *Neurology.* 2003; 61:1151–1152.
12. Edwards AO. Central retinal artery occlusion following forehead injection with a corticosteroid suspension. *Pediatr Dermatol.* 2008; 25:460–461.
13. Lee CM, Hong IH, Park SP. Ophthalmic artery obstruction and cerebral infarction following periocular injection of autologous fat. *Korean J Ophthalmol.* 2011;25:358-361.
14. Lee YJ, Kim HJ, Choi KD, Choi HY. MRI restricted diffusion in optic nerve infarction after autologous fat transplantation. *Journal of Neuro-Ophthalmology.* 2010;30:216–218.
15. Ellis PP. Occlusion of the central retinal artery after retrobulbar corticosteroid injection. *Am J Ophthalmol.* 1978;85:352-356.
16. Hong DK, Seo YJ, Lee JH, Im M. Sudden visual loss and multiple cerebral infarction after autologous fat injection into the glabella. *Dermatol Surg.* 2014;1–3.
17. Kwon DY, Park MH, Koh SB, Dhong ES, Baek SH, Ryu HJ, et al. Multiple arterial embolism after illicit intranasal injection of collagenous material. *Dermatol Surg.* 2010;36:1196–1199.



## Figure Legends

Figure 1. Brain perfusion computed tomography showed asymmetrically decreased perfusion involving the left cerebral hemisphere.

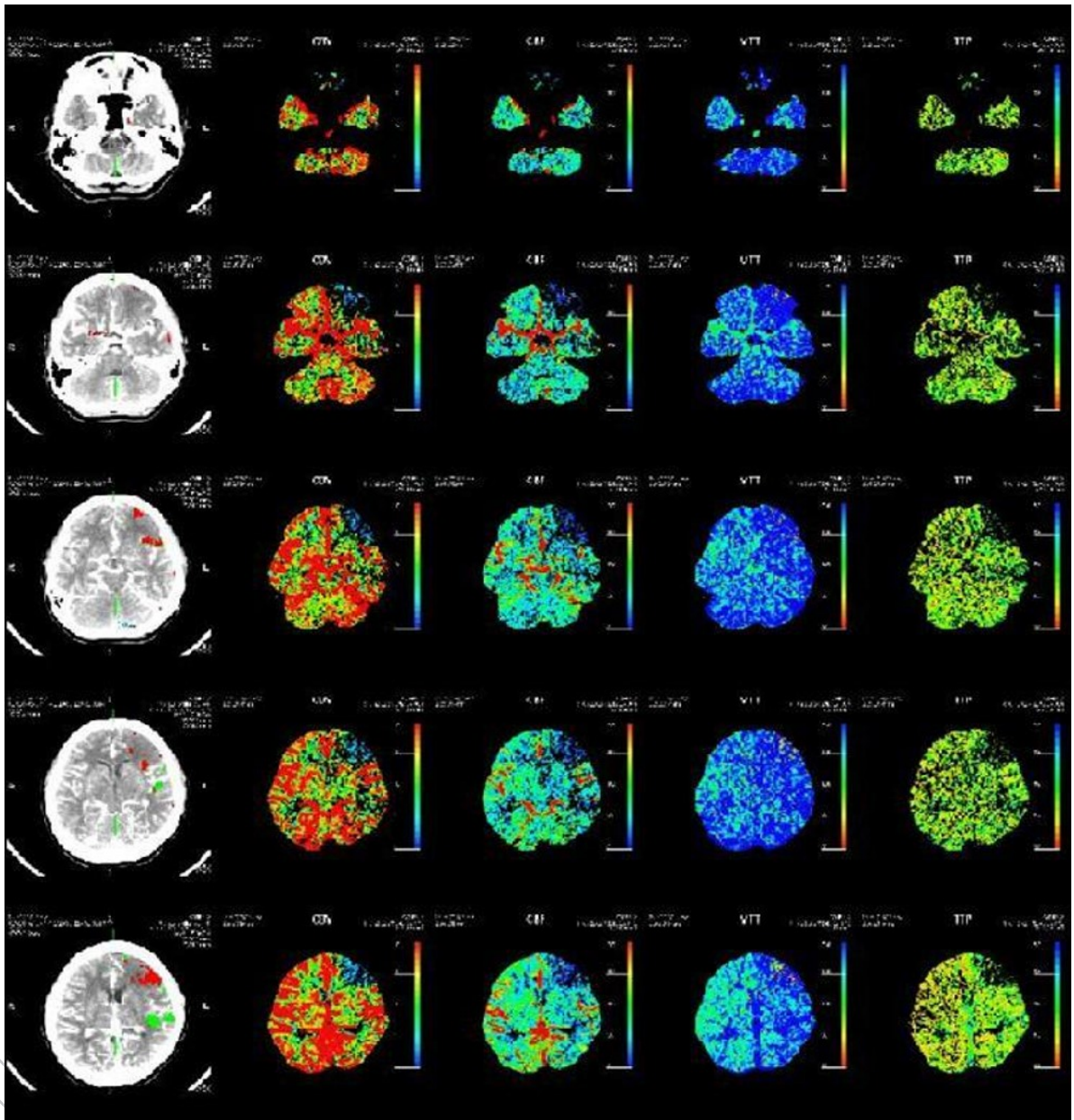


Figure 2. Brain computed tomography angiography with contrast showed intra-arterial filling defect and occlusion of the distal portion of the left M2 superior division branch.

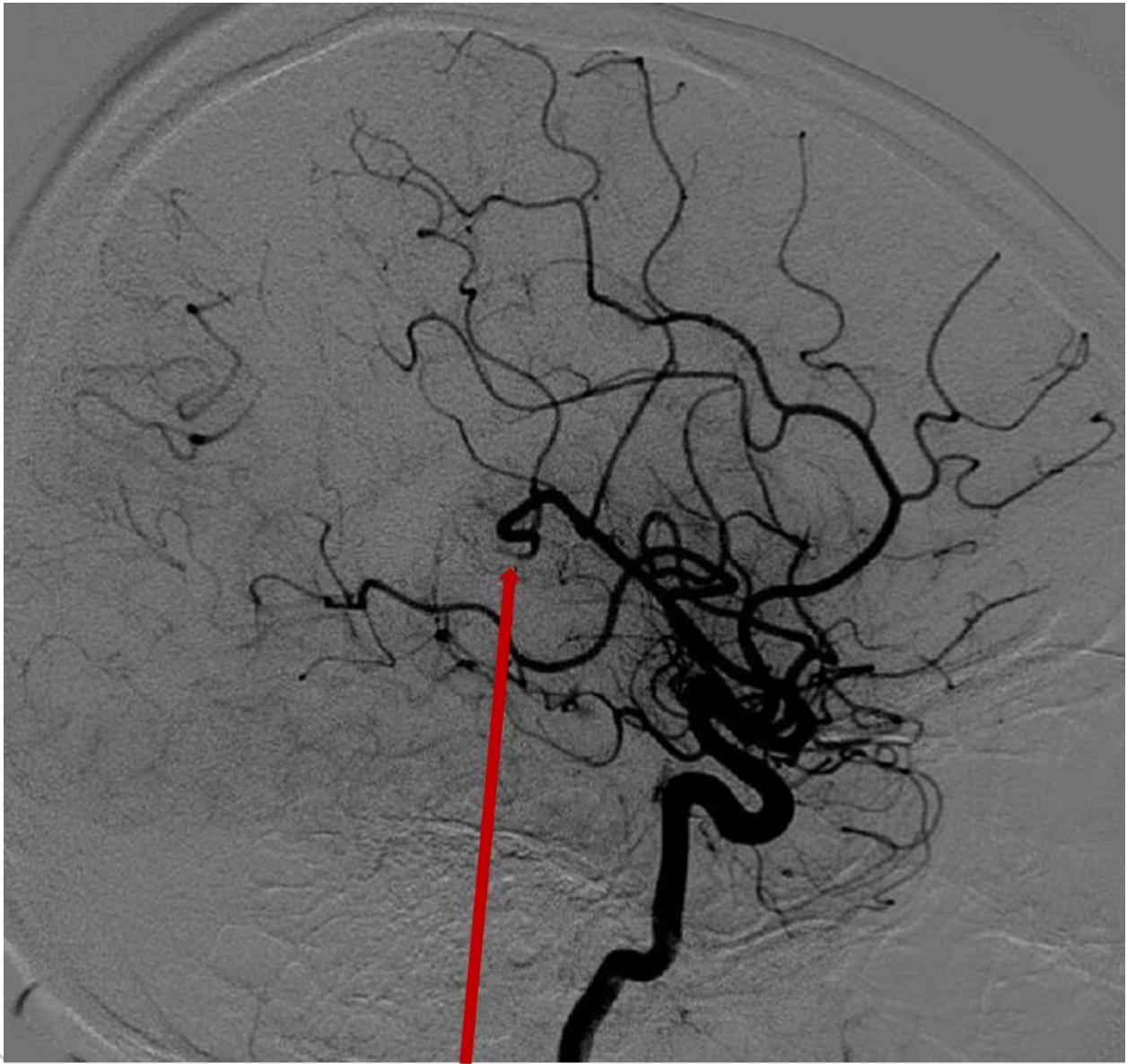


Figure 3. Diffusion-weighted magnetic resonance imaging demonstrated hyperacute infarction involving the anterior and posterior portions of the left middle cerebral artery territory.

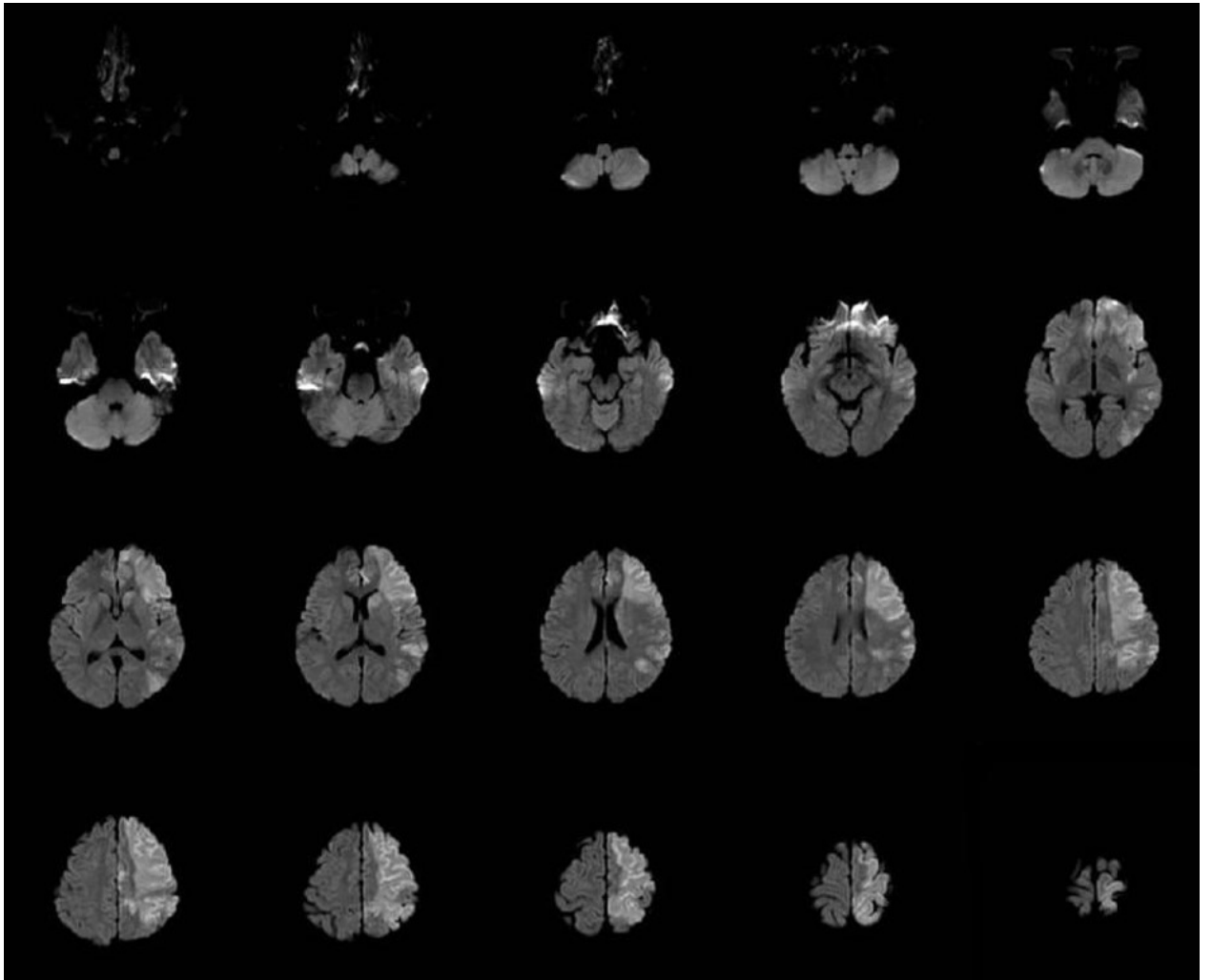
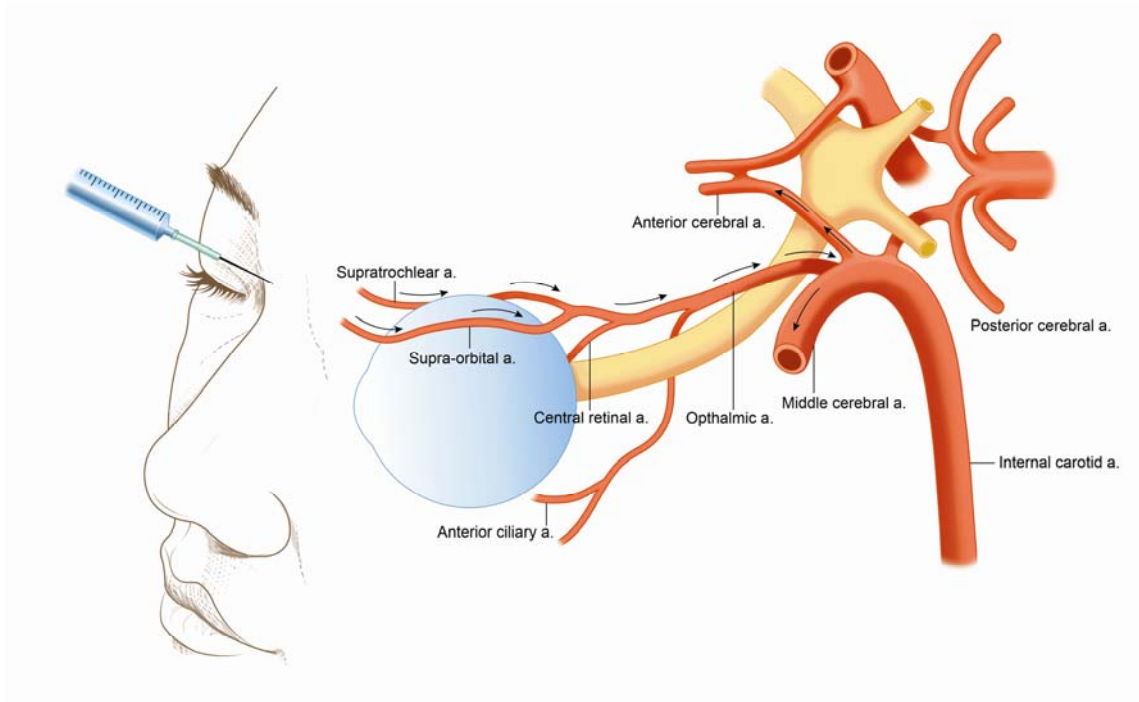


Figure 4. Schematic of the vasculature of the face and periocular area in relation to the site of cosmetic autologous fat injection to the anterior and middle cerebral arteries. The arrows indicate the route of retrograde flow of embolic fat particles.



JUST A