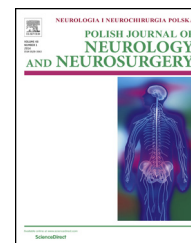


Available online at [www.sciencedirect.com](http://www.sciencedirect.com)

ScienceDirect

journal homepage: <http://www.elsevier.com/locate/pjnns>

## Short communication

# Novel mutation of the NOTCH3 gene in a Polish family with CADASIL

Julia Buczek<sup>a,\*</sup>, Beata Błażejewska-Hyżorek<sup>a</sup>, Agnieszka Cudna<sup>a,b</sup>,  
Małgorzata Lusawa<sup>c</sup>, Eliza Lewandowska<sup>d</sup>,  
Iwona Kurkowska-Jastrzębska<sup>a,b</sup>, Anna Członkowska<sup>a,b</sup>

<sup>a</sup> 2nd Department of Neurology, Institute of Psychiatry and Neurology, Warsaw, Poland<sup>b</sup> Department of Clinical and Experimental Pharmacology, Medical University of Warsaw, Warsaw, Poland<sup>c</sup> Department of Radiology, Institute of Psychiatry and Neurology, Warsaw, Poland<sup>d</sup> Department of Neuropathology, Institute of Psychiatry and Neurology, Warsaw, Poland

## ARTICLE INFO

## Article history:

Received 9 December 2015

Accepted 14 April 2016

Available online xxx

## Keywords:

Cerebral autosomal dominant  
arteriopathy with subcortical  
infarcts and leukoencephalopathy  
NOTCH3

Novel mutation

Phenotypic variability

## ABSTRACT

Cerebral autosomal dominant arteriopathy with subcortical infarcts and leukoencephalopathy (CADASIL) is an inherited small blood vessels disease caused by mutations in the gene encoding the neurogenic locus notch homolog protein 3 (NOTCH 3). We present a Polish family with a previously unreported novel mutation in exon 12 c.1851C>C/G of the NOTCH3 gene and varying disease expression. One of the two family members with the confirmed mutation presented with all the main CADASIL symptoms; while, his affected father was nearly asymptomatic. Both family members had epilepsy, coronary artery disease, and abdominal aorta aneurysm. Our observation confirms there is phenotypic variability in CADASIL not only between, but also within, families carrying the same mutation.

© 2016 Polish Neurological Society. Published by Elsevier Sp. z o.o. All rights reserved.

## 1. Introduction

Cerebral autosomal dominant arteriopathy with subcortical infarcts and leukoencephalopathy (CADASIL) is rare single gene disorders causing cerebral small vessels disease. The main clinical symptoms of CADASIL are migraine with aura, lacunar strokes, cognitive impairment, mood disturbances, and apathy. The pathognomonic vascular feature of the disease is the presence of granular osmiophilic material

(GOM) deposits in the brain and other organs. CADASIL is caused by mutations in the NOTCH3 gene, encoding the transmembrane receptor Notch3 that contains 34 epidermal growth factor-like (EGF-like) repeats in its extracellular domains. Each EGF-like repeat contains six cysteine residues. Most mutations occur in exons 2–24 of NOTCH3 gene, encoding the extracellular domain of the receptor. All CADASIL mutations identified so far result in odd numbers of cysteine residues within EGF-like repeats in extracellular domains. It is unclear if mutations not altering EGF-like repeats are

\* Corresponding author at: 2nd Department of Neurology, Institute of Psychiatry and Neurology, ul. Sobieskiego 9, 02-957 Warsaw, Poland. Tel.: +48 224582874; fax: +48 228429322.

E-mail address: [jbuczek@ipin.edu.pl](mailto:jbuczek@ipin.edu.pl) (J. Buczek).

<http://dx.doi.org/10.1016/j.pjnns.2016.04.008>

0028-3843/© 2016 Polish Neurological Society. Published by Elsevier Sp. z o.o. All rights reserved.

associated with CADASIL. We present a Polish family with a previously unreported novel missense mutation in exon 12, c.1851C>C/G of the *NOTCH3* gene and varying disease severity.

## 2. Case presentations

A 57-year-old man (Patient 1) was referred to our department, a few weeks after the first episode of ischemic stroke, to diagnose diffused white matter changes detected by magnetic resonance imaging (MRI). His medical history (Table 1) and results of the brain MRI raised suspicion of CADASIL. He presented with all hallmark CADASIL symptoms and epilepsy. He had severe coronary artery disease (CAD), post-infarction heart failure with a cardiac ejection fraction of 15%, atrial septal aneurysm (ASA), and abdominal aortic aneurysm (AAA). The ultrastructural examination of skin and muscles vessels showed GOM deposits mainly in arterioles. The detailed results of the skin-muscle biopsy were described elsewhere [1]. Genetic examination revealed a missense mutation c.1851C>C/G in the *NOTCH3* gene that substituted tryptophan for cysteine at residue 521 (C617W). During the next 2 years, the patient deteriorated gradually in cognitive function, and suddenly died at the age of 59, probably due to abdominal aneurysm rupture. No post-mortem examination was carried out.

His father, at the age of 84 (Patient 2), had the genetic test performed of *NOTCH3* gene according to the protocols for

presymptomatic testing for Huntington disease. The same mutation was confirmed. He had no clinical manifestation of CADASIL, besides epilepsy. The AAA and CAD were also diagnosed, but were less severe than in his son (Table 1). The MRI scan showed typical diffuse hyperintensities in temporal lobes and cerebral white matter. Ultrastructural examination of the skin and muscle vessels revealed GOM deposits. They were barely visible in arterioles and were not found in capillary vessels (detailed results were previously described [2]). To date, he remains stable and independent in activities of daily living. The family pedigree is depicted in Fig. 1. The daughter of Patient 1 has epilepsy and migraine headaches, but decided against genetic testing. The mother of Patient 2 died at the age of 62 due to heart disease; she also suffered from depression. Patients 1 and 2 have no siblings.

## 3. Discussion

To the best of our knowledge, this paper represents the first case report of a novel heterozygous missense mutation of the *NOTCH3* gene, c.1851C>C/G, in exon 12, resulting in the p.C716W substitution in its extracellular domain. To date, more than 170 different mutations of *NOTCH3* have been recorded, but only one mutation, c.1918C>T, p. Arg640Cys, in exon 12 [3]. Exons 3 and 4 are mutation hotspots, and other mutation cluster regions have been described in certain population groups [4,5].

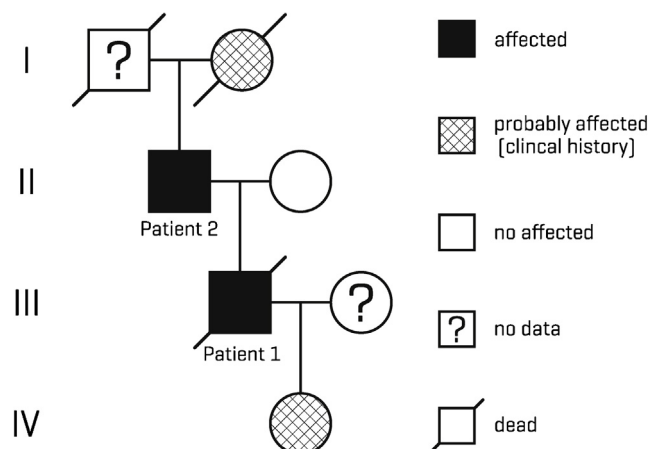
This report presents distinct clinical phenotypes ranging from severe (Patient 1) to almost asymptomatic (Patient 2) in a family carrying the same mutation. Patient 1 had the typical clinical phenotype for CADASIL; while, Patient 2 had only the neuroradiological features of the disease. Clinical heterogeneity between and even within CADASIL families has been described before, but few cases with minimal symptoms and a diagnosis after the age of 80 years have been reported [6].

Both of our patients had a history of AAA and CAD, with different disease severities. We did not find any report of the coexistence of CADASIL and AAA, but typical CADASIL vascular changes have been found in large arteries, such as the aorta and carotid. Premature coronary artery disease and increased risk of early acute myocardial infarction in CADASIL

**Table 1 – Medical history, radiological findings, and disability/dependence scale.**

	Patient 1 Son	Patient 2 Father
<b>Age of diagnosis (years)</b>	57	84
<b>Main CADASIL symptoms</b>		
Stroke	+	–
Migraine	+	–
Cognitive impairment	+	–
Mood disturbances	+	–
Apathy	+	–
<b>Other symptoms</b>		
Epilepsy	+	+
Abdominal aortic aneurysm	+	+
Dimension (mm × mm)	57 × 56	30 × 30
Atrial septal aneurysm	+	–
Coronary artery disease with MI	+	+
EF %	15	50
<b>Vascular risk factors</b>		
Hypertension	–	+
Tobacco use	+	–
Hyperlipidemia	–	–
<b>Brain MRI</b>		
Modified Scheltens' scale (0–120)	86	55
External capsule hyperintensity	+	+
Temporal lobe hyperintensity	+	+
ACE-R/MMSE (0–100)/(0–30)	78/25	91/29
Barthel ADL Index (0–20)	13	20
MRS (0–6)	3	1

Key: +, present; –, absent; MI, myocardial infarction; EF, ejection fraction; ACE-R, Addenbrooke's cognitive examination-revised; MMSE, mini-mental state examination; ADL, activities of daily living; MRS, modified ranking scale.



**Fig. 1 – Pedigree of the investigated family.**

patients have been reported [7]. Typical CADASIL arteriopathic changes have been shown in coronary microvasculature [8]. On the other hand, in a small case-control study of 23 CADASIL patients, there were no ECG signs evoking myocardial infarction or myocardial ischemia [9]. As in Patient 1, ASA was also described in four CADASIL patients from Italy [10]. The relationship between all of these findings and the disease is uncertain.

#### 4. Conclusions

Our results confirm the need to analyze all 23 exons encoding the extracellular domain of the *NOTCH3* gene in patients suspected of CADASIL, especially in countries with unknown mutation spectrums, such as Poland. The CADASIL manifestation is mainly restricted to the brain, but other organs are also affected and other non-neurological symptoms and signs may occur during the course of the disease.

#### Conflict of interest

None declared.

#### Acknowledgement and financial support

This work was supported by grants from the Polish Ministry of Science and Higher Education (grant no. NN402375039). We thank Grażyna Gromadzka for implementation of the *NOTCH3* sequence analysis.

#### Ethics

The work described in this article has been carried out in accordance with The Code of Ethics of the World Medical Association (Declaration of Helsinki) for experiments involving humans; Uniform Requirements for manuscripts submitted to Biomedical journals.

#### REFERENCES

- [1] Lewandowska E, Wierzbą-Bobrowicz T, Buczek J, Gromadzka G, Dziewulska D. CADASIL patient with extracellular calcium deposits. *Folia Neuropathol* 2013;51(4):302–11.
- [2] Lewandowska E, Felczak P, Buczek J, Gramza K, Rafałowska J. Blood vessel ultrastructural picture in a CADASIL patient diagnosed at an advanced age. *Folia Neuropathol* 2014;52(4):443–51.
- [3] Leiden Open Variation Database (LOVD), [http://grenada.lumc.nl/LSDB\\_list/lsdbs/notch3](http://grenada.lumc.nl/LSDB_list/lsdbs/notch3) [accessed 30.11.15].
- [4] Lee YC, Liu CS, Chang MH, Lin KP, Fuh JL, Lu YC, et al. Population-specific spectrum of *NOTCH3* mutations, MRI features and founder effect of CADASIL in Chinese. *J Neurol* 2009;256(2):249–55.
- [5] Bianchi S, Zicari E, Carluccio A, Di Donato I, Pescini F, Nannucci S, et al. CADASIL in central Italy: a retrospective clinical and genetic study in 229 patients. *J Neurol* 2015;262(1):134–41.
- [6] Lee YC, Yang AH, Soong BW. The remarkably variable expressivity of CADASIL: report of a minimally symptomatic man at an advanced age. *J Neurol* 2009;256(6):1026–7.
- [7] Rubin CB, Hahn V, Kobayashi T, Litwack A. A report of accelerated coronary artery disease associated with cerebral autosomal dominant arteriopathy with subcortical infarcts and leukoencephalopathy. *Case Rep Cardiol* 2015;2015:e.167513. <http://dx.doi.org/10.1155/2015/167513>
- [8] Lesnik Oberstein SA, Jukema JW, Van Duinen SG, Macfarlane PW, van Houwelingen HC, Breuning MH, et al. Myocardial infarction in cerebral autosomal dominant arteriopathy with subcortical infarcts and leukoencephalopathy (CADASIL). *Medicine (Baltimore)* 2003;82(4):251–6.
- [9] Cumurciuc R, Henry P, Gobron C, Vicaute E, Bousser MG, Chabrier H, et al. Electrocardiogram in cerebral autosomal dominant arteriopathy with subcortical infarcts and leukoencephalopathy patients without any clinical evidence of coronary artery disease: a case-control study. *Stroke* 2006;37(4):1100–2.
- [10] Rago M, Pianese L, Cacchiò G, Manca A, Scarcella M, Silvestri S, et al. Multi-organ investigation in 16 CADASIL families from central Italy sharing the same R1006C mutation. *Neurosci Lett* 2012;6(1):116–212.