

1
2
3
4 **Brain mechanisms of recovery from pure alexia:**
5
6
7
8 **a single case study with multiple longitudinal scans**
9

10
11
12
13
14 Laurent Cohen^{1,2,3,4,5}, Stanislas Dehaene^{6,7}, Samantha McCormick^{8,9},

15
16 Szonya Durant⁸, Johannes M. Zanker⁸
17
18
19
20
21
22

23 ¹ Inserm, U 1127, F-75013, Paris, France
24

25 ² Sorbonne Universités, UPMC Univ Paris 06, UMR S 1127, F-75013, Paris, France
26

27 ³ AP-HP, Hôpital de la Pitié Salpêtrière, Department of Neurology, F-75013, Paris, France
28

29 ⁴ CNRS, UMR 7225, F-75013, Paris, France
30

31 ⁵ Institut du Cerveau et de la Moelle épinière, ICM, F-75013, Paris, France
32

33 ⁶ Collège de France, Place Marcelin Berthelot, 75005, Paris, France
34

35 ⁷ Cognitive Neuroimaging Unit, CEA DSV/I2BM, INSERM, Université Paris-Sud, Université Paris-Saclay,
36 NeuroSpin center, 91191 Gif/Yvette, France
37

38 ⁸ Department of Psychology, Royal Holloway, University of London, Egham, TW20 0EX, UK
39

40 ⁹ Department of Psychology, University of Roehampton, Whitelands College, Holybourne Avenue,
41 London, SW15 4JD, UK
42
43
44
45
46
47
48
49
50
51
52
53
54
55
56
57
58
59
60
61
62
63
64
65

Abstract

1 Pure alexia is an acquired reading disorder, typically due to a left occipito-temporal lesion affecting
2 the Visual Word Form Area (VWFA). It is unclear whether the VWFA acts as a unique bottleneck for
3 reading, or whether alternative routes are available for recovery. Here, we address this issue through
4 the single-case longitudinal study of a neuroscientist who experienced pure alexia and participated in
5 17 behavioral, 9 anatomical, and 9 fMRI assessment sessions over a period of two years. The origin of
6 the impairment was assigned to a small left fusiform lesion, accompanied by a loss of VWFA
7 responsivity and by the degeneracy of the associated white matter pathways. fMRI experiments
8 allowed us to image longitudinally the visual perception of words, as compared to other classes of
9 stimuli, as well as the mechanisms of letter-by-letter reading. The progressive improvement of
10 reading was not associated with the re-emergence of a new area selective to words, but with
11 increasing responses in spared occipital cortex posterior to the lesion and in contralateral right
12 occipital cortex. Those regions showed a non-specific increase of activations over time and an
13 increase in functional correlation with distant language areas. Those results confirm the existence of
14 an alternative occipital route for reading, bypassing the VWFA, but they also point to its key
15 limitation: the patient remained a slow letter-by-letter reader, thus supporting the critical
16 importance of the VWFA for the efficient parallel recognition of written words.
17
18
19
20
21
22
23
24
25
26
27
28
29
30
31
32
33
34
35
36
37
38
39
40
41
42
43
44
45
46
47
48
49
50
51
52
53
54
55
56
57
58
59
60
61
62
63
64
65

Introduction

Pure alexia is a reading disorder due to an isolated impairment of visual orthographic encoding. It results from left occipito-temporal lesions (Dejerine, 1892; Starrfelt and Shallice, 2014), and critical lesions have been pinpointed at or near the so-called Visual Word Form Area (VWFA), a category-selective region which is crucial for the visual identification of letters and combinations of letters (Cohen et al., 2000; Cohen et al., 2003a; Gaillard et al., 2006; Pflugshaupt et al., 2009; Woodhead et al., 2013). In a patient with a small lesion and a selective deficit, left occipitotemporal activations selective for alphabetic stimuli were abolished, while activations were unimpaired in neighboring areas selective for faces, places, or objects (Gaillard 2006).

While the causes of pure alexia are thus beginning to be uncovered, the mechanisms of its recovery remain uncertain. The goal of this paper is to contribute to this issue by taking advantage of a rather exceptional situation, in which one of the authors, a neuroscientist, became a pure alexic, and underwent a series of repeated behavioral and fMRI assessments over a period of two years. Here, we carefully examine the evolution of his performance, brain anatomy, and brain activation in fMRI. We use these results to shed some light on the reorganization of the ventral visual pathway during recovery from pure alexia, and the issue of the existence of several visual routes for reading (Richardson et al., 2011).

In the existing literature, there is both controversy and considerable inter-individual variability concerning the brain mechanisms of recovery. First, only a small minority of pure alexic patients, known as global alexics (Dejerine, 1892), are actually unable to identify even single letters. Most patients retain the ability to decipher words letter by letter (LBL), a strategy whose behavioral marker is a word length effect, i.e. a reading time proportional to the number of letters in words (e.g. Cumming et al., 2006). Moreover, reading latencies for each component letter are longer than normal, further reducing reading speed (Ingles and Eskes, 2008).

Few functional imaging studies have investigated the physiology of LBL reading. They reveal both similarities and discrepancies across patients regarding the visual and the verbal components of LBL reading. Cohen et al (2004) studied a patient who had undergone extensive surgical removal of her left occipito-temporal region. She exhibited abnormally strong activations in right occipito-temporal cortex by all types of alphabetic strings relative to checkerboards. Those activations were larger during reading of real words relative to the perception of illegible consonant strings, further supporting a role of right occipito-temporal cortex in LBL reading in this patient. A similar pattern prevailed in another patient with LBL reading due to a large posterior cerebral artery stroke (Cohen et al., 2003b). However, in a third patient with a very small surgical lesion disconnecting the VWFA,

1 Gaillard et al. (2006; Epelbaum et al., 2008) showed that orthographic input during LBL reading was
2 not achieved by the right-hemispheric visual system, but by intact cortex posterior to the lesion. Such
3 was also the case in the patient reported by Seghier et al. (2012), whose results suggested that the
4 left occipital cortex provided input to superior temporal and frontal regions, bypassing the lesioned
5 VWFA.
6
7

8
9 Even fewer studies address the brain correlates of the improvement of the patients' reading speed
10 over time. In a follow-up study of the surgical patient reported by Cohen et al. (2004a), Henry et al.
11 (2005) showed that as the patient's reading became faster, activations by alphabetic stimuli
12 decreased in the visual cortex, while the fronto-parietal activations associated with LBL reading
13 increased. Using magnetoencephalography (MEG), Woodhead et al. (2013) showed that 6 weeks of
14 whole-word reading training in pure alexics yielded an increase in functional correlation between the
15 inferior frontal, the ventral occipitotemporal, and the occipital cortices of the left hemisphere, for
16 trained versus untrained items.
17
18

19 In summary, the existing evidence on recovery from pure alexia, while scarce, is not fully convergent.
20 Some of the reported cases seem to reacquire a reading-related region analogous to the VWFA in
21 ventral occipito-temporal cortex, either near the lesion, or in the contralateral hemisphere. Others,
22 however, seem to bypass the VWFA entirely and may read via direct occipital input to language
23 regions (Seghier et al., 2012) (see also Cohen et al. (2004b)). The goal of the present paper was to
24 document, in unprecedented temporal detail, what happened in patient JMZ. As we shall see, JMZ
25 experienced a near-selective destruction of the VWFA and yet re-acquired reading. We obtained 9
26 longitudinal fMRI scans in JMZ, thus offering a unique opportunity to adjudicate between two
27 theories of recovery: re-emergence of a functional VWFA, or direct occipital bypass. What we
28 observed in JMZ was just one of the possible trajectories in recovery, and only multiple comparisons
29 among cases longitudinally studied in similar detail could provide a fair idea about the brain
30 mechanisms of recovery from pure alexia.
31
32
33
34
35
36
37
38
39
40
41
42
43
44
45
46
47

48 **Medical history**

49 The patient (JMZ, the last author of this paper) is a right-handed man with no significant medical
50 history, a neuroscientist with a faculty position at a UK university. His native language is German, but
51 he had been living and teaching in English-speaking countries for more than 20 years. At the age of
52 54, he suffered from a stroke revealed by the sudden occurrence of a reading impairment. On initial
53 clinical examination, there was right homonymous hemianopia, maximal along the horizontal
54 meridian, without macular sparing (Figure 1A, perimetry at day 4), and severe alexia leading on to
55
56
57
58
59
60
61
62
63
64
65

1 very slow letter-by-letter reading. Spelling, oral language comprehension and production were
2 unimpaired. Hemianopia receded partially over the following weeks, persisting mostly along the
3 horizontal meridian, still without macular sparing (Figure 1A, perimetry at day 44). Anatomical MRI
4 showed a small infarct in the territory of the left posterior cerebral artery (Figure 1B). The present
5 study was carried out over the following 2 years, during which the patient practiced reading on his
6 own on a daily basis whilst returning to his academic duties, and his reading abilities improved
7 gradually.
8
9

10
11
12 JMZ observed his condition carefully from the day of his infarct. Initially, all letters appeared as
13 unordered, unstable, and difficult to segment into meaningful words. JMZ observed that he was able
14 to write isolated words and short text segments from memory (in English, German, and Latin) as long
15 as he refrained from looking at the notepaper (on inspection of the written text, he tried to correct
16 what he perceived as ubiquitous spelling errors). Using a note book, he started copying words from
17 his environment and trying to decipher them. Two days after the stroke, he succeeded in deciphering
18 individual letters by effortful reconstruction from line segments, and then combining them into letter
19 strings which he compared with memorized spelling of words. Mirror-image letter confusions (such
20 as d b p q) were a particular problem. Three weeks after his stroke, JMZ managed to read his first
21 sentence from a news magazine article, very slowly and with great effort. Five years later, in spite of
22 objective progress (documented further below), he still felt impaired with quick recognition of
23 mirror-image letters, acronyms, noisy or low-visual contrast texts, dense or unstructured typesets,
24 and handwriting.
25
26
27
28
29
30
31
32
33
34
35

36 37 **Methods**

38 39 **Time line of testing**

40
41
42 Between the first month (day 24) and the 19th month (day 575) after the stroke, JMZ participated in
43 10 sessions of behavioral assessment of word reading, 17 sessions of behavioral assessment of text
44 reading, and 9 sessions of fMRI of word reading and object perception (Figure 2). He also participated
45 in an fMRI language localizer experiment during the 24th month (day 726). Anatomical T1-weighted
46 images were acquired at the same time as the 9 fMRI sessions, and diffusion images were acquired
47 during the 23rd month (day 708).
48
49
50
51
52

53 54 **Behavioral assessment**

55 56 **Word reading**

57
58 JMZ's reading speed of for isolated English words was measured between day 116 and day 661 after
59 the infarct. Seven word lists were created, each comprising 18 words for each of the word lengths of
60
61
62
63
64
65

1
2
3
4
5
6
7
8
9
10
11
12
13
14
15
16
17
18
19
20
21
22
23
24
25
26
27
28
29
30
31
32
33
34
35
36
37
38
39
40
41
42
43
44
45
46
47
48
49
50
51
52
53
54
55
56
57
58
59
60
61
62
63
64
65

3, 4, 5, 6, 7, and 8 letters. Word frequency was matched across length groups within each list (Francis and Kucera, 1982). In each session, one of those lists was presented, with the words in random order. Words were presented on the computer screen at a viewing distance of ca. 40 cm to JMZ who was wearing his prescribed reading glasses. He initiated the experiment by a key press, after which for each stimulus (i) a central fixation target appeared on the screen for 500 ms; which then (ii) was replaced by the stimulus word displayed in lower case courier font (0.25 deg letter size) dark on bright background, one space to the right of the fixation point, for 5000 ms, and the JMZ was instructed to speak the presented word as soon as he had recognized it; followed (iii) by a blank screen shown for 200 ms before the next stimulus cycle started. Response was recorded with a head-mounted microphone through the voice input of the computer. The latency of reading onset was determined off line for each single word from the digital audio record and recognition errors were flagged. From these data, for each session and word length the average response time and the percentage of recognition errors were computed.

Text reading

Between day 24 and day 793 after the infarct, video recordings were made of JMZ reading short paragraphs of narrative texts previously not seen, in English and German, to assess natural reading speed. Text segments (50 – 200 words, initially taken from newspaper clips, after 2 months all taken from Bill Bryson's 'The lost continent' and its German translation) were printed on a white A4 sheet in black letters (12 pt Times Roman font, 1.5 lines spacing) and placed at a standard reading distance of 40 cm. The overall reading time was measured, allowing to determine the average reading time per word. No attention was given to errors and corrections of individual words, but they were part of the measured reading time. Within each session, one English and one German text from different sections of the source were presented, in random order.

T1-weighted anatomical imaging

Acquisition parameters

We used a 3-Tesla MRI (Siemens Trio) with an 8-channel head coil for all scanning sessions, apart from the last 2, for which a new 32-channel head coil was used. Structural data were acquired using a T1-weighted 3-D anatomical scan (MPRAGE, Siemens, TR 1830 ms, TE 3.03 ms, flip angle 11°, resolution 1×1×1 mm³).

Data processing and statistical analysis

T1 images were processed using the SPM8 software. Lesion topography was described on the basis of the image acquired during the first session, normalized to the MNI space. We used voxel-based

1 morphometry (VBM) as implemented in the VBM8 toolbox (<http://www.neuro.uni-jena.de/vbm>) to
2 study the evolution of grey and white matter density over time (Ashburner and Friston, 2000;
3 Ashburner, 2010). To this end, we segmented the T1 images into white and gray matter images,
4 which were warped into each other across sessions to generate a template in MNI space. Finally,
5 smoothed, spatially normalized and scaled grey and white matter images were generated in MNI
6 space for each session, and were entered in a linear regression model (absolute threshold masking
7 set at 0.05), with session number as regressor. We used a statistical threshold of voxelwise $P < 0.001$
8 and clusterwise corrected $P < 0.05$.
9

14 Diffusion tensor imaging

17 Acquisition parameters

18 A total of 70 near-axial slices were acquired on a Siemens 3 Tesla VERIO TIM system equipped with a
19 32-channel head coil. We used an acquisition sequence which provided isotropic ($2 \times 2 \times 2$ mm)
20 resolution and coverage of the whole head with a posterior-anterior phase of acquisition. The
21 acquisition was peripherally-gated to the cardiac cycle with an echo time (TE) of 85 msec. We used a
22 repetition time (TR) equivalent to 24 RR. At each slice location, 6 images were acquired with no
23 diffusion gradient applied. Additionally, 60 diffusion-weighted images were acquired, in which
24 gradient directions were uniformly distributed on the hemisphere with electrostatic repulsion. The
25 diffusion weighting was equal to a b-value of 1500 s/mm^2 .
26
27
28
29
30
31
32
33

34 Data processing and statistical analysis

35 The patient's fractional anisotropy (FA) was compared to a group of 10 matched controls (10 males,
36 45-66 years old, 11-26 years of education). All FA images were normalized, smoothed with an 8 mm
37 isotropic kernel, and the patient's image was compared to controls using a two-sample t-test as
38 implemented in SPM8, masking by the template FA image thresholded above 3. We used voxelwise
39 thresholds of $P < 0.01$ and $P < 0.001$, with a clusterwise threshold of $P < 0.05$ corrected.
40
41
42
43
44
45

46 Functional imaging

48 Activation paradigms

49 *Language localizer*

50 In order to identify the main components of the language network, we used a subpart of a short
51 functional localizer experiment whose details are fully reported in Pinel et al. (2007). To assess
52 auditory language condition, we pooled (1) trials on which the patient had simply to listen to short
53 sentences (10 trials), (2) trials on which sentences instructed the patient to press three times a left or
54
55
56
57
58
59
60
61
62
63
64
65

1 right button (5 trials each), (3) trials on which sentence instructed the patient to solve simple mental
2 arithmetic problems (10 trials). To assess visual language, we pooled the exact equivalent of the
3 auditory conditions, but with visually presented stimuli. Visual sentences were broken down into four
4 successive screens (250 ms) separated by 100 ms blank intervals. Each screen comprised one to three
5 words, resulting on average in 1.3 sec of trial duration per sentence.
6
7

8 *Visual categories*

9
10
11 In order to identify category-selective regions in the visual cortex, we used a stimulation paradigm
12 reported in Gaillard et al. (2006). The patient was presented with an alternation of blocks of pictures
13 (8000 ms per block) and blocks of rest with a central fixation point (7800 ms per block). Each
14 stimulation block included 8 black and white pictures from one of 4 categories: 3-letter words, faces,
15 tools, or houses. Pictures were displayed for 600 ms and followed by a 400 ms blank screen. The
16 experiment included two sequences, each comprising 24 blocks of pictures (6 for each category) and
17 24 blocks of rest. Blocks were presented in pseudo-random order within sequences, so as to
18 maximize the variety of transitions between conditions while avoiding any repetition of the same
19 condition in successive blocks. The patient completed a one-back task in which he had to press a
20 button every time he detected a repetition of an image (behavioral results were not further
21 analyzed).
22
23
24
25
26
27
28
29
30
31

32 *Slow reading*

33
34
35 In order to study the slow letter-by-letter reading procedure, JMZ was submitted to the same
36 imaging procedure as described in Cohen et al. (2003). He was presented with four types of stimuli:
37 rest with a central fixation point, words in English, meaningless consonant strings, and checkerboards
38 covering approximately the same field as letter strings. The 128 words were a subset of the list used
39 for the behavioral assessment, including 42 3-4 letter words, 44 5-6 letter words, 42 7-8 letter words.
40 Consonant strings were matched one-to-one to real words in number of letters. The frequency
41 distribution of consonants was the same in consonant strings as in words. Stimuli were presented
42 centrally for 1700 ms, followed by an 800 ms fixation point. The patient was instructed to pay
43 attention equally to all types stimuli and to read real words covertly. Each session comprised four
44 fMRI runs, each comprising 16 experimental blocks, i.e. 4 blocks of each condition. Each block
45 comprised 8 trials. Blocks were presented in pseudo-random order within sequences, so as to
46 maximize the variety of transitions between conditions while avoiding any repetition of the same
47 condition in successive blocks. Trials were presented in random order within blocks. The order of
48 blocks within sequences and the order of trials within blocks differed across the four sequences.
49
50
51
52
53
54
55
56
57
58
59
60
61
62
63
64
65

Acquisition parameters

We used a 3-Tesla MRI (Siemens Trio) with an 8-channel head coil for the first 7 sessions and 32-channel head coil for the last 2 sessions, and a gradient-echo planar imaging sequence sensitive to brain oxygen-level dependent (BOLD) contrast (35 contiguous axial slices, acquired using ascending interleaved sequence, 2 mm thickness; TR = 2500 ms; Flip angle = 85°, TE = 32 ms, in-plane resolution = 3 × 3 mm, matrix = 64 × 64). For each acquisition, the first 4 volumes were discarded to reach equilibrium. T1-weighted images were also acquired for anatomical localization.

For the language localizer, the scanner parameters were slightly different: 37 axial slices acquired using ascending interleaved sequence, 3 mm thickness; TR = 2400 ms; Flip angle = 85°, TE = 32 ms, in-plane resolution = 3 × 3 mm, matrix = 64 × 64). For each acquisition, the first 5 volumes were discarded to reach equilibrium.

Data processing

Functional images from all 9 sessions were pre-processed together using the SPM8 software as follows: slice timing, motion correction by realignment, coregistration of the first T1-weighted image to the mean functional image, affine normalization of the T1-weighted image to the MNI template, normalization of functional images (resampled voxel size = 3 × 3 × 3 mm) by applying the parameters of the anatomical normalization, and Gaussian smoothing (5 mm FWHM).

Statistical analysis

For each of the three experiments, in order to perform a GLM analysis, each voxel time series was fitted with a linear combination of functions derived by convolving a standard haemodynamic response function with the time series of the stimulus categories. There were thus 1 session * 1 block * 10 conditions = 10 regressors of interest for the Language Localizer, 9 sessions * 2 blocks * 4 conditions = 72 regressors for the Visual Categories experiment, and 9 sessions * 4 blocks * 3 conditions = 108 regressors for the Slow Reading experiment. In order to avoid missing peri-lesional, anterior ventral and orbitofrontal activations, the default threshold for the SPM8 statistical mask was lowered from 0.8 to 0.4, at the expense of expanding the explored volume and making corrections for multiple comparisons more stringent. Contrast images were computed for comparisons of interest, including contrasts pooling all sessions, and contrasts assessing linear changes over time.

We also used psychophysiological interaction (PPI) analyses (Friston et al., 1997), using SPM8 functionalities as a tool to explore the functional correlation between brain regions. In essence, PPI models the response across the brain as the influence of a seed region and its interaction with experimental conditions. We defined regions of interest (ROIs), extracted BOLD signal from those ROIs, and for each ROI performed a GLM analysis whose regressors were the ROI's extracted signal,

1
2
3
4
5
6
7
8
9
10
11
12
13
14
15
16
17
18
19
20
21
22
23
24
25
26
27
28
29
30
31
32
33
34
35
36
37
38
39
40
41
42
43
44
45
46
47
48
49
50
51
52
53
54
55
56
57
58
59
60
61
62
63
64
65

an experimental regressor (e.g. words vs pictures), and their interaction term. Contrasts defined over the interaction term allow to identify regions whose correlation with the ROI changes according to experimental conditions.

For all statistical comparisons we used a clusterwise threshold of $P < 0.05$, corrected for multiple comparisons across the whole brain, with a voxelwise threshold of $P < 0.01$ for the Language Localizer and 0.001 for the Visual Categories and Slow Reading experiments. Contrasts used for masking were thresholded at voxelwise $P < 0.001$, unless stated otherwise.

Behavioral results

During the 19 months of testing, reading performance improved steadily and was well fit by decreasing power law functions (Table 1). English text reading speed improved from 7.1 s/word at day 4 after the stroke, to 1.6 s/word at day 269 (77% improvement), and to 1.4 s/word at day 555 (12% further improvement) (Figure 2A). German reading text followed the same pattern. Similarly, correct word reading decreased from an average word reading latency of 1889 ms/word at day 116, to 1165 ms/word at day 284 (38% improvement), and to 962 ms/word at day 575 (17% further improvement) (Figure 2B). This is almost twice the mean normal latency, as shown in numerous studies, e.g. Ziegler et al. (2001) who found values of about 520 ms in both German and English.

The signature of letter-by-letter reading in pure alexic patients is an increase of reading latency with the number of letters in words (the so-called word length effect). Linear regression indicated that, during the first testing session at day 116, the patient's word length effect had a slope of 225 ms/letter. The slope then decreased over time, parallel to the decrease in average latency, to a value of 65 ms/letter at day 575, still way above the normal range (Cohen et al., 2003a). Those values were again way above the word length effect that may be observed in overt naming, ranging across studies from 0 to less than 20 ms per letter (Hudson and Bergman, 1985; O'Regan and Jacobs, 1992; Weekes, 1997).

With unlimited presentation of the target words, error rates are naturally less sensitive than latencies to reading impairments. Nevertheless, JMZ made about 15% errors (average for all word lengths) during the first two sessions, and then kept an error rate of 5-10% until the last session (Table 1). The error pattern was typical of pure alexia. First, a large majority of errors consisted in real English words (59%), plus some German words (12%; e.g. STADIUM > STUDIUM), no responses (13%), and non-words (16%). Second, most errors affected the final letters of target words (e.g. BALLET > BALLAD, CRUSADE > CRUISE), a known consequence of guessing on the basis of targets' initial part.

Anatomical brain imaging results

Lesion topography from T1-weighted images

The lesion was a narrow slit mostly confined to the occipito-temporal white matter (Figure 1C). Its ventral edge ($x=-50$) affected the lateral branch of the fusiform gyrus, bordering the lateral occipito-temporal sulcus. It extended up to $z=17$ into the white matter, flanking the lateral ventricle. Its maximum anteroposterior extension was at about $z=-6$, spanning from $y=-43$ to $y=-75$. It encompassed the average coordinates of the peak activation of the VWFA found in healthy subjects (e.g. MNI -43 -54 -12; Cohen et al., 2002).

Anatomical evolution over time

Voxel-based morphometry (VBM) across scanning sessions, shows that there was a decrease in white matter (WM) density and an increase in grey matter (GM) density in a set of left posterior regions (Figures 3A and S1). The interpretation of such changes affecting the WM and GM in opposite directions is intrinsically ambiguous. However, one may plausibly attribute those changes to a primary atrophy of fibers affected by the lesion. In addition to those main changes, there was (1) a WM decrease in the splenium of the corpus callosum, and (2) a single region of increase in WM, together with a decrease in GM (MNI -57 -63 7), in a small left posterior superior temporal sulcus (STS)/middle temporal gyrus (MTG) patch. We checked that those VBM changes could not be due to anatomical deformations occurring in the vicinity of the lesions over time. To this end, the 9 T1-weighted anatomical images were aligned, and slices including or neighboring the lesion were inspected. No changes whatsoever could be detected in the geometry of the lesion, and no shift in the cortical surface over time.

The voxelwise comparison of the patient's fractional anisotropy (FA) map to a set of control subjects (Figure 3B), confirmed the existence of white matter abnormalities in the left temporal lobe, showing an extensive reduction of FA overlapping with the areas of reduced WM density. FA reduction overlapped with the inferior longitudinal fasciculus (ILF), the inferior fronto-occipital fasciculus (IFOF), and possibly the posterior segment of the arcuate fasciculus, as identified from the atlas by Thiebaut et al. (2011), thresholded at 75% of subjects (Figure 3C).

fMRI results

Language localizer

The language localizer was used once, 24 months after the stroke, in order to identify the main areas involved in auditory, visual, and supramodal language processing (Figure S2).

1
2
3
4
5
6
7
8
9
10
11
12
13
14
15
16
17
18
19
20
21
22
23
24
25
26
27
28
29
30
31
32
33
34
35
36
37
38
39
40
41
42
43
44
45
46
47
48
49
50
51
52
53
54
55
56
57
58
59
60
61
62
63
64
65

Modality-dependent activations were identified by contrasting auditory minus visual sentences, and visual minus auditory sentences, masked respectively by auditory sentences minus rest and by visual sentences minus rest (voxelwise $P < 0.01$). This showed auditory activations in the bilateral STG (left: MNI -63 -19 4, $Z > 8$; right: MNI 72 -10 -2, $Z > 8$), and visual activations in the bilateral occipital (left: MNI -21 -91 4, $Z = 6.41$; right: MNI 18 -91 -5, $Z > 8$), ventral occipito-temporal (left: MNI -33 -79 -17, $Z = 4.45$; right: MNI 39 -67 -14, $Z = 6.77$) and dorsal occipito-parietal cortex (left: MNI -27 -70 28, $Z = 7.55$; right: MNI 33 -64 52, $Z > 8$). Importantly, in the right hemisphere, ventral activations extended rostrally to $y = -55$, while in the left hemisphere they stopped at $y = -76$, just posterior to the lesion.

Supramodal language areas were identified by the conjunction of auditory sentences minus rest and visual sentences minus rest. This showed activations in the left temporo-parietal junction (MNI -48 -46 13, $Z = 5.68$), the left precentral/IFS cortex (MNI -42 5 28, $Z = 5.64$), the left-predominant SMA (MNI -9 8 52, $Z = 5.84$).

Summary

In summary, (1) there was a strong overall left lateralization of supramodal language processing, both in the temporal and frontal lobes, confirming that language was left-lateralized in JMZ; (2) bilateral activations were observed in modality-specific regions for auditory and visual processing; (3) left ventral activations to visual sentences were restricted to the occipital cortex posterior to the lesion, with no activation of the VWFA.

Visual categories experiment

This experiment was run 9 times during JMZ's recovery in order to study longitudinally the loss and potential recovery of category-specific activations to printed words in the visual system. To this end, we briefly presented visual stimuli from four categories (words, faces, houses, and tools). Note that words were presented too briefly to allow JMZ to recognize them accurately from letter-by-letter reading.

Activations pooled over time

We first pooled all 9 acquisition sessions, and looked for category-specific activations (Figure 4A). For each category, we assessed the conjunction contrast of activations induced by this category minus each of the other categories. This showed a typical category-specific mosaic of occipito-temporal activations (Malach et al., 2002; Gaillard et al., 2006): right-hemispheric activations for faces in the FFA (MNI 42 -61 -20, $Z > 8$) and the lateral occipital cortex (MNI 51 -79 -5, $Z > 8$); bilateral activations for tools in the LOC (left: MNI -54 -76 -2, $Z > 8$; right: MNI 54 -70 -5, $Z > 8$) and the occipito-parietal cortex (left: MNI -24 -67 37, $Z = 7.09$; right: MNI 18 -67 49, $Z = 5.69$); bilateral mesial occipito-temporal activations for houses, peaking in the PPA (left: MNI -36 -46 -11, $Z > 8$; right: MNI 30 -40 -11, $Z > 8$), plus

1
2
3
4
5
6
7
8
9
10
11
12
13
14
15
16
17
18
19
20
21
22
23
24
25
26
27
28
29
30
31
32
33
34
35
36
37
38
39
40
41
42
43
44
45
46
47
48
49
50
51
52
53
54
55
56
57
58
59
60
61
62
63
64
65

some more dorsal occipito-parietal activations. Note that the left PPA was contiguous and mesial to the lesion.

In contrast, word-specific activations were conspicuously absent from the classical left occipito-temporal site of the VWFA, and were confined to the tip of the left occipital lobe around the posterior end of the calcarine (MNI -9 -97 -8, $Z>8$; MNI -30 -97 -14, $Z>8$), at a location very similar to reading-related activations observed in normal subjects (Szwed et al., 2011; Szwed et al., 2014; Chang et al., 2015). Extensive word-specific activations were also present in a set of left-predominant language areas, including the 3 supramodal areas identified with the language localizer (TPJ: MNI -60 -46 13, $Z>8$; IFS: MNI -45 11 25, $Z>8$; SMA : MNI -3 -1 58, $Z>8$) and extending to Broca's area (MNI -66 -1 13; $Z>8$) and the left MTG (MNI -72 -37 1; $Z>8$) (Figures 4 and S2).

Increase of selective activations to words over time

We looked for areas showing an increasing selectivity for words relative to the average of other categories over time (Figure 5). We found the same supramodal language regions previously identified with the language localizer (left TPJ: MNI -72 -37 4, $Z=5.11$; left IFS: MNI -48 11 22, $Z=6.72$). At the peaks of those regions, only words showed an increase relative to the average of all categories ($P<0.005$), as shown in curves of activations over time (Figure 5B). It is noteworthy that during the first scanning session, words did not activate those areas relative to rest, and were thus indistinguishable from the other classes of visual stimuli. Importantly, no region of the visual cortex developed a selectivity for words. Finally, the word-selective region at the posterior tip of the calcarine sulcus did not increase in selectivity over time ($P=0.4$ at the peak voxel; Figure 4 bottom panel).

We then looked for non-selective increases in activation to words relative to rest (Figure 5). As expected, we again found the same language areas as before, plus a left ventrolateral occipital cluster just posterior to the lesion (MNI -48 -82 -8, $Z=6.55$). At the peak of this cluster (Figure 5C), the increase of activations relative to rest affected all categories (correlation with session number, all $P_s < 0.02$), and accordingly no category increased in activation relative to the average of all categories (all $P_s > 0.10$).

Psychophysiological interaction (PPI)

The involvement of visual and other regions in reading can be revealed not only through their level of activation, but also through their functional correlation with distant regions, particularly with core language areas. We defined a seed ROI in supramodal language cortex, by creating a 5-mm-radius sphere centered on the peak of the left TPJ cluster (MNI -60 -46 13) as identified above by contrasting words minus the other categories of stimuli. Using PPI analysis, we then identified the

1 regions whose correlation with the TPJ was larger during the perception of words than during the
2 perception of other types of stimuli. When pooling all 9 sessions, we found a significant PPI in the 3
3 previously identified supramodal language areas, and in extensive bilateral occipito-temporal and
4 occipito-parietal regions (Figure 6). Searching for correlates of reading improvement, we then looked
5 for regions whose PPI increased over time. PPI increased in most of the regions which showed a
6 significant pooled PPI (Figure 6).
7
8
9

10
11 In the previous section (Figure 5C), we found a left ventral occipital region (MNI -48 -82 -8) featuring
12 a non-specific increase in activation for all types of stimuli over time. Importantly, PPI revealed that
13 during the perception of words, as compared to other stimuli, the coupling of this occipital region
14 with the language system increased over time, demonstrating category-selectivity in the functional
15 correlation pattern (Figure 6, yellow circle and bottom panel).
16
17
18
19
20

21 We carried out the same PPI analyses with seed ROIs located in the other main word-specific regions
22 (IFS and left occipital cortex). Those analyses yielded essentially the same results as those based on
23 the TPJ region of interest.
24
25
26

27 **Summary**

28 In summary, in this passive viewing experiment, (1) all types of stimuli, except words, yielded strong
29 category-specific activations at the same occipito-temporal locations as in healthy subjects; (2)
30 words, relative to other categories, did not activate the VWFA but only posterior occipital cortex; (3)
31 over time, printed words progressively induced an increasing activation of the supramodal language
32 network, thereby diverging from other categories of visual stimuli; (4) in intact ventral occipital
33 regions posterior to the lesion, activation increased over time for all types of stimuli; (5) PPI analyses
34 showed that, despite its lack of selectivity for words, occipital cortex progressively increased its
35 coupling with the language system during the perception of words, pointing to its role in reading
36 improvement.
37
38
39
40
41
42
43
44
45

46 **Slow reading experiment**

47 The aim of this experiment was to study more specifically the correlates of letter-by-letter reading
48 and its improvement over time. To this aim, we contrasted real words to illegible consonant strings,
49 with checkerboards as a further lower-level control. All stimuli were presented for a long duration
50 (1700 ms), sufficient to read the words.
51
52
53
54
55

56 **Activations pooled over time**

57 The reading network was delineated using three hierarchical contrasts: alphabetical (i.e. words and
58 consonant strings) minus fixation, alphabetical minus checkerboards (masking by alphabetical minus
59
60
61
62
63
64
65

1 fixation), and words minus consonant strings (masking by alphabetical minus checkerboards) (Figure
2 7A). Relative to both fixation and checkerboards, alphabetical stimuli activated the same language
3 areas as in previous experiments, bilateral ventral occipito-temporal cortex (posterior to the lesion in
4 the left hemisphere), plus bilateral intraparietal cortex.
5

6
7 Moreover, many of those areas showed more activation for words relative to strings of consonants, a
8 contrast which is thought to reflect letter-by-letter reading attempts: the bilateral posterior occipital
9 cortex, and the same left-hemispheric language areas as those identified before (TPJ: MNI -57 -46 13,
10 $Z>8$; precentral/IFS: MNI -60 -13 43, $Z>8$; SMA : MNI -6 -1 55, $Z=7.65$; Broca's area: MNI -69 -1 13;
11 $Z=7.71$; MTG: MNI -57 -25 -14; $Z=7.20$) (Figures 7A and S1).
12
13
14
15
16

17 **Evolution of activations over time**

18 Searching for correlates of the reading improvement, we looked for increases over time in the
19 contrast of words minus checkerboards masking inclusively by an increasing difference of words
20 minus fixation (voxelwise $P<0.01$). This showed an increase of activations in the bilateral occipital
21 cortex (left: MNI -42 -91 -8, $Z=6.15$; right: MNI 21 -103 4, $Z=7.41$; Figure 7B). This included left
22 occipital region (MNI -48 -82 -8) identified in the previous experiment as featuring a non-specific
23 increase in activation for all types of stimuli ($P=0.002$ at the peak voxel). Conversely, we also found
24 decreases in activations to words relative to checkerboards in the bilateral intraparietal cortex (left:
25 MNI -36 -49 34, $Z=6.29$; right: MNI 36 -70 43, $Z=5.38$) and the left IFS (MNI -57 -1 34, $Z=6.82$). When
26 analyzing the evolution of the contrast of words minus consonant strings we found a qualitatively
27 similar but weaker pattern, reaching significance only for the right intraparietal activation increase.
28
29
30
31
32
33
34
35
36

37 **Summary**

38 In summary, (1) when presented for a long duration, alphabetical stimuli activated the same overall
39 network as in the Visual Categories experiment, including posterior visual and language-related
40 areas; (2) a large part of this network was more activated by real words than by consonant strings;
41 (3) in parallel with the improvement of word reading performance over time, activations to words
42 increased in bilateral occipital cortex, a possible correlate of improved letter-processing efficiency;
43 (4) activations decreased in bilateral parietal and left frontal regions, a possible correlate of the
44 reduced attention and working memory load required by LBL reading, thanks to improved letter
45 identification.
46
47
48
49
50
51
52
53
54
55

56 **Discussion**

57 We studied a patient with pure alexia over the course of over one year and a half, both assessing the
58 improvement of his reading abilities, and acquiring longitudinal functional imaging data. We will
59
60
61
62
63
64
65

1 discuss in turn the origins of the reading impairment, the mechanisms of the letter-by-letter reading
2 strategy and of its improvement over time, and the variability that exists between individual patients
3 in those compensatory mechanisms.
4

5 **Mechanisms of the reading deficit**

6 **Pure alexia or hemianopic alexia?**

7
8
9 In the latest phases of his reading improvement, JMZ's pattern of reading latencies was similar to
10 what is observed in right hemianopic patients without sparing of foveal vision. Indeed, such
11 hemianopia has a moderate impact on reading, featuring a slight overall slowing down, and the
12 emergence of a word length effect (Cohen et al., 2003b; Leff et al., 2006). This length effect, as
13 measured in patients (Cohen et al., 2003b; Leff et al., 2006) or in healthy subjects with simulated
14 hemianopia (Bao et al., 2015), is in the order of 10-100 ms per letter. This slope of the length effect is
15 much less than what occurs in severe pure alexia, but it is compatible with JMZ's values of 59 ms and
16 65 ms measured during the last two testing sessions. However, there are several reasons to believe
17 that despite this similarity of reading pattern, JMZ's impairment cannot be reduced to hemianopic
18 alexia. First, this alternative diagnosis does not apply to the early phases of the deficit, during which
19 the severity of the deficit and the size of the length effect were not compatible with hemianopic
20 alexia. Second, particularly with protracted word presentation, hemianopic patients are not expected
21 to make reading errors, while JMZ still made 5-10% errors in single word reading during the latest
22 testing sessions. Third, JMZ had the subjective feeling that his visual field returned to normal,
23 although this cannot be taken as firm evidence in the absence of objective visual field follow up.
24 Fourth, hemianopic alexia results from lesions affecting the left medial occipital lobe with a frequent
25 extension to the lingual gyrus (Leff et al., 2006). To the contrary, this area was spared in JMZ, whose
26 lesion affected the ventral temporal lobe, precisely as expected in pure alexia (Cohen et al., 2003b;
27 Leff et al., 2006; Pflugshaupt et al., 2009). Fifth and finally, JMZ showed strong activations to words in
28 his left occipital cortex, while activations were lacking in the VWFA, which is the pattern opposite to
29 what would be expected in hemianopic alexia.
30
31
32
33
34
35
36
37
38
39
40
41
42
43
44
45
46
47

48 **Brain correlates of pure alexia**

49 JMZ's lesion precisely matches group studies of pure alexic patients, in which the critical lesion site
50 associated with pure alexia was assigned to the region lateral to the middle section of the left
51 fusiform gyrus (Cohen et al., 2003b; Pflugshaupt et al., 2009), overlapping with the VWFA as
52 identified by neuroimaging studies in healthy subjects (for reviews see Jobard et al., 2003; Dehaene
53 and Cohen, 2011; Cattinelli et al., 2013; Taylor et al., 2013; Dehaene et al., 2015).
54
55
56
57
58
59
60
61
62
63
64
65

1 JMZ did not experience any impairment in object recognition beyond reading. As in the case reported
2 by Gaillard et al. (2006) this selective impairment was paralleled by the loss of selective fMRI
3 responses to written words in the VWFA, while other ventral temporal category-selective activations
4 were spared (selectivity for words over other categories of objects persisted at the very tip of the left
5 occipital lobe, a finding that will be discussed below).
6
7

8
9 The lesion affected both the cortex subtending orthographic encoding, but also the white matter
10 projecting from low-level visual cortex and to language areas. Indeed, we found a degeneration of
11 white matter in the occipitotemporal region, extending well beyond the lesion, and affecting some of
12 the main tracts involved in reading, i.e. inferior longitudinal and inferior fronto-occipital fasciculi and
13 possibly the posterior segment of the arcuate (Epelbaum et al., 2008; Vandermosten et al., 2012;
14 Bouhali et al., 2014). There was also a progressive decrease in white matter density in the splenium
15 of the corpus callosum. The critical role of this structure in reading is to allow words or word parts
16 displayed in the left visual hemifield to be read. Left hemifield stimuli project to the right geniculate
17 nucleus and thence to the right occipital lobe. Even if some letter identification abilities are present
18 in the right occipitotemporal region (Cohen et al., 2003b; Dehaene et al., 2005; Epelbaum et al.,
19 2008), this information must be conveyed across hemispheres to the VWFA through the callosal
20 splenium, and thence the left-hemispheric reading network. As a consequence, splenial lesions give
21 rise to alexia restricted to the left half of the visual field (Suzuki et al., 1998; Cohen et al., 2000;
22 Molko et al., 2002; Cohen et al., 2003b). In patients with complete right hemianopia, an additional
23 callosal lesions is thus sufficient to yield full-fledged pure alexia (Maeshima et al., 2011). As a further
24 illustration of its role in reading, the splenium undergoes anatomical changes in parallel to the
25 acquisition of literacy (Carreiras et al., 2009). In the case of JMZ, one may speculate that the
26 degeneration of the splenium could contribute to limit the recovery of reading in the left hemifield.
27 In summary, our observations are compatible with JMZ's lesion leading to a degeneracy of the main
28 fiber tracts conveying reading-related visual information to and from the VWFA.
29
30
31
32
33
34
35
36
37
38
39
40
41
42
43
44
45

46 Interestingly, we found a small spot in the left posterior STS/MTG (MNI -57 -63 7) where grey matter
47 density decreased over time. We checked that this region was never activated relative to rest in any
48 of the experiments. One may speculate that the lack of activation and the anatomical degeneration
49 resulted from a diaschisis or deafferentation from the ventral temporal lesion. Indeed, this spot is
50 very close to one of the regions of interest anatomically connected to the VWF system, as studied by
51 Bouhali et al. (2014) (MNI -52 -69 9). This region was shown to be connected through the arcuate
52 fasciculus to the sector of the VWF system centered at MNI -45 -58 -19, a cortical location which is at
53 the core of JMZ's lesion. Functionally, this STS/MTG locus could be a key step in the reading circuit.
54 Accordingly, it is located slightly posterior to the reproducible STS activation focus associated with
55
56
57
58
59
60
61
62
63
64
65

1 the three terms “reading”, “phonological”, and “semantic”, in the Neurosynth meta-analytic
2 database (<http://neurosynth.org/>). This region overlaps with an area activated during reading by real
3 words more than by pseudowords, as shown in a recent meta-analysis (Taylor et al., 2013). This could
4 reflect either semantic processing (Binder et al., 2009), or possibly involvement of the phonological
5 lexicon (Davis and Gaskell, 2009). Thus, although the function of this region cannot be ascertained on
6 the basis of the present evidence, it would be tempting to view it as a step subsequent to the VWFA
7 in the word reading process.
8
9

10 **Mechanisms of letter-by-letter reading**

11 Following the occurrence of his lesion, JMZ rapidly picked up LBL reading, which then improved to
12 some extent over time. However, he did not recover fully functional parallel reading, which is the
13 hallmark of expert adult reading (Aghababian and Nazir, 2000). At a minimum, LBL reading requires
14 letter identification by the visual system, followed by storage of letters in working memory,
15 eventually allowing for access to the lexicon and to phonological encoding. We will now examine the
16 brain mechanisms of those processes and their evolution over time.
17
18

19 **Residual letter identification**

20 The patient’s orthographic encoding did not rely on the letter-selective VWFA proper, which was
21 shown to be anatomically disrupted and impossible to activate. However, the spared left occipital
22 tissue posterior to the lesion probably played a crucial role in residual reading and in reading
23 improvement. Distinct regions were identified on the basis of their activation patterns.
24
25

26 **Left posterior occipital cortex**

27 We identified posterior occipital clusters peaking at MNI -9 -97 -8, overlapping with areas V1 and V2
28 (47% and 41%, respectively) and at MNI -30 -97 -14, overlapping with areas V3v and V4 (58% and
29 39%, respectively). Anatomical overlap was computed with the SPM Anatomy toolbox, based on
30 cytoarchitectonic parcellation (Eickhoff et al., 2005). This region was identified on the basis of its
31 selectivity to words as compared to the other categories of stimuli (faces, houses, tools). There is
32 now ample evidence corroborating the role of occipital cortex in reading expertise. Szwed et al.
33 (2011), identified the same areas by contrasting words minus objects, after subtraction of scrambled
34 images. In another study, occipital cortex showed higher activation to real letters than to
35 comparable non-letter shapes (e.g. rotated letters) and was sensitive to letter frequency, particularly
36 when stimuli were presented along the horizontal visual meridian (Chang et al., 2015). Szwed et al.
37 (2014) further showed that, within retinotopic cortex, areas V1/V2 and V3/V4 play distinct roles:
38 V1/V2 was predominantly involved in alphabetic reading (in French subjects), whereas V3/V4 was
39 involved in Chinese reading in Chinese subjects. In English readers, Richardson et al. (2011) found
40
41
42
43
44
45
46
47
48
49
50
51
52
53
54
55
56
57
58
59
60
61
62
63
64
65

1
2
3
4
5
6
7
8
9
bidirectional functional correlation of occipital cortex to posterior superior temporal regions,
modulated positively by reading. Finally, another source of evidence for occipital involvement in
reading comes from the comparison of literate and illiterate adults : posterior occipital cortex
increases its activation to horizontal relative to vertical checkerboards in direct proportion to literacy
scores (words read per minute), and its activation also increases linearly with literacy when printed
sentences are presented (Dehaene et al., 2010).

10
11
12
13
14
15
16
17
18
19
20
21
22
Although attuned to the perception of letters, this region does not appear to be sensitive to high-
order regularities involving combinations of letters, such as bigram frequency, which emerge only in
more anterior parts of the occipitotemporal reading pipeline, corresponding to the VWFA (Binder et
al., 2006; Vinckier et al., 2007; Thesen et al., 2012). Thus, the loss of the VWFA, together with the
preservation of occipital reading-related activation, may explain why the patient lost the fast parallel
recognition of words while remaining able to quickly identify individual letters in a serial manner.

23
24
25
26
27
28
29
30
31
32
33
Indeed, during slow letter-by-letter reading, occipital cortex showed a stronger activation to real
words than to consonant strings ($t=3.81$ and $t=4.52$ at the peaks of the two clusters; $P<0.001$). This
difference likely resulted from the longer visual processing of real words, which were read letter by
letter, as compared to consonant strings, which the patient rapidly rejected as unreadable. The same
account applies also to the right-hemispheric symmetrical area, which showed the same pattern of
activation as in the left hemisphere (Figure 7).

34
35
36
37
38
39
40
41
42
43
44
45
Importantly, there was no increase of the selectivity for words over time in those posterior occipital
areas, suggesting that the reading improvement could not be explained by changes in their intrinsic
properties. Still, the V3v/V4 region (but not the V1/V2 region) showed an increase over time in its PPI
with language areas ($t=4.31$, $P<0.001$ at the peak voxel), suggesting a better integration in the
reading network. The latter feature was shared with right-hemispheric symmetrical areas (Figure 6),
which were presumably involved in encoding visual stimuli from the intact left visual hemifield.

46 47 48 49 50 51 52 53 54 55 56 57 58 59 60 61 62 63 64 65 The “Occipital Word Form Area”

Somewhat anterior to the V1-V4 areas discussed before, we found a ventral occipital region (MNI -48
-82 -8), where the increase in activation over time concerned equally all categories of visual objects.
This cluster corresponds to lateral and ventral occipital areas hOc4la and hOc4v (55% and 20%,
respectively) (Rottschy et al., 2007; Malikovic et al., 2015). In JMZ this region showed an increased
selectivity for words in its functional coupling with language areas, during the perception of words as
compared to other types of images. In further support for its role in LBL reading improvement, there
was a significant increase over time in the difference of words minus checkerboards, in the slow
reading experiment. This area is likely identical to the previously designated “Occipital Word Form

1 Area” peaking at MNI $y=-80$, as previously identified by contrasting words presented in the right
2 minus in the left hemifield (Cohen et al., 2002), and by using repetition suppression by partially
3 repeated words (Strother et al., 2016). It may also correspond to the “letter-form area” (MNI $y=-78$)
4 identified by Thesen et al. (2012) with fMRI, MEG, and electrocorticography, an area sensitive to the
5 number of letters but not to lexical features of stimuli. Its activation precedes more anterior word-
6 selective activity, and it is presumably responsible for processing individual letters. Rothlein et al.
7 (2014), using fMRI with MVPA analyses, identified at a region sensitive to the visuospatial shape
8 features of letters which however was significant only in the right-hemispheric region symmetrical to
9 the putative “Occipital Word Form Area”.

16 Finally, one may wonder whether the increase in activation of the “Occipital Word Form Area”, which
17 affected all categories of visual objects (Figure 5C), may have resulted from an improvement in the
18 visual field deficit. However this hypothesis seems unlikely for two reasons. First there was at this
19 location a strong increase over time in activation by words as compared to checkerboards (Figure
20 7B), suggesting that activation increase could not be reduced to a non-specific increase in sensitivity
21 to any right-hemifield stimulation. Second, the increase in activation to words was not linear, and
22 occurred mostly during the late phase of the study, i.e. after the sixth testing session (296 days after
23 the stroke) (Figure 5C). This temporal profile does not fit with the changes in the visual field, which
24 actually improved dramatically during the first 6 weeks after the stroke. Although we do not have
25 more recent assessments of JMZ’s perimetry, it has been demonstrated that the improvement of
26 hemianopia occurs within the first 3 months from injury, and that any improvement after 6 months
27 post-injury is implausible (Zhang et al., 2006).

38 In summary, we may conclude that the earlier stages of residual reading in JMZ relied on spared
39 cortex posterior to the lesion and on contralateral right occipital cortex, and that the progressive
40 improvement of reading was not associated with the emergence of new selective areas, but with a
41 non-specific increase of activations around the Occipital Word Form Area, together with an increase
42 of functional correlation between occipital regions and the language network. The existence of such
43 occipital routes for reading is in good agreement with Seghier et al. (2012) and Richardson et al.
44 (2011). In particular, using fMRI and dynamic causal modelling (DCM) in a pure alexic patient, Seghier
45 et al. (2012) showed an increased functional correlation in a pathway linking occipital, superior
46 temporal, and premotor cortex, bypassing the lesioned VWFA. Importantly, however, our work and
47 that of Seghier et al. (2012) suggests that this residual reading route does not allow for the recovery
48 of normal reading abilities, but only a form of fast letter-by-letter reading. This observation helps
49 delineate, by contrast, the specific and seemingly irreplaceable role of the VWFA. It appears that the
50 critical importance of the VWFA does not lie in the identification of individual letters, but in the fast
51
52
53
54
55
56
57
58
59
60
61
62
63
64
65

1 recognition of higher-order letter combinations such as bigrams, complex graphemes, or full
2 morphemes, which in turn allow for a fast access to the lexical and phonological reading routes
3 (Grainger and Ziegler, 2011).
4

5 **The non-visual stages of letter-by-letter reading**

6 In addition to letter identification, efficient letter-by-letter reading involves effortful combination of
7 letters and access to word identity, presumably depending on left frontoparietal areas underlying
8 verbal working memory and language (Cohen et al., 2004a; Henry et al., 2005). All three experiments
9 reported here showed that printed words activated left parietotemporal and frontal language areas.
10 Those activations matched the behavioral evidence that effortful reading indeed allowed JMZ to
11 access verbal representations from sight. When LBL reading was most facilitated, i.e. when real
12 words were presented for a long duration in the slow reading experiment, the language network
13 activated more than during the perception of illegible consonant strings.
14
15
16
17
18
19
20
21

22 The improvement of reading over time arguably resulted from an improved communication of
23 orthographic information to verbal processes. Accordingly, activations of the language areas to
24 rapidly flashed word stimuli increased over time (Figure 5), and so did their functional correlation
25 with visual cortex (Figure 6). In addition to such increases, in the slow reading experiment in which
26 the patient had time to actually read letter by letter, word-related activations decreased over time in
27 the left IFS and bilateral IPS. Those regions have been repeatedly shown to subtend attention and
28 verbal working memory (see e.g. Chen and Desmond, 2005; Cohen et al., 2008; Schulze et al., 2011),
29 processes which are clearly prerequisite to lexical access during LBL reading. The decreased
30 activation of those regions therefore suggests that one correlate of JMZ's reading improvement is a
31 decrease in the need for attention and working memory resources. Surprisingly, however, this
32 pattern of evolution of brain activations may vary across patients. Thus, in the patient reported by
33 Henry et al. (2005), contrary to what prevailed in JMZ, there was a decrease in residual occipital
34 activations, but an increase in the frontoparietal network assigned to verbal working memory.
35 Understanding this variability is a topic for further research.
36
37
38
39
40
41
42
43
44
45
46
47

48 **Diversity of compensation mechanisms**

49 To conclude, one may underline the substantial individual variability in the mechanisms of recovery
50 from pure alexia. Among those factors accounting for such variability are (1) premorbid reading
51 abilities; (2) premorbid lateralization of the visual word form system, which may vary across subjects
52 (Cohen et al., 2002; Pinel and Dehaene, 2009; Van der Haegen et al., 2012); (3) type of script, such as
53 ideographic systems in which the very notion of LBL reading may not be applicable (Butterworth and
54 Yin, 1991; Shan et al., 2010; Chen et al., 2015); (4) topography of lesions, which may affect different
55
56
57
58
59
60
61
62
63
64
65

sectors of the VWF system and therefore have a variable impact on posterior letter processing abilities (Cohen et al., 2003a; Rosazza et al., 2007) as well as effective callosal transfer (Binder and Mohr, 1992; Suzuki et al., 1998; Cohen et al., 2000); (5) the methods of rehabilitation, which may rely to various degrees on LBL or more global deciphering (Woodhead et al., 2013; Starrfelt et al., 2014). Clarifying those factors may eventually help understand the variety of evolution trajectories in alexic patients, and better focus rehabilitation procedures.

1
2
3
4
5
6
7
8
9
10
11
12
13
14
15
16
17
18
19
20
21
22
23
24
25
26
27
28
29
30
31
32
33
34
35
36
37
38
39
40
41
42
43
44
45
46
47
48
49
50
51
52
53
54
55
56
57
58
59
60
61
62
63
64
65

References

- 1
2 Aghababian V, Nazir TA (2000) Developing normal reading skills: aspects of the visual processes
3 underlying word recognition. *J Exp Child Psychol* 76:123-150.
- 4 Ashburner J (2010) VBM Tutorial. In: <http://www.fil.ion.ucl.ac.uk/~john/misc/VBMclass10pdf>.
- 5 Ashburner J, Friston KJ (2000) Voxel-based morphometry--the methods. *Neuroimage* 11:805-821.
- 6 Bao JY, Rubino C, Taylor AJ, Barton JJ (2015) The effects of homonymous hemianopia in experimental
7 studies of alexia. *Neuropsychologia* 70:156-164.
- 8 Binder JR, Mohr JP (1992) The topography of callosal reading pathways. A case-control analysis. *Brain*
9 115:1807-1826.
- 10 Binder JR, Desai RH, Graves WW, Conant LL (2009) Where is the semantic system? A critical review
11 and meta-analysis of 120 functional neuroimaging studies. *Cereb Cortex* 19:2767-2796.
- 12 Binder JR, Medler DA, Westbury CF, Liebenthal E, Buchanan L (2006) Tuning of the human left
13 fusiform gyrus to sublexical orthographic structure. *Neuroimage* 33:739-748.
- 14 Bouhali F, Thiebaut de Schotten M, Pinel P, Poupon C, Mangin JF, Dehaene S, Cohen L (2014)
15 Anatomical connections of the visual word form area. *The Journal of neuroscience : the*
16 *official journal of the Society for Neuroscience* 34:15402-15414.
- 17 Butterworth B, Yin WG (1991) The universality of two routines for reading: evidence from Chinese
18 dyslexia. *Proceedings Biological sciences / The Royal Society* 246:91-95.
- 19 Carreiras M, Seghier ML, Baquero S, Estevez A, Lozano A, Devlin JT, Price CJ (2009) An anatomical
20 signature for literacy. *Nature* 461:983-986.
- 21 Cattinelli I, Borghese NA, Gallucci M, Paulesu E (2013) Reading the reading brain: A new meta-
22 analysis of functional imaging data on reading. *Journal of Neurolinguistics* 26:214-238.
- 23 Chang CH, Pallier C, Wu DH, Nakamura K, Jobert A, Kuo WJ, Dehaene S (2015) Adaptation of the
24 human visual system to the statistics of letters and line configurations. *Neuroimage* 120:428-
25 440.
- 26 Chen SH, Desmond JE (2005) Cerebrocerebellar networks during articulatory rehearsal and verbal
27 working memory tasks. *Neuroimage* 24:332-338.
- 28 Chen Z, Shao H, Xu M, Peng G, Liu P, Liu X, Shan C, Weng X, Luo B (2015) Is radical-by-radical reading
29 strategy effective for Chinese pure alexia? A case study. *Neuropsychology* 29:402-408.
- 30 Cohen L, Dehaene S, Vinckier F, Jobert A, Montavont A (2008) Reading normal and degraded words:
31 contribution of the dorsal and ventral visual pathways. *Neuroimage* 40:353-366.
- 32 Cohen L, Lehericy S, Chochon F, Lemer C, Rivaud S, Dehaene S (2002) Language-specific tuning of
33 visual cortex? Functional properties of the Visual Word Form Area. *Brain* 125:1054-1069.
- 34 Cohen L, Dehaene S, Naccache L, Lehericy S, Dehaene-Lambertz G, Henaff MA, Michel F (2000) The
35 visual word form area: spatial and temporal characterization of an initial stage of reading in
36 normal subjects and posterior split-brain patients. *Brain* 123:291-307.
- 37 Cohen L, Henry C, Dehaene S, Martinaud O, Lehericy S, Lemer C, Ferrieux S (2004a) The
38 pathophysiology of letter-by-letter reading. *Neuropsychologia* 42:1768-1780.
- 39 Cohen L, Martinaud O, Lemer C, Lehericy S, Samson Y, Obadia M, Slachevsky A, Dehaene S (2003a)
40 Visual word recognition in the left and right hemispheres: anatomical and functional
41 correlates of peripheral alexias. *Cereb Cortex* 13:1313-1333.
- 42 Cohen L, Martinaud O, Lemer C, Lehericy S, Samson Y, Obadia M, Slachevsky A, Dehaene S (2003b)
43 Visual Word Recognition in the Left and Right Hemispheres: Anatomical and Functional
44 Correlates of Peripheral Alexias. *Cereb Cortex* 13:1313-1333.
- 45 Cohen L, Lehericy S, Henry C, Bourgeois M, Larroque C, Sainte-Rose C, Dehaene S, Hertz-Pannier L
46 (2004b) Learning to read without a left occipital lobe: A single case of right-hemispheric shift
47 of the Visual Word Form Area. *Ann Neurol* 56:890-894.
- 48 Cumming TB, Patterson K, Verfaellie M, Graham KS (2006) One bird with two stones: Abnormal word
49 length effects in pure alexia and semantic dementia. *Cogn Neuropsychol* 23:1130-1161.
- 50
51
52
53
54
55
56
57
58
59
60
61
62
63
64
65

- 1 Davis MH, Gaskell MG (2009) A complementary systems account of word learning: neural and
2 behavioural evidence. *Philosophical transactions of the Royal Society of London Series B,*
3 *Biological sciences* 364:3773-3800.
- 4 Dehaene S, Cohen L (2011) The unique role of the visual word form area in reading. *Trends Cogn Sci*
5 15:254-262.
- 6 Dehaene S, Cohen L, Sigman M, Vinckier F (2005) The neural code for written words: a proposal.
7 *Trends Cogn Sci* 9:335-341.
- 8 Dehaene S, Cohen L, Morais J, Kolinsky R (2015) Illiterate to literate: behavioural and cerebral
9 changes induced by reading acquisition. *Nature reviews Neuroscience.*
- 10 Dehaene S, Pegado F, Braga LW, Ventura P, Nunes Filho G, Jobert A, Dehaene-Lambertz G, Kolinsky R,
11 Morais J, Cohen L (2010) How learning to read changes the cortical networks for vision and
12 language. *Science* 330:1359-1364.
- 13 Dejerine J (1892) Contribution à l'étude anatomo-pathologique et clinique des différentes variétés de
14 cécité verbale. *Mem Soc Biol* 4:61-90.
- 15 Eickhoff SB, Stephan KE, Mohlberg H, Grefkes C, Fink GR, Amunts K, Zilles K (2005) A new SPM
16 toolbox for combining probabilistic cytoarchitectonic maps and functional imaging data.
17 *Neuroimage* 25:1325-1335.
- 18 Epelbaum S, Pinel P, Gaillard R, Delmaire C, Perrin M, Dupont S, Dehaene S, Cohen L (2008) Pure
19 alexia as a disconnection syndrome: new diffusion imaging evidence for an old concept.
20 *Cortex* 44:962-974.
- 21 Francis WN, Kucera H (1982) *Frequency Analysis of English Usage: Lexicon and Grammar.* Boston:
22 Houghton Mifflin Company.
- 23 Friston KJ, Buechel C, Fink GR, Morris J, Rolls E, Dolan RJ (1997) Psychophysiological and modulatory
24 interactions in neuroimaging. *Neuroimage* 6:218-229.
- 25 Gaillard R, Naccache L, Pinel P, Clemenceau S, Volle E, Hasboun D, Dupont S, Baulac M, Dehaene S,
26 Adam C, Cohen L (2006) Direct intracranial, fMRI and lesion evidence for the causal role of
27 left inferotemporal cortex in reading. *Neuron* 50:191-204.
- 28 Grainger J, Ziegler JC (2011) A dual-route approach to orthographic processing. *Front Psychol* 2:54.
- 29 Henry C, Gaillard R, Volle E, Chiras J, Ferrieux S, Dehaene S, Cohen L (2005) Brain activations during
30 letter-by-letter reading: A follow-up study. *Neuropsychologia*:1983-1989.
- 31 Hudson PTW, Bergman MW (1985) Lexical knowledge in word recognition: Word length and word
32 frequency in naming and lexical decision tasks. *J Mem Lang* 24:46-58.
- 33 Ingles JL, Eskes GA (2008) A comparison of letter and digit processing in letter-by-letter reading.
34 *Journal of the International Neuropsychological Society* 14:164-173.
- 35 Jobard G, Crivello F, Tzourio-Mazoyer N (2003) Evaluation of the dual route theory of reading: a
36 metaanalysis of 35 neuroimaging studies. *Neuroimage* 20:693-712.
- 37 Leff AP, Spitsyna G, Plant GT, Wise RJ (2006) Structural anatomy of pure and hemianopic alexia. *J*
38 *Neurol Neurosurg Psychiatry* 77:1004-1007.
- 39 Maeshima S, Osawa A, Sujino K, Fukuoka T, Deguchi I, Tanahashi N (2011) Pure alexia caused by
40 separate lesions of the splenium and optic radiation. *J Neurol* 258:223-226.
- 41 Malach R, Levy I, Hasson U (2002) The topography of high-order human object areas. *Trends Cogn Sci*
42 6:176-184.
- 43 Malikovic A, Amunts K, Schleicher A, Mohlberg H, Kujovic M, Palomero-Gallagher N, Eickhoff SB, Zilles
44 K (2015) Cytoarchitecture of the human lateral occipital cortex: mapping of two extrastriate
45 areas hOc4la and hOc4lp. *Brain Struct Funct.*
- 46 Molko N, Cohen L, Mangin JF, Chochon F, Lehéricy S, Le Bihan D, Dehaene S (2002) Visualizing the
47 neural bases of a disconnection syndrome with diffusion tensor imaging. *J Cogn Neurosci*
48 14:629-636.
- 49 O'Regan JK, Jacobs AM (1992) Optimal viewing position effect in word recognition: A challenge to
50 current theory. *Journal of Experimental Psychology: Human Perception and Performance*
51 18:185-197.

- 1 Pflugshaupt T, Gutbrod K, Wurtz P, von Wartburg R, Nyffeler T, de Haan B, Karnath HO, Mueri RM
2 (2009) About the role of visual field defects in pure alexia. *Brain* 132:1907-1917.
- 3 Pinel P, Dehaene S (2009) Beyond Hemispheric Dominance: Brain Regions Underlying the Joint
4 Lateralization of Language and Arithmetic to the Left Hemisphere. *J Cogn Neurosci*.
- 5 Pinel P, Thirion B, Meriaux S, Jobert A, Serres J, Le Bihan D, Poline JB, Dehaene S (2007) Fast
6 reproducible identification and large-scale databasing of individual functional cognitive
7 networks. *BMC Neurosci* 8:91-109.
- 8 Richardson FM, Seghier ML, Leff AP, Thomas MS, Price CJ (2011) Multiple routes from occipital to
9 temporal cortices during reading. *The Journal of neuroscience : the official journal of the*
10 *Society for Neuroscience* 31:8239-8247.
- 11 Rosazza C, Appollonio I, Isella V, Shallice T (2007) Qualitatively different forms of pure alexia. *Cogn*
12 *Neuropsychol* 24:393-418.
- 13 Rothlein D, Rapp B (2014) The similarity structure of distributed neural responses reveals the
14 multiple representations of letters. *Neuroimage* 89:331-344.
- 15 Rottschy C, Eickhoff SB, Schleicher A, Mohlberg H, Kujovic M, Zilles K, Amunts K (2007) Ventral visual
16 cortex in humans: cytoarchitectonic mapping of two extrastriate areas. *Hum Brain Mapp*
17 28:1045-1059.
- 18 Schulze K, Mueller K, Koelsch S (2011) Neural correlates of strategy use during auditory working
19 memory in musicians and non-musicians. *The European journal of neuroscience* 33:189-196.
- 20 Seghier ML, Neufeld NH, Zeidman P, Leff AP, Mechelli A, Nagendran A, Ridloch JM, Humphreys GW,
21 Price CJ (2012) Reading without the left ventral occipito-temporal cortex. *Neuropsychologia*.
- 22 Shan C, Zhu R, Xu M, Luo B, Weng X (2010) Implicit reading in Chinese pure alexia. *Brain Lang*
23 114:147-156.
- 24 Starrfelt R, Shallice T (2014) What's in a name? The characterization of pure alexia. *Cogn*
25 *Neuropsychol* 31:367-377.
- 26 Starrfelt R, Olafsdottir RR, Arendt IM (2014) Rehabilitation of pure alexia: A review.
27 *Neuropsychological Rehabilitation* 23:755-779.
- 28 Strother L, Coros AM, Vilis T (2016) Visual Cortical Representation of Whole Words and Hemifield-
29 split Word Parts. *J Cogn Neurosci* 28:252-260.
- 30 Suzuki K, Yamadori A, Endo K, Fujii T, Ezura M, Takahashi A (1998) Dissociation of letter and picture
31 naming resulting from callosal disconnection. *Neurology* 51:1390-1394.
- 32 Szwed M, Qiao E, Jobert A, Dehaene S, Cohen L (2014) Effects of literacy in early visual and
33 occipitotemporal areas of Chinese and French readers. *J Cogn Neurosci* 26:459-475.
- 34 Szwed M, Dehaene S, Kleinschmidt A, Eger E, Valabregue R, Amadon A, Cohen L (2011) Specialization
35 for written words over objects in the visual cortex. *Neuroimage* 56:330-344.
- 36 Taylor JS, Rastle K, Davis MH (2013) Can cognitive models explain brain activation during word and
37 pseudoword reading? A meta-analysis of 36 neuroimaging studies. *Psychological bulletin*
38 139:766-791.
- 39 Thesen T, McDonald CR, Carlson C, Doyle W, Cash S, Sherfey J, Felsevalyi O, Girard H, Barr W,
40 Devinsky O, Kuzniecky R, Halgren E (2012) Sequential then interactive processing of letters
41 and words in the left fusiform gyrus. *Nat Commun* 3:1284.
- 42 Thiebaut de Schotten M, Ffytche DH, Bizzi A, Dell'Acqua F, Allin M, Walshe M, Murray R, Williams SC,
43 Murphy DG, Catani M (2011) Atlasing location, asymmetry and inter-subject variability of
44 white matter tracts in the human brain with MR diffusion tractography. *Neuroimage* 54:49-
45 59.
- 46 Van der Haegen L, Cai Q, Brysbaert M (2012) Colateralization of Broca's area and the visual word
47 form area in left-handers: fMRI evidence. *Brain Lang* 122:171-178.
- 48 Vandermosten M, Boets B, Wouters J, Ghesquiere P (2012) A qualitative and quantitative review of
49 diffusion tensor imaging studies in reading and dyslexia. *Neurosci Biobehav Rev* 36:1532-
50 1552.

- 1 Vinckier F, Dehaene S, Jobert A, Dubus JP, Sigman M, Cohen L (2007) Hierarchical coding of letter
2 strings in the ventral stream: dissecting the inner organization of the visual word-form
3 system. *Neuron* 55:143-156.
- 4 Weekes BS (1997) Differential effects of number of letters on word and nonword naming latency.
5 *Quarterly Journal of Experimental Psychology* 50A:439-456.
- 6 Woodhead ZV, Penny W, Barnes GR, Crewes H, Wise RJ, Price CJ, Leff AP (2013) Reading therapy
7 strengthens top-down connectivity in patients with pure alexia. *Brain : a journal of neurology*
8 136:2579-2591.
- 9 Zhang X, Kedar S, Lynn MJ, Newman NJ, Biousse V (2006) Natural history of homonymous
10 hemianopia. *Neurology* 66:901-905.
- 11 Ziegler JC, Perry C, Jacobs AM, Braun M (2001) Identical words are read differently in different
12 languages. *Psychological Science* 12:379-384.
- 13
14
15
16
17
18
19
20
21
22
23
24
25
26
27
28
29
30
31
32
33
34
35
36
37
38
39
40
41
42
43
44
45
46
47
48
49
50
51
52
53
54
55
56
57
58
59
60
61
62
63
64
65

Acknowledgements

1 The research leading to these results has received funding from the program “Investissements
2 d’avenir” ANR-10-IAIHU-06. We thank E. Volle and M. Thiebaut de Schotten for the help with
3 diffusion weighted imaging acquisition and analyses. Additional support for this research comes from
4 the “Agence Nationale de la Recherche” (grants ANR-09-RPDOC-004-01 and ANR-13-JSV4-0001-01).
5 The authors want to thank Ari Lingewaran for providing technical support for the acquisition of MRI
6 data.
7
8
9

10
11
12
13
14
15
16
17
18
19
20
21
22
23
24
25
26
27
28
29
30
31
32
33
34
35
36
37
38
39
40
41
42
43
44
45
46
47
48
49
50
51
52
53
54
55
56
57
58
59
60
61
62
63
64
65

Figure legends

Figure 1

Patient characteristics. (A) Initially the patient had complete right homonymous hemianopia (automated perimetry), which receded partially over the first weeks after the stroke. (B) MRI showed a small infarct (magenta) in the territory of the left posterior cerebral artery, shown here on a 3D translucent image of the patient's brain. (C) Lesion topography from axial and coronal T1-weighted images. The lesion was a narrow slit mostly confined to the occipito-temporal white matter (yellow arrow), encompassing the average coordinates of the peak activation of the VWFA (red circle; MNI -43 -54 -12; Cohen et al., 2002).

Figure 2

Evolution of reading performance over a period of 19 months. The patient participated in (A) 17 sessions of behavioral assessment of text reading; and (B) 10 sessions of behavioral assessment of word reading. He participated in 9 sessions of fMRI of reading and object perception (red crosses). For both text and words, reading speed improved steadily but with a decreasing pace. As an index of increasingly effective letter-by-letter reading, the word length effect decreased over time (green curve). Curves were well fit with decreasing power laws (dotted lines and R^2 values).

Figure 3

Voxel-based morphometry (VBM) of white matter abnormalities. (A) There was a decrease over time in white matter density (blue) in a set of left posterior regions and in the splenium of the corpus callosum. There was an increase in white matter density (red) in the posterior left STS. (B) There was a reduction in fractional anisotropy in the patient relative to controls in similar regions. (C) the region of reduced anisotropy overlapped with the inferior longitudinal (green) and inferior fronto-occipital (blue) fasciculi, and possibly with the posterior segment of the arcuate fasciculus (magenta).

Figure 4

Mosaic of selectivity to different categories of visual objects. Category-specific activations pooled over all testing sessions. Each category of stimuli was contrasted to the other three. This showed a typical category-specific mosaic of occipito-temporal activations to faces (blue), tools (magenta), and houses (green), yet with a missing response to word at the normal site of the visual word form area (VWFA). Words-specific activations in the visual cortex were restricted to the posterior tip of the left calcarine region (yellow circle), where selectivity did not change over time.

Figure 5

Evolution of selectivity to different categories of visual objects. (A) Increase over time of activations to words relative to rest (blue), and relative to other categories (red). The bottom plots show the evolution of activations relative to rest for the 4 categories of stimuli, at peak voxels indicated by yellow circles (same color code as in Figure 4). (B) Left-hemispheric language areas showed a selective increase of activations by words. (C) A left occipital region showed a non-specific increase.

Figure 6

Evolution of functional correlations in the experiment with categories of visual objects. A psychophysiological interaction (PPI) analysis was used to search for regions whose coupling with the temporo-parietal junction, and other language areas, was higher during the perception of words than of other types of images. A network including, in addition to language areas, ventral and dorsal visual cortex showed both significant PPI when pooling all sessions (blue), and a significant increase in PPI over time (red). This increase in PPI concerned notably the bilateral occipital cortex, as illustrated by the plot of PPI evolution at the left occipital peak (yellow circle and bottom panel).

Figure 7

Activations during slow reading and their evolution with time. (A) Activations pooled over all sessions, showing hierarchically embedded activations for alphabetic stimuli minus fixation (red), minus checkerboards (blue), and for words minus consonants strings (green). (B) Activation for words minus checkerboards increased over time in the bilateral occipital cortex (red), and decreased in the left frontal and bilateral parietal cortex (blue).

Figure S1

VBM analysis of grey matter abnormalities, showing an increase over time in the density of grey matter (red) in left posterior regions contiguous to the regions of decreased white matter density (see Figure 3A). Conversely there was a decrease in GM (blue) in the posterior left STS.

Figure S2

(A) Activations during the localizer for spoken and written language perception. There was a strong overall left lateralization of supramodal language processing, both in the temporal and frontal lobes (blue). There were expected bilateral activations in modality-specific regions triggered by auditory (green) or visual (red) language. Left ventral activations to visual sentences were restricted to the occipital cortex posterior to the lesion, with no activation of the VWFA. (B) Core language areas, as identified in the 3 experiments using the contrasts reported in the text. In the language localizer: conjunction of audio and visual sentences (blue). In the categories experiment: conjunction of words minus all others (red). In the slow reading experiment: words minus consonants (green).

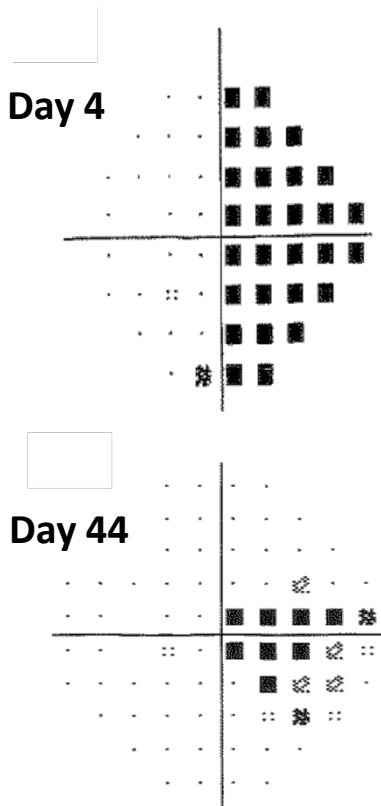
Tables

Table 1

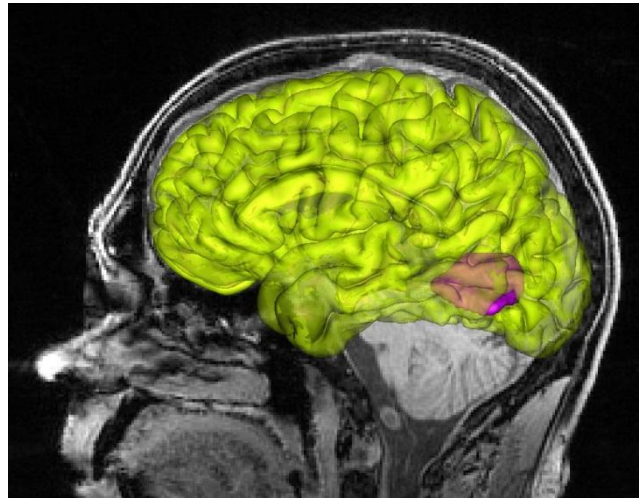
Evolution of single word reading performance

Evolution of single word reading performance										
Time after stroke (days)	116	158	211	260	284	296	326	396	465	575
Correct reading onset latency (ms)										
Word length (letters)										
3	1282	1144	1100	1045	1061	920	846	603	577	926
4	1579	1506	1286	1038	1089	1049	795	773	735	818
5	1790	1929	1423	1235	1163	1106	871	738	901	736
6	2127	1965	1381	1406	1198	1094	791	837	841	961
7	2040	1825	1556	1835	1260	1374	974	1084	843	1254
8	2515	2209	1678	1615	1216	1734	1077	1304	936	1074
Mean	1889	1763	1404	1362	1165	1213	892	890	805	962
Reading errors (%)										
Word length (letters)										
3	10%	10%	11%	5%	10%	5%	5%	10%	5%	10%
4	10%	11%	0%	10%	0%	10%	15%	5%	5%	10%
5	15%	25%	5%	5%	5%	20%	5%	5%	10%	15%
6	5%	15%	10%	0%	5%	10%	15%	5%	15%	0%
7	25%	10%	5%	15%	5%	5%	10%	10%	5%	0%
8	25%	10%	5%	0%	0%	10%	5%	5%	10%	0%
Mean	15%	13%	6%	6%	4%	10%	9%	7%	8%	6%
Word length effect										
slope (ms/letter)	225	180	104	155	38	144	46	130	59	65
intercept (ms)	649	771	830	512	957	422	639	177	482	605

(A) Visual field defect



(B) Outline of the lesion



(C) Left occipito-temporal brain lesion

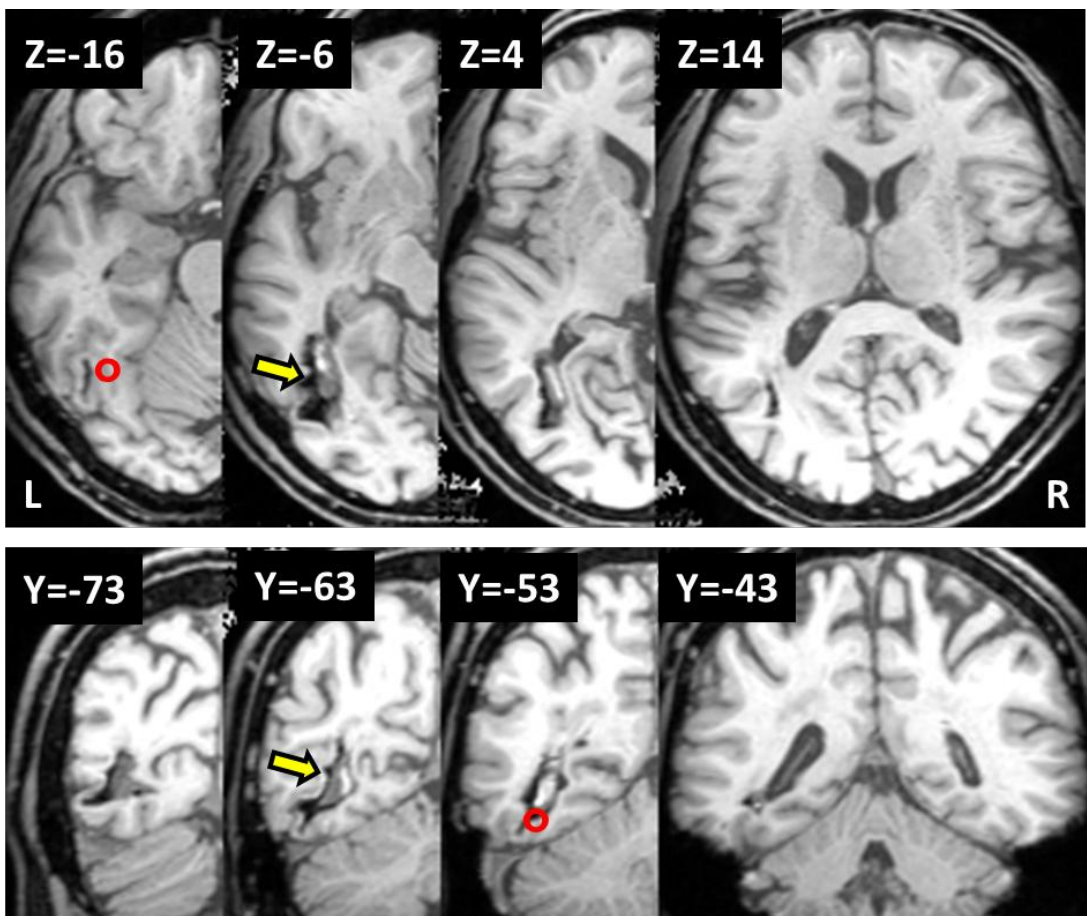
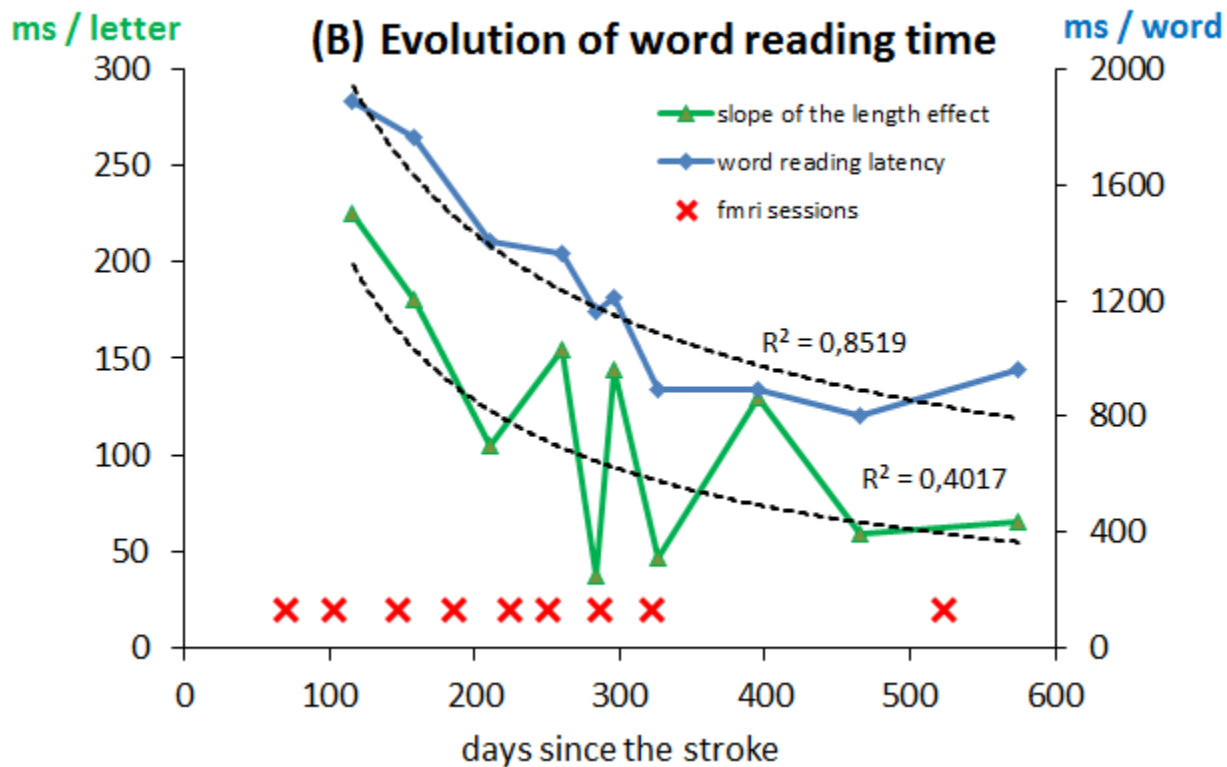
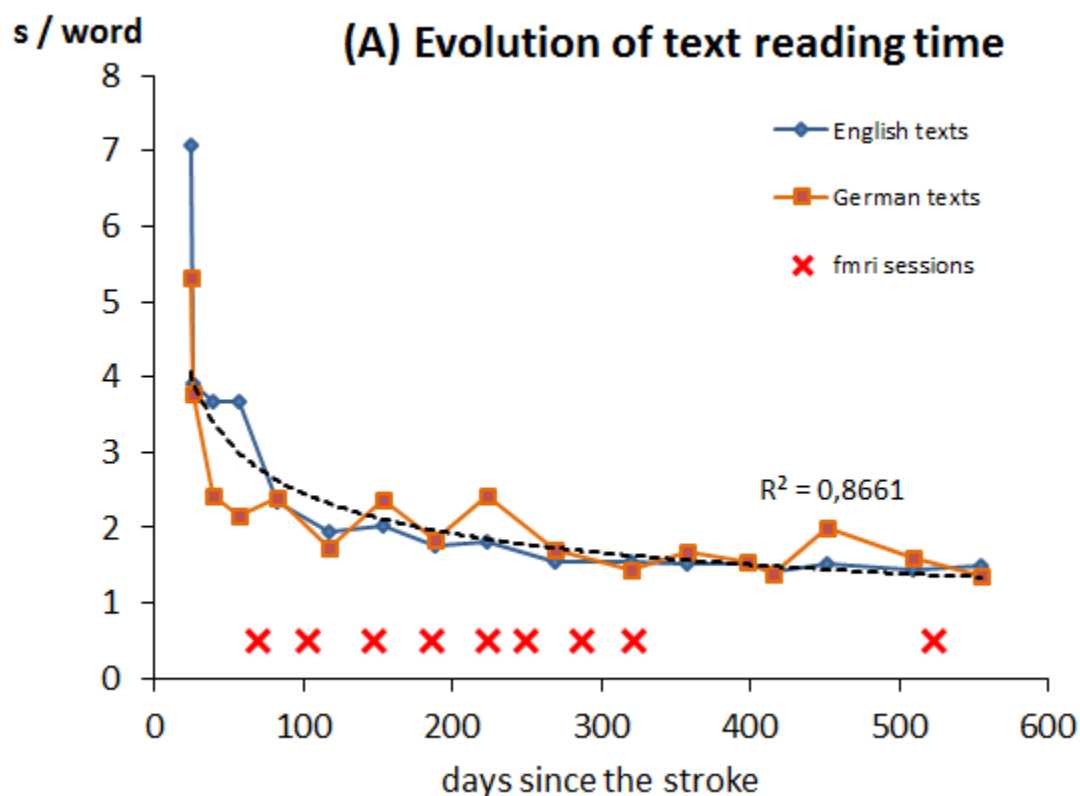
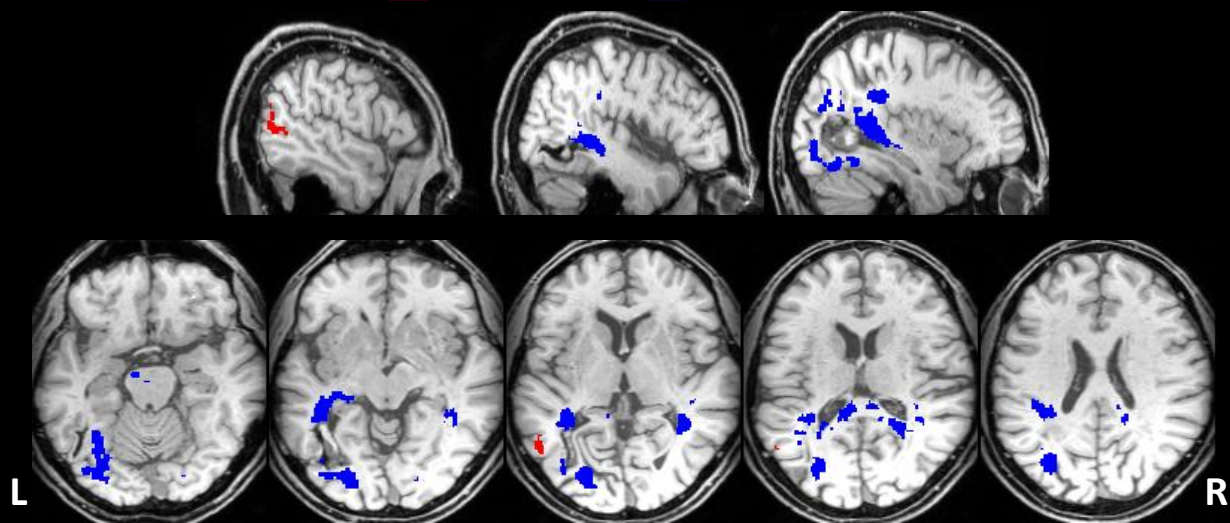


Figure 2



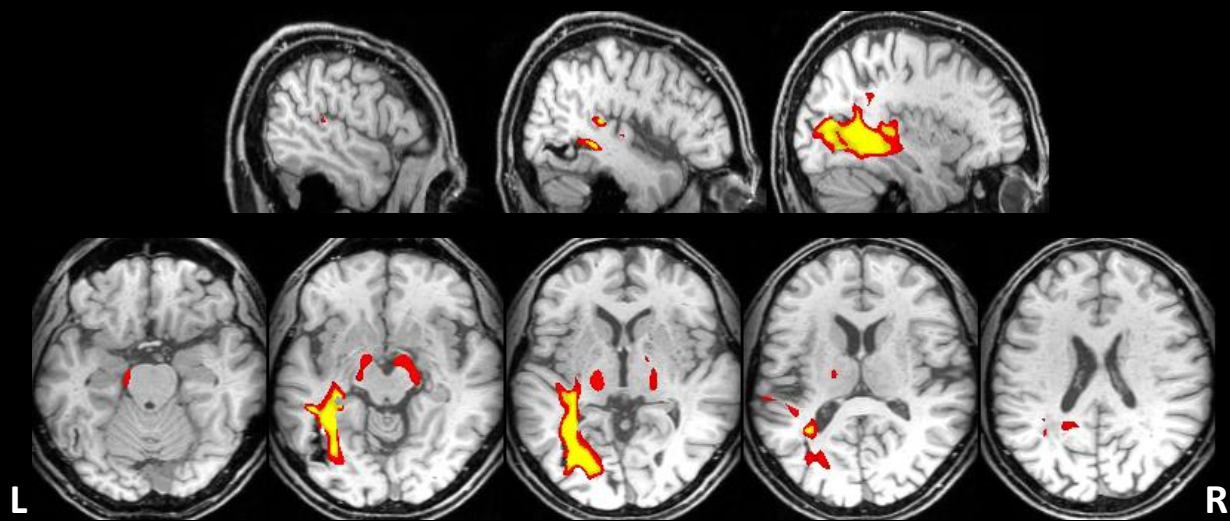
(A) Evolution over time of white matter density

Red Increase Blue Decrease



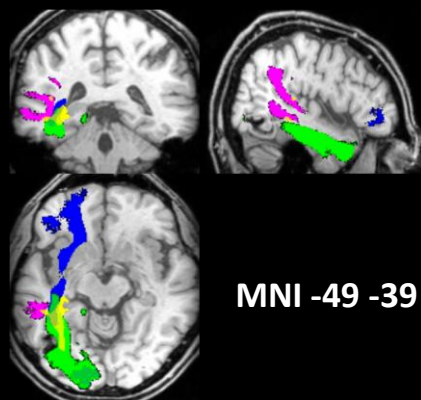
(B) FA reduction in the patient relative to controls

Red $P < 0.01$ Yellow $P < 0.001$



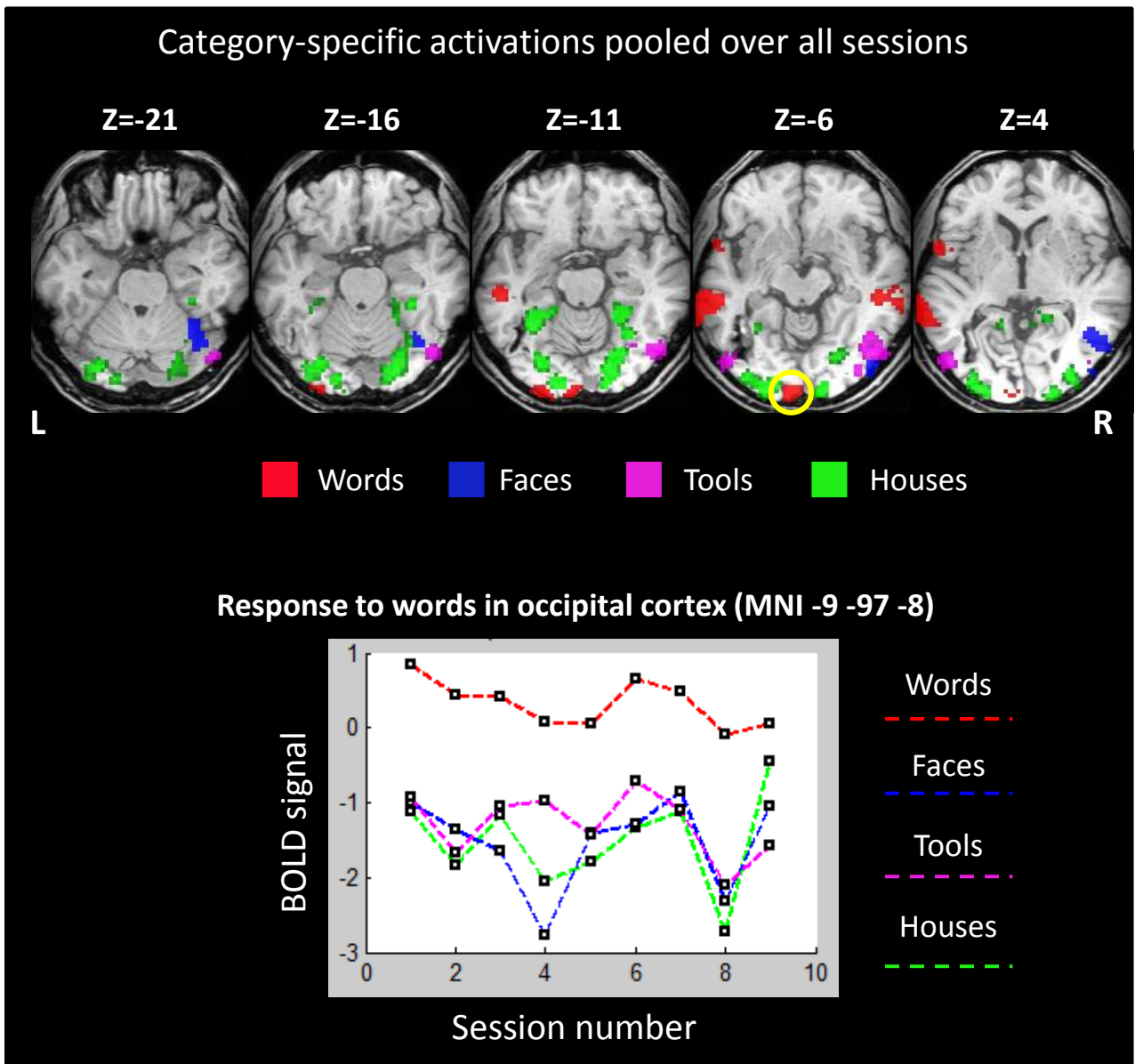
(C) Overlap of FA reduction ($P < 0.001$) with the main white matter fasciculi

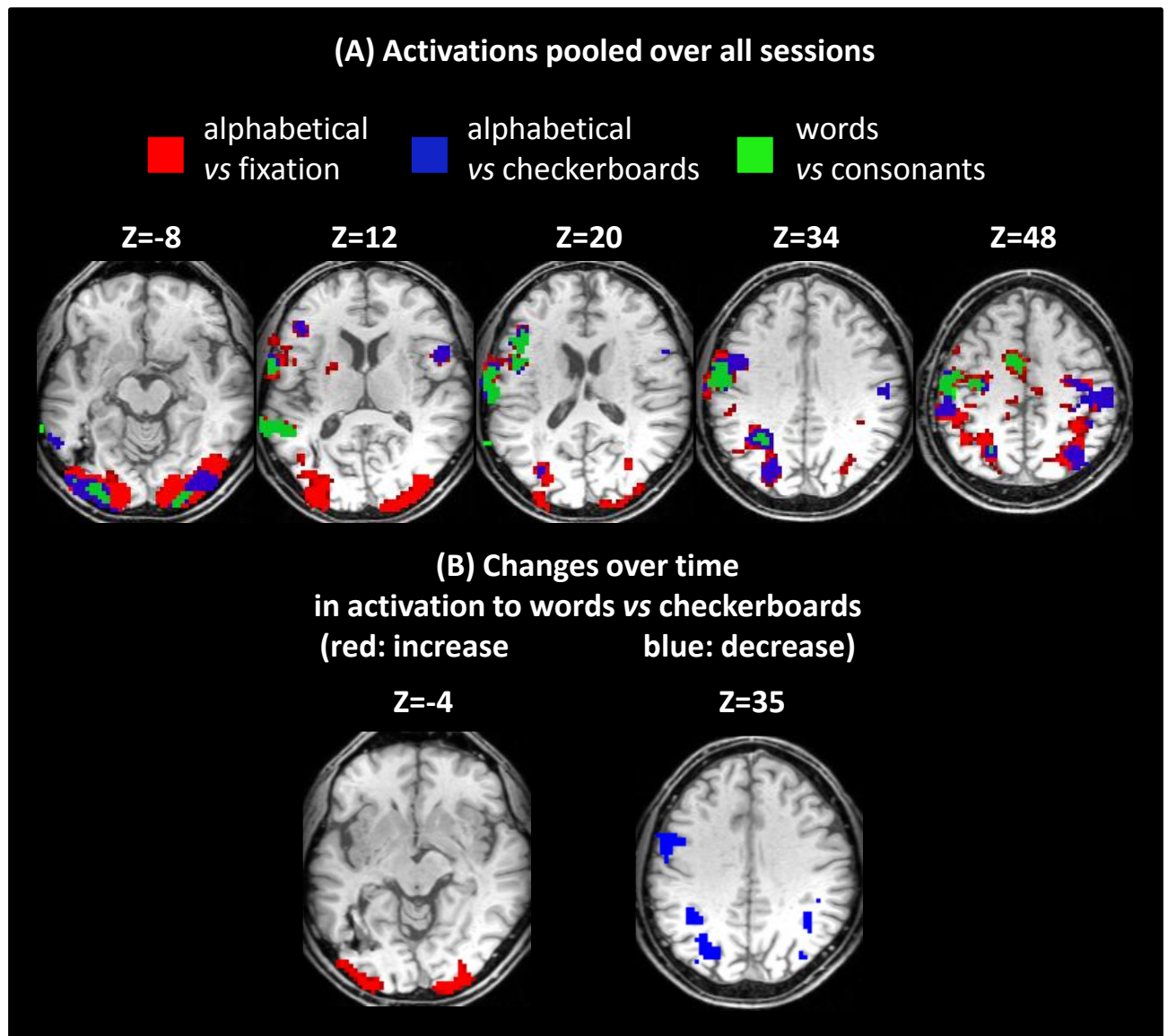
Magenta Posterior AF
 Green ILF
 Blue IFOF



MNI -49 -39 -6

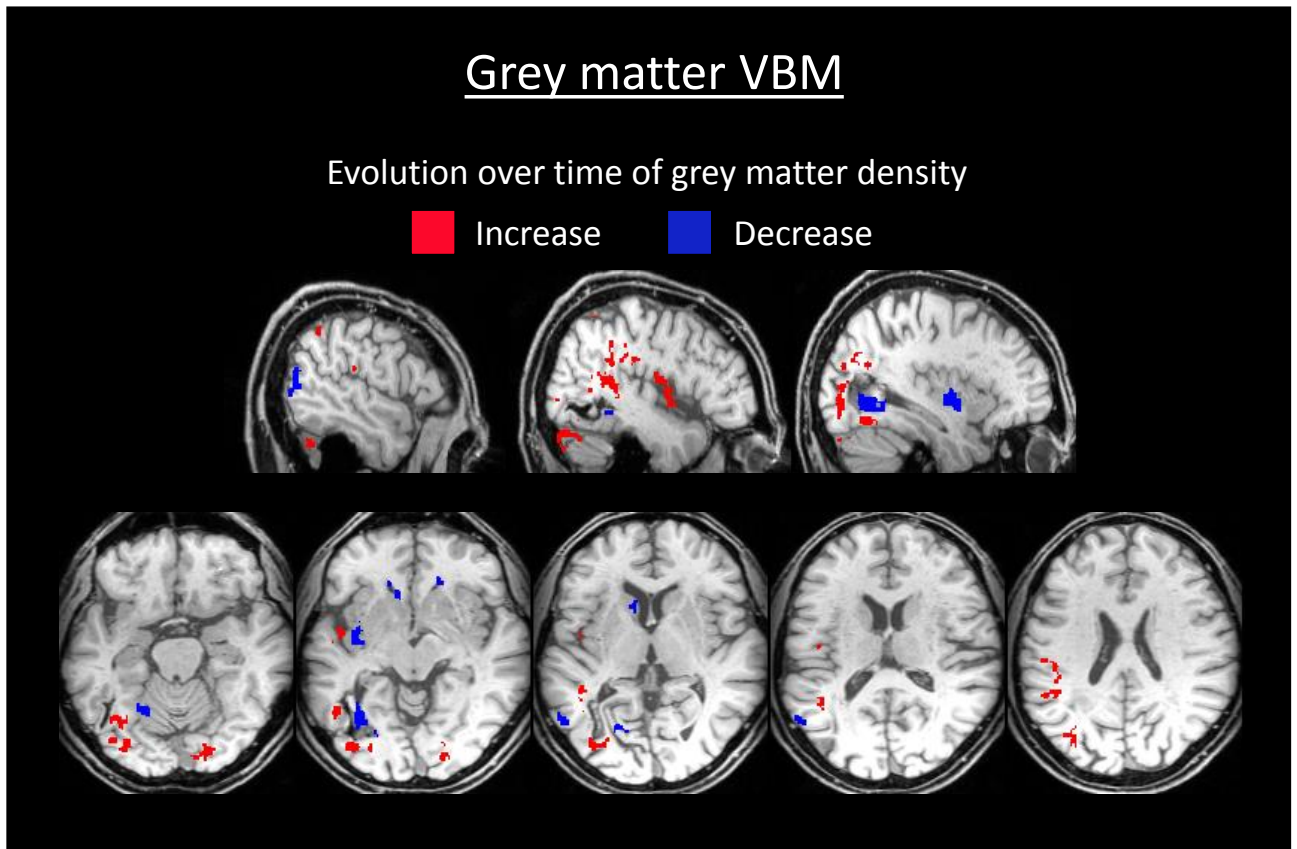
Figure 4





Supplementary Material

[Click here to download Supplementary Material: JMZ_supplementary.pdf](#)



VBM analysis of grey matter abnormalities, showing an increase over time in the density of grey matter (red) in left posterior regions contiguous to the regions of decreased white matter density (see Figure 3A). Conversely there was a decrease in GM (blue) in the posterior left STS.

