

Apraxia of Eyelid Opening Secondary to Right Hemisphere Infarction

James C. Johnston, MD,* Daniel M. Rosenbaum, MD,†
Carmela M. Picone, MD, and James C. Grotta, MD

A variety of eyelid movement abnormalities have been attributed to lesions of the central nervous system. Apraxia of lid movements, and especially of lid opening, has received the least attention. We present 2 cases of lid opening apraxia and propose that this abnormality may be due to right hemisphere dysfunction.

Johnston JC, Rosenbaum DM, Picone CM,
Grotta JC. Apraxia of eyelid opening secondary
to right hemisphere infarction.
Ann Neurol 1989;25:622-624

Over the last century, a variety of eyelid movement abnormalities have been attributed to lesions of the central nervous system, including ptosis, motor imper-sistence, and apraxia of lid movements. The latter disorder has received the least attention. Apraxia of lid closure was first described by Lewandowsky [1] in 1907, but only a few cases have been reported since [2, 3]. We present 2 more cases, both with right hemisphere infarction. (Since this manuscript was submitted, we have identified a third case, which is not discussed here.)

The following criteria for lid opening apraxia, modified from Lepore and Duvoisin [4], were present in both of our patients: inability to initiate lid opening voluntarily, despite frontalis muscle contraction; normal spontaneous lid elevation; no evidence of concurrent orbicularis oculi muscle contraction; no ocular motor nerve dysfunction; no ocular sympathetic dysfunction; and no ocular myopathy.

Case Reports

Patient 1

A 68-year-old right-handed woman previously in good health had acute onset of left-sided weakness. She was alert and oriented with fluent but dysarthric speech, left-sided neglect, and visual-spatial dysfunction. She had no evidence of

orofacial or limb apraxia. She had central left facial weakness, a left hemiparesis, and left hemisensory deficit. The left plantar response was extensor, the right flexor.

The pupils were 3 mm, symmetrical, and equally reactive. Extraocular movements were full, although she exhibited a right conjugate gaze preference. She rarely opened her eyes spontaneously, even when engaged in conversation; however, when her eyes were open, there was no evidence of ptosis. Closure of the eye was normal. Reflex lid opening was intact. The patient was unable to open her eyes on command, despite frontalis muscle contraction. She was aware of this deficit, replying that she did not know why she was unable to perform the task. Occasionally she used her non-paretic hand to elevate the lids.

The patient improved over the next few days. By the fourth hospital day, she was able to open her lids on command without hesitation. Also during this time, neglect and visual-spatial dysfunction resolved. The motor and sensory deficits persisted. Serial computed tomography of the brain revealed an infarction in the right middle cerebral artery distribution (Fig 1).

Patient 2

An 81-year-old right-handed man with a history of atrial fibrillation but no prior neurological events experienced the acute onset of left-sided paralysis. He was alert and oriented, with fluent but dysarthric speech, left-sided neglect, visual-spatial dysfunction, and a left homonymous hemianopsia. He had no evidence of orofacial or limb apraxia. He had central left facial weakness, left hemiplegia, and left hemisensory deficit. The left plantar response was extensor, the right flexor.

The pupils were 4 mm, symmetrical, and equally reactive. Extraocular movements were full, although he exhibited a right conjugate gaze preference. Although the patient kept his eyes closed most of the time, he at times opened them spontaneously. There was no evidence of ptosis. Closure of the eyes was normal. Reflex lid opening was intact. He was unable to open his eyes on command, despite frontalis muscle contraction. He was aware of this difficulty, replying that he did not know why he was unable to perform this task.

The patient slowly improved, but it was not until the end of 1 month that he was able to open his eyes on command. During this time, parietal lobe dysfunction also resolved, but motor and sensory deficits persisted. Serial computed tomography of the brain revealed an infarction in the right middle cerebral artery distribution with hemorrhagic transformation (Fig 2).

Discussion

Both of our patients exhibited lid opening apraxia as defined by the above-mentioned criteria. They had difficulty initiating lid opening, even when alert and interacting with other people. This eventually resolved, as did other deficits of cortical function referable to the right parietal lobe.

The Table summarizes the reported cases of lid opening apraxia. Extrapyramidal disease was responsible for cases reported by Schilder [5], Goldstein and Cogan [6], Dehaene [7], and Lepore and Duvoisin [4].

From the Department of Neurology, University of Texas School of Medicine, Houston, TX.

Received May 20, 1988, and in revised form Nov 7. Accepted for publication Dec 3, 1988.

Address correspondence to Dr Johnston, Eastern Idaho Neurology Clinic, 2860 Channing Way, Suite 217, Idaho Falls, ID 83404.

*Current address: Eastern Idaho Neurology Clinic, Idaho Falls, ID.

†Current address: Stern Comprehensive Stroke Center, Montefiore Medical Center, Bronx, NY.

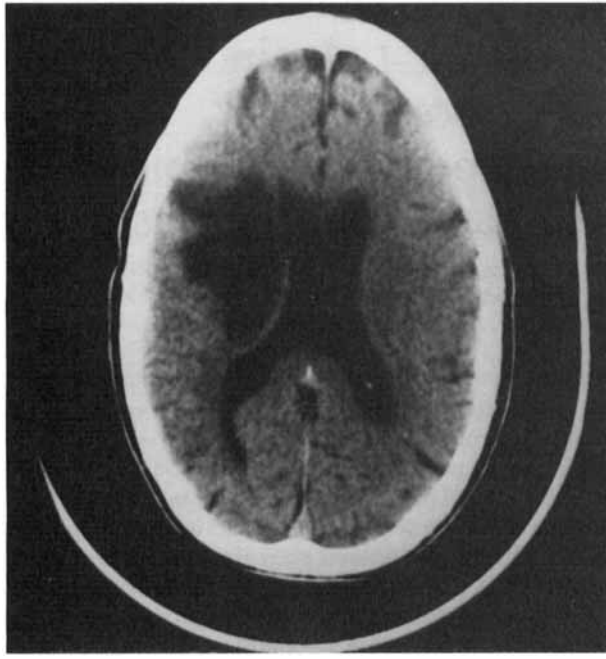


Fig 1. Computed tomograph of Patient 1 one week after presentation. Patient's right is viewer's left.

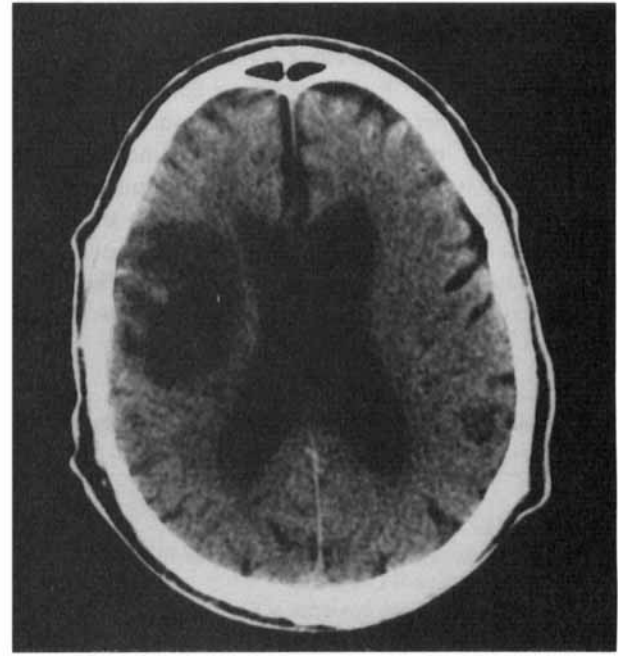


Fig 2. Computed tomograph of Patient 2 one week after presentation. Patient's right is viewer's left.

Nashold and Gillis [8] reported 1 patient who developed lid opening apraxia after placement of a thermal lesion in Forel's field H and the red nucleus for involuntary movements. Our patients had no evidence of extrapyramidal dysfunction.

The hypothesis that the cortex influences lid movements is not new. Early animal studies by Ferrier [9], Leyton and Sherrington [10], and others established this concept, and Penfield and Rasmussen [11] evoked lid opening by stimulating awake humans in the prefrontal as well as more posterior cortical regions. Of all lid movements, ptosis has most frequently been associated with cortical lesions. While many early cases of ptosis were simply attributed to a mass effect, Marquez [12] suggested that ptosis may be due to supranuclear disruption of ocular motor nerve pathways produced by lesions of the cerebral cortex or internal capsule.

Years later, Caplan [13] described 13 cases of unilateral or bilateral ptosis after hemispheric vascular events. None of his patients had apraxia. Other lid abnormalities including reflex blepharospasm [14] and motor impersistence [15, 16] have been associated with cortical lesions. Additionally, Walsh and Hoyt [17] reported a case of unilateral ptosis, contralateral to a temporal lobe epileptic focus.

Cortical lesions causing apraxia of lid movements, in particular of lid opening, have been much less frequently reported. Riese [18] described a patient who was unable to initiate lid elevation after a missile wound affecting both hemispheres. Nutt [19] described 2 stroke patients with difficulty initiating lid

Reported Cases of Apraxia of Eyelid Opening

Author	No. of Patients	Pathological Findings
Schilder (1927) [5]	2	Extrapyramidal
Riese (1930) [18]	1	Cortical (bilateral)
Goldstein and Logan (1965) [6]	4	Extrapyramidal
Nashold and Gillis (1967) [8]	1	Forel's H, red nucleus
Nutt (1977) [19]	2	Cortical (bilateral)
Colombo et al. (1982) [20]	1	Cortical (bilateral)
Dehaene (1984) [7]	3	Extrapyramidal
Lepore and Duvoisin (1985) [4]	6	Extrapyramidal
De Renzi et al (1986) [21]	1	Cortical (right hemisphere)

opening, but both also had bilateral ptosis. These patients had bilateral cortical disease, which the author stressed was necessary for the phenomenon of lid opening apraxia to occur. Colombo and colleagues [20] described 1 patient with lid opening apraxia who had bilateral cortical infarctions.

Our patients exhibited lid opening apraxia without other ocular or lid abnormalities, and the clinical and radiographic examinations indicated unilateral right hemispheric cortical involvement. De Renzi and colleagues [21] described several lid abnormalities in patients with hemispheric vascular lesions, and noted 1

patient with right brain disease who was unable to initiate lid elevation. However, little other clinical information was provided. Our cases do not identify the exact region responsible for lid opening apraxia, since the area involved by each infarct was quite extensive. However, as the apraxia resolved coincident with other signs of right parietal lobe dysfunction, we speculate that the same regions involved with non-dominant cortical function are responsible for lid opening apraxia. These cases suggest that eyelid opening apraxia may be due to right parietal lobe cortical dysfunction.

The authors wish to thank Betty Cobb for her assistance in the preparation of this article.

References

1. Lewandowsky M. Ueber apraxie dyes lidschlusses. *Klin Wochenschr* 1907;44:921-923
2. Rosati G, DeBastiani P, Granieri E, Agnetti V. Voluntary lid closure inability—release of a compulsive reaction to the exploration of the environment. *Arch Psychiatr Nervenkr* 1978; 226(1):11-17
3. Russel RWR. Supranuclear palsy of eyelid closure. *Brain* 1980;108:71-82
4. Lepore FE, Duvoisin RC. Apraxia of eyelid opening: an involuntary levator inhibition. *Neurology* 1985;35:423-427
5. Schilder P. Neuer beitrag zur pathologie der lidbewegungen. *Dtsch Z Nervenheilk* 1927;98:161-168
6. Goldstein JE, Cogan DG. Apraxia of lid opening. *Arch Ophthalmol* 1965;73:155-159
7. Dehaene I. Apraxia of eyelid opening in progressive supranuclear palsy. *Ann Neurol* 1984;15(1):115-116
8. Nashold BS Jr, Gillis JP Jr. Ocular signs from brain stimulation and lesions. *Arch Ophthalmol* 1967;77:609-618
9. Ferrier D. Experiments on the brains of monkeys. *Proc R Soc Lond* 1875;23:409-432
10. Leyton ASF, Sherrington CS. Observations on the excitable cortex of the chimpanzee, orang-utan and gorilla. *Q J Exp Physiol* 1917;11:135-227
11. Penfield W, Rasmussen T. *The cerebral cortex of man*, vol 75. New York: Macmillan, 1950:51-52
12. Marquez M. La lendidura palpebral normal y patologica. *Medicina Ibero*, Madrid 1936;1:209-222
13. Caplan LR. Ptosis. *J Neurol Neurosurg Psychiatry* 1974;37:1-7
14. Fisher CM. Reflex blepharospasm. *Neurology* 1963;13:77-78
15. Fisher CM. Left hemiplegia and motor impersistence. *J Nerv Ment Dis* 1956;123(3):201-218
16. Joynt RJ, Benton AL, Fogel ML. Behavioral and pathological correlates of motor impersistence. *Neurology* 1962;12:876-881
17. Walsh FB, Hoyt WF. *Clinical neurophthalmology*. 3rd ed. Baltimore: Williams & Wilkins, 1969
18. Riese W. Apraxie der lidoffnung. *J Psych Neurol Lpz* 1930; 40:347-355
19. Nutt JG. Lid abnormalities secondary to cerebral hemisphere lesions. *Ann Neurol* 1977;1:149-151
20. Colombo A, De Renzi E, Gibertani M. Eyelid movement disorders following unilateral hemispheric stroke. *Ital J Neurol Sci* 1982;3(1):25-30
21. De Renzi E, Gentilini M, Bazolli C. Eyelid movement disorders and motor impersistence in acute hemispheric disease. *Neurology* 1986;36:414-418

Induction of Aromatic-L-Amino Acid Decarboxylase by Decarboxylase Inhibitors in Idiopathic Parkinsonism

F. Boomsma, PhD,* J. D. Meerwaldt, MD,†
A. J. Man in 't Veld, MD,* A. Hovestadt, MD,†
and M. A. D. H. Schalekamp, MD*

We evaluated the effect of administration of L-dopa, alone or in combination with a peripheral decarboxylase inhibitor, on plasma levels of aromatic-L-amino acid decarboxylase (ALAAD). After single-dose administration of L-dopa plus benserazide (Madopar) in healthy subjects and in chronically treated patients with parkinsonism, plasma ALAAD followed for 2 to 3 hours fell, but returned to predosing levels within 90 minutes. Four groups of patients with idiopathic parkinsonism were studied during chronic treatment: Group I, no L-dopa treatment (n = 31); Group II, L-dopa alone (n = 15); Group III, L-dopa plus benserazide (n = 28); and Group IV, L-dopa plus carbidopa (Sinemet, n = 30). Plasma ALAAD 2 hours after dosing was normal in Groups I and II. ALAAD was increased threefold in Groups III and IV, suggesting induction of ALAAD by the coadministration of a peripheral decarboxylase inhibitor. In a study of 3 patients in whom L-dopa/benserazide was started, plasma ALAAD rose gradually over 3 to 4 weeks. Further detailed pharmacokinetic studies of L-dopa, dopamine, and ALAAD in plasma and cerebrospinal fluid are required to determine if the apparent ALAAD induction by a peripheral decarboxylase inhibitor may be related to the loss of clinical efficacy of combination therapy in some patients and how it is related to end-of-dose deterioration and on-off phenomena.

Boomsma F, Meerwaldt JD, Man in 't Veld AJ, Hovestadt A, Schalekamp MADH. Induction of aromatic-L-amino acid decarboxylase by decarboxylase inhibitors in idiopathic parkinsonism. *Ann Neurol* 1989;25:624-628

In patients suffering from Parkinson's disease L-dopa is often administered combined with so-called peripheral decarboxylase inhibitors (PDI's). PDI's inhibit the con-

From the Departments of *Internal Medicine I and †Neurology, University Hospital Dijkzigt, Erasmus University, Rotterdam, The Netherlands.

Received Sep 16, 1988, and in revised form Nov 14. Accepted for publication Dec 3, 1988.

Address correspondence to Dr Boomsma, Dept. of Internal Medicine I, Erasmus University, Dr Molewaterplein 40, 3015 GD Rotterdam, The Netherlands.