



Contents lists available at ScienceDirect

Pediatric Neurology

journal homepage: www.elsevier.com/locate/pnu

Clinical Observations

The Unique Coexistence of Anti-SS-A/Ro Antibodies in a Neonatal Case of Symptomatic Ischemic Stroke

Kenji Kanda MD*, Aya Sato MD, Daisuke Abe MD, Setsuko Nishijima MD, Tsuyoshi Ishigami MD, PhD

Department of Pediatrics, Hikone Municipal Hospital, Hikone, Shiga, Japan

ABSTRACT

BACKGROUND: Neonatal cerebral infarction is a relatively common cause of neonatal seizures, with an incidence of at least 1:4000 live births and is associated with a high incidence of neurological sequelae. However, the pathophysiological mechanisms and predisposing factors responsible for neonatal infarction are not fully established. **PATIENT DESCRIPTION:** A full-term baby boy was transferred at two days of age for the treatment of a cluster of seizures. Cranial magnetic resonance imaging revealed multiple lesions compatible with acute cerebral infarction. The results of the blood tests performed to screen for thrombophilic diseases were normal for his age, and his perinatal history was unremarkable. A diagnosis of idiopathic cerebral infarction was made. Additional examination for autoimmune diseases showed that both the mother and the patient had the anti-SS-A/Ro antibody. The patient was treated with phenobarbital and has no neurological sequelae. **CONCLUSIONS:** This is the first report demonstrating the coexistence of neonatal cerebral infarction and neonatal lupus syndrome. Thus neonatal lupus syndrome may be an additional risk factor for neonatal stroke.

Keywords: maternal autoantibodies, neonate, cerebral infarction, neonatal lupus syndrome

Pediatr Neurol 2016; ■: 1–4

© 2016 Elsevier Inc. All rights reserved.

Introduction

Neonatal cerebral infarction is a relatively common cause of neonatal seizures, with an incidence of at least 1:4000 live births, and is associated with a high incidence of neurological sequelae. However, the pathophysiological mechanisms and the predisposing factors responsible for neonatal infarction are not fully understood, and most cases are considered idiopathic.¹ Here, we report a case of a full-term baby with multiple cerebral infarctions and expression of the maternal anti-SS-A/Ro antibody. Transplacental passage of the autoantibody leads to neonatal lupus syndrome (NLS), which can affect the skin, heart, and in rare cases, the hepatobiliary or hematologic

systems.² Although neurological complications associated with NLS have been reported,³ there is only one case of acute cerebral stroke in early infancy.⁴ Herein, we describe another rare case of acute cerebral infarction associated with NLS. This is the first report of the the coexistence of neonatal cerebral infarction and NLS.

Patient Description

A male neonate was transferred because of a cluster of seizures on the second day after birth. He was the first baby to a previously healthy 23-year-old mother with a normal pregnancy and was born at term weighing 3180 g by elective Cesarean delivery for breech presentation, with an Apgar score of 9 points at one minute and 10 points at five minutes. It was a smooth delivery, and umbilical cord blood gas analysis showed pH 7.31, pCO₂ 49 mm Hg, HCO₃ 24 mEq/L, and base excess –2.0 mEq/L. At 44 hours after birth, the baby developed clonic movement of his right leg and arm lasting for several seconds. Seizures were observed intermittently over the next 4 hours, totaling four episodes. Upon arrival, another clonic seizure occurred on his right upper and lower limb lasting for approximately 20 seconds, which subsided without any medication. Neurological examination was normal without asymmetry of muscular tonus, strength, deep tendon reflexes, or brain stem reflexes. Inspection of the skin revealed no cutaneous diseases.

Informed consent: Informed consent was obtained from the parent.

Article History:

Received March 12, 2016; Accepted in final form June 8, 2016

* Communications should be addressed to: Dr. Kanda; Department of Pediatrics; Hikone Municipal Hospital; Hassaka-cho 1882; Hikone-shi, Shiga 522 8539, Japan.

E-mail address: kandak@municipal-hp.hikone.shiga.jp

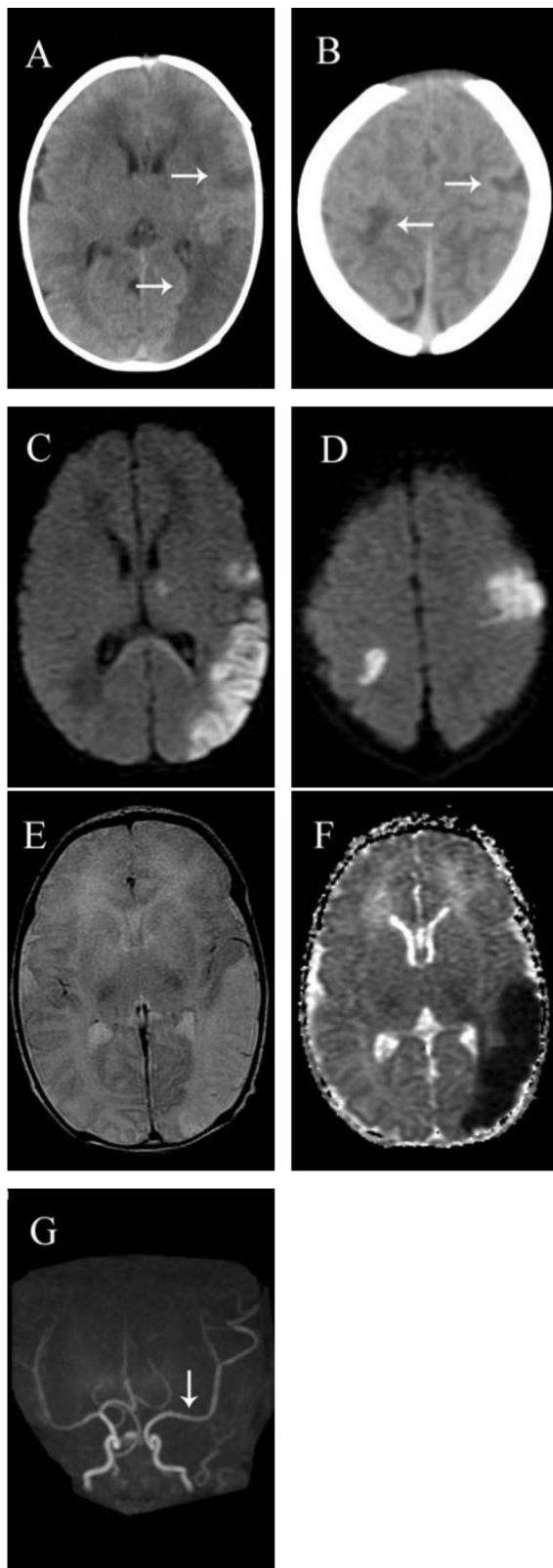


FIGURE. Cranial radiographic findings on admission of a male neonate with cerebral infarction associated with neonatal lupus syndrome. Cranial computed tomography showing multiple low-density areas (arrows) in the left frontal and temporal lobe and one part of the right parietal lobe (A, B). Diffusion-weighted images of cranial magnetic resonance imaging show high signal regions in the left frontal and temporo-occipital lobe, left thalamus, and

Computed tomographic scan showed multiple low-density areas in the region supplied by the left middle cerebral artery and in the right parietal lobe (Figure A, B). On cranial magnetic resonance (MR) imaging, diffusion-weighted images identified high signal regions in the left frontal and the temporo-occipital lobes, the left thalamus, and the right posterior frontal lobe (Figure C, D). These lesions were visualized as high intensity on T2-weighted images (Figure E) and as low intensity on the apparent diffusion coefficient map (Figure F). MR angiography (Figure G) showed a dilatation of the left middle cerebral artery, likely owing to reperfusion. These findings were consistent with an acute phase of ischemic stroke, and the patient was diagnosed as idiopathic neonatal cerebral infarction involving mainly the left middle cerebral artery territory.

Cardiac examination showed a regular heart rate of 142 beats/minute and no audible murmur. Electrocardiogram was normal. Echocardiogram showed no congenital structural abnormalities except for a patent foramen ovale. The results of the routine blood test including complete blood cell count, C-reactive protein, electrolytes, liver and renal function, blood sugar, and venous blood gas analysis were normal. Tests for blood coagulation were also within age-specific reference ranges: prothrombin time 13.8 seconds, prothrombin time–international normalized ratio 1.12, prothrombin time activity 72%, activated partial thromboplastin time 39.5 s, fibrinogen 265 mg/dL, and D-Dimer 1.5 μ g/mL. No paroxysmal discharge or asymmetrical attenuation was found on electroencephalogram recorded in the interictal period. An anticonvulsant (phenobarbital 5 mg/kg/day without a loading dose) was immediately administered for three days as a suppository and then orally.

The eighth attack at 67 hours of age was his last convulsion. His vital signs and respiration were consistently stable so that supportive therapy was not required. Additional evaluation related to coagulopathy and autoimmune disorders showed antithrombin III 34.9%, protein C antigen 35%, protein S antigen 24%, antinuclear antibody (ANA) 1:640 with a nuclear staining pattern of speckled, anti-beta-2-glycoprotein I antibody <0.7 U/mL (range, 0 to 2.5), lupus anticoagulant (Dilute Russell's viper venom time 1.09 [0 to 1.2]), anti-Ro/SS-A antibody greater than 500 U/mL (0 to 10), and anti-La/SS-B antibody <7.0 U/mL (0 to 10). The titer of ANA and the concentration of the anti-Ro/SS-A antibody were high, whereas the remaining parameters were within the normal neonatal range.

We considered that these autoantibodies were transmitted via the placenta and thus checked the mother for an autoimmune disorder. She was diagnosed with subclinical Sjögren syndrome on the result of her blood analysis; ANA 1:320 with a nuclear staining pattern of speckled, anti-Ro/SS-A antibody greater than 500 U/mL, anti-La/SS-B antibody 26.8 U/mL, rheumatoid factor 117.9 IU/mL (0 to 20), serum amylase 135 IU/L (43 to 116), and IgG 2927 mg/dL (870 to 1700). Treatment with phenobarbital was stopped at 8 days of age, and he developed no seizure afterward. There was no vasculopathy or new cerebral lesions on MR imaging at the age of 5.5 months.

The patient achieved standard developmental milestones at age 20 months without any motor paralysis. A gradual decrease in his autoantibodies was confirmed as follows. ANA started at 1:640 (day 3), gradually decreased to 1:320 (day 52), 1:160 (day 79), and 1:80 (day 169) and was then negative at day 295. Anti-SS-A antibody started at greater than 500 U/mL (day 22) and then gradually decreased to 352 U/mL (day 169), 41.7 U/mL (day 261), and 13.6 U/mL (day 295). This decrease in his autoantibodies suggests that they were actually transferred from the mother. The asymptomatic mother was informed that she needed to consult a doctor specializing in connective tissue disorders in case she has symptoms suggestive of Sjögren syndrome or wishes to have another child.

Discussion

Maternal autoimmune disorders are an important risk factor of neonatal cerebral infarction,¹ and a role for

the right posterior frontal lobe (C, D). The lesions were demonstrated on high intensity on T2-weighted images (E) and low intensity on apparent diffusion coefficient map (F). Magnetic resonance angiogram showed dilatation of the left middle cerebral artery (G).

TABLE.

Reports in Infancy of NLS With Both Objective Findings Prompting Neuroimaging and Imaging Abnormalities

Symptoms	Imaging Abnormalities	Gender/Age	Diagnostic Imaging Method	Presence of CHD	Hematologic Diseases	Cutaneous Disease	Reference
Left-sided clonic seizures	Infarct, SDH	Female/2m	MRI, CT	No	No	No	Saini et al. ⁴
Macrocephaly	Hydrocephalus	Female/4w, Female/6w	CT	No	No	Yes	Nakayama-Furukawa et al. ^{7,*}
Cluster of focal seizures	Low density of the periventricular and white matter	Male/20d	US, CT	No	Yes	Yes	Lin et al. ^{8,*}
Macrocephaly	Ventriculomegaly	Male/4m	US, CT	No	No	Yes	Prendiville et al. ^{9,*}
Macrocephaly	Hydrocephalus	Variable	US, CT	Variable	Variable	Variable	Boros et al. ^{10,*}
Poor activity	Intracranial hemorrhage	Male/2d	US, CT	No	Yes	No	Chen et al. ^{11,*}
Macrocephaly	Hydrocephalus	Male/2m	US, MRI	No	No	Yes	Yasue et al. ¹²
Cluster of focal seizures	Multiple cerebral infarction	Male/2d	CT, MRI	No	No	No	This case

Abbreviations:

CHD = Congenital heart disease

CT = Computed tomography

d = Days of age

m = Months

MRI = Magnetic resonance image

SDH = Subdural hematoma

US = Ultrasound scan

w = Weeks

* Reviewed case in Chen et al.³ and Saini et al.⁴

antiphospholipid syndrome is well established.⁵ However, our patient had no signs of coagulopathy or maternally transferred antibodies associated with antiphospholipid syndrome. Rather, we detected a maternal anti-SS-A/Ro antibody in the blood of the baby, and the mother was diagnosed with subclinical Sjögren syndrome. Transplacental passage of autoantibodies leads to NLS, which mainly affects the skin and heart, with rarer involvement of the hepatobiliary or hematologic systems. Central nervous system (CNS) involvement is estimated to occur in 1.4% of patients with NLS.²

The clinical features of NSL with CNS involvement are summarized in Table. Most reports involve patients with neuroimaging-determined abnormalities such as hydrocephalus, nonspecific white matter change, and sonography-detected vasculopathy without severe neurological symptoms. The association of NLS and acute cerebral stroke is very rare. Saini et al.⁴ reported a two-month-old girl with NLS who had acute cerebral stroke, and concluded that the attack was secondary to cerebral vasculitis based on angiography. In the present case, MR angiography showed a dilatation of the left middle cerebral artery likely owing to reperfusion but did not demonstrate vascular attenuations suggestive of vasculitis or an embolic source. Although it remains unclear whether the present case represents a causal relationship, intracranial hemodynamic instability demonstrated by means of ultrasound scan in Sjögren syndrome⁶ might have induced stroke in the prothrombotic perinatal period.

The possibility of preventive intervention for babies of anti-SS-A/Ro antibody-positive women is of interest. For example, several prenatal maternally administered treatments for avoiding congenital heart block in newborns of anti-SS-A/Ro antibody-positive women have been evaluated and reviewed.¹³ Anti-inflammatory therapy with a fluorinated steroid is promising if initiated at a stage of early AV nodal damage.^{13,14} Although a similar strategy may be applied to the neurological sequelae of NLS if its main pathology is an antibody-mediated inflammation

of the vascular endothelium, no causative role has been proven.

In conclusion, we describe a neonate with cerebral infarction and NSL. Although this is a single case study, we suggest that techniques other than the commonly performed coagulopathy panel could help to determine the etiology of neonatal stroke, because mothers of babies with NSL may have few symptoms. Furthermore, Inoue et al.¹⁵ reported a 17-year-old girl with NLS who developed CNS vasculopathy resembling moyamoya disease. Thus early diagnosis with NLS related to SS-A/Ro autoantibodies and long-term follow-up of the patient starting at birth are mandatory.

References

- Raju TN, Nelson KB, Ferriero D, et al. Ischemic perinatal stroke: summary of a workshop sponsored by the National Institute of Child Health and Human Development and the National Institute of Neurological Disorders and Stroke. *Pediatrics*. 2007;120:609-616.
- Dorner T, Feist E, Pruss A, et al. Significance of autoantibodies in neonatal lupus erythematosus. *Int Arch Allergy Immunol*. 2000;123:58-66.
- Chen C, Lin K, Wong AM, et al. Central nervous system manifestations of neonatal lupus: a systematic review. *Lupus*. 2013;22:1484-1488.
- Saini AG, Sankhyan N, Bhattad S, et al. CNS vasculitis and stroke in neonatal lupus erythematosus: a case report and review of literature. *Eur J Paediatr Neurol*. 2014;18:444-448.
- Simchen MJ, Goldstein G, Lubetsky A, et al. Factor V leiden and antiphospholipid antibodies in either mothers or infants increase the risk for perinatal arterial ischemic stroke. *Stroke*. 2009;40:65-70.
- Morreale M, Francia A, Marchione P, et al. Intracranial hemodynamic changes in primary Sjögren syndrome: a transcranial Doppler case-control study. *Neurol Sci*. 2015;36:1589-1595.
- Nakayama-Furukawa F, Takigawa M, Iwatsuki K, et al. Hydrocephalus in two female siblings with neonatal lupus erythematosus. *Arch Dermatol*. 1994;130:1210-1212.
- Lin S, Shyur S, Wu J, et al. Focal seizures as an unusual presentation of neonatal lupus erythematosus. *Asian Pac J Allergy Immunol*. 2005;23:61-64.

9. Prendiville J, Cabral D, Poskitt K, et al. Central nervous system involvement in neonatal lupus erythematosus. *Pediatr Dermatol.* 2003;20:60-67.
10. Boros CA, Spence D, Blaser S, et al. Hydrocephalus and macrocephaly: new manifestations of neonatal lupus erythematosus. *Arthritis Care Res.* 2007;57:261-266.
11. Chen C, Huang J, Hsu J, et al. Neonatal lupus complicated by hemorrhagic stroke. *Lupus.* 2012;21:1582-1585.
12. Yasue S, Kadoi E, Toyoshima Y, NM. Neonatal lupus erythematosus with hydrocephalus and macrocephaly born to an asymptomatic mother. *Jpn J Pediatr.* 2014;67:2115-2119. Japanese.
13. Hutter D, Silverman ED, Jaeggi ET. The benefits of transplacental treatment of isolated congenital complete heart block associated with maternal anti-Ro/SSA antibodies: a review. *Scand J Immunol.* 2010;72:235-241.
14. Llanos C, Izmirly PM, Katholi M, et al. Recurrence rates of cardiac manifestations associated with neonatal lupus and maternal/fetal risk factors. *Arthritis Rheum.* 2009;60:3091-3097.
15. Inoue K, Fukushige J, Ohno T, et al. Central nervous system vasculopathy associated with neonatal lupus. *Pediatr Neurol.* 2002;26:68-70.