

CONCISE REPORT

Encephalopathy with upper body hypertonia and myoclonus in patient with systemic lupus erythematosus and anti-CASPR2

A Castro¹, JC Romeu¹, R Geraldès² and JA Pereira da Silva¹

¹Serviço de Reumatologia e Doenças Ósseas Metabólicas, Hospital de Santa Maria, Centro Hospitalar de Lisboa Norte, Lisboa, Portugal; and

²Hospital de Santa Maria, Unidade de AVC, Serviço de Neurologia, Centro Hospitalar de Lisboa Norte, Lisboa, Portugal

Systemic lupus erythematosus (SLE) may involve the nervous system but there are no specific biomarkers of neuroSLE. Limbic encephalitis has been rarely associated with SLE. We present a case of a 22-year-old black woman where typical SLE psychosis evolved to an encephalopathy with atypical features, normal MRI, electroencephalogram slowing and frontal and occipito-temporal hypometabolism on fluorodeoxyglucose positron emission tomography (FDG PET).

Memory deficits, bizarre behaviour, psychosis, neuromyotonia and movement disorders have been described in autoimmune central nervous system disorders and associated with specific antibodies. Brain MRI may be normal and cortical brain hypometabolism on FDG PET scans has been reported. We have not found any report of limbic encephalitis or other SLE neurological manifestation associated to positive titres of anti-CASPR2 antibodies and this may warrant systematic investigation. In the rare cases of limbic encephalitis associated with SLE no specific antibodies were documented. Anti-CASPR2 antibodies have been associated not only with limbic encephalitis but also with neuromyotonia and Morvan syndrome. Although our patient had a specific pattern of tone abnormalities with an impressive cervical and upper limb hypertonicity and flaccid lower limbs, no myotonic discharges were found. We did not find any association between myoclonus and anti-CASPR2 antibodies. We cannot exclude that a non determined autoantibody could have played a role; however, clinical and FDG PET improvement supports an antibody-mediated injury, in this case of neuroSLE. *Lupus* (2016) 0, 1–4.

Key words: Neurolupus; systemic lupus erythematosus; encephalopathy; anti-CASPR2 antibodies

Introduction

Systemic lupus erythematosus (SLE) may present a broad spectrum of neurological manifestations. Though autoantibody-mediated neuronal lesion has been suggested in some cases, no serological test is recommended in the diagnosis of NeuroSLE (NSLE).¹

A substantial proportion of encephalitides are associated with autoantibodies directed against the extracellular domains of cell-surface proteins, critical in the regulation of neuronal excitability (LGII, CASPR2, contactin-2 (VGKC-complex

antibodies), and the NMDA, AMPA, and GABA-b receptors).²

VGKC-antibodies, originally identified in patients with neuromyotonia, were defined by their ability to precipitate voltage-gated potassium channel complexes from brain tissue (VGKC-complex antibodies). Contactin-associated protein-like 2 (CASPR2) is a cell adhesion molecule that clusters voltage-gated potassium channels at the juxtaparanodes of myelinated axons and may regulate axonal excitability. As a component of the voltage-gated potassium channels complex, CASPR2 has been identified as a target in neuromyotonia and Morvan syndrome, but also in some cases of autoimmune limbic encephalitis. How anti-CASPR2 autoimmunity is linked with the central neurological symptoms is still elusive.³

In autoimmune encephalopathies, such as limbic encephalitis, patients may present with amnesia,

Correspondence to: AM Castro, Hospital de Santa Maria, Centro Hospitalar de Lisboa Norte, Avenida Prof. Egas Moniz Lisboa, Lisboa 1649-035, Portugal.

Email: alicemcastro@gmail.com

Received 27 October 2015; accepted 1 June 2016

confusion and psychiatric features then develop a generalized encephalopathy, with loss of consciousness, movement disorders and hypothalamic disturbance.^{2,8} There are very few reported cases of limbic encephalitis in association with SLE.

We describe a case of a patient with SLE with an autoimmune encephalopathy and elevated titres of anti-CASPR2 antibodies.

Case report

A 22-year-old black woman presented with a three-month history of fatigue, fever, abdominal pain and myalgia. Pleural effusion, mild ascites, hepatosplenomegaly and pericardial effusion, leucopenia with lymphocytopenia, anaemia, thrombocytopenia, hypocomplementaemia, microscopic haematuria, proteinuria (with normal renal function), high ANA, anti-dsDNA (533 IU/ml) and anti-Sm, anti-RNP, anti-SSA and anti-SSB positivity were documented. Infection screening including Parvovirus, Cytomegalovirus, Epstein-Barr virus, Herpes simplex type 1 and type 2, Coxsackie, Echovirus, HIV 1 and 2, HBV, HCV were negative. Other agents such as *Rickettsia conorii*, *Coxiella burnetii*, *Toxoplasma gondii*, *Treponema pallidum*, *Leishmania*, *Borrelia burgdorferi* (Lyme), *Bartonella henselae*, *Brucella*, *Mycobacterium tuberculosis* (interferon gamma release assay) were negative. SLE was diagnosed and prednisone 60 mg daily started. One week later, after corticotherapy onset, inappropriate behaviour, bizarre and paranoid ideation, sexual disinhibition, disorientation and memory dysfunction were noticed. Steroid and SLE psychosis were considered but this was deemed unlikely since the clinical picture rapidly evolved to apathy, fluctuating attention, underactive behaviour, poor and incoherent speech, increased cervical and upper extremities tone, left hand myoclonus, slight muscle weakness of lower limbs, decreased deep tendon reflexes (DTRs). Days later there was autonomic disturbance with tachycardia and profuse sweating, associated with akinetic mutism, trismus, aphagia, increased cervical tone, moderate spastic weakness and decreased DTR in upper limbs, continuous myoclonus of the left hand, flaccid plegia with slight muscle atrophy, abolition of DTR in lower limbs and unresponsive plantar reflexes. Cerebrospinal fluid (CSF) examination revealed no cells, increased level of proteins (119.8 mg/dl) and increased IgG index. Bacteriologic exam of CSF was negative.

Brain magnetic resonance imaging (MRI) (D31) non enhancing showed punctate T2/FLAIR hyperintensities in the subcortical white fronto-opercular substance and adjacent to the frontal horns of lateral ventricles and in the subcortical white matter of the superior frontal gyrus on the right, with well-defined limits without mass effect or restriction on diffusion imaging. Spinal cord MRI was unremarkable (D53). Electroencephalography (EEG) with simultaneous surface electromyography (EMG) demonstrated slow background activity, with bilateral fronto-temporal delta wave bursts but no epileptic activity associated with left hand myoclonus and no neuromyotonia on needle EMG. Despite extensive screening no metabolic or infectious causes were evident.

A positron emission tomography (PET) scan (D73) showed frontal and occipito-temporal hypometabolism and striatal hypermetabolism (Figure 1a). Under the presumptive diagnosis of autoimmune encephalopathy due to anti-neuronal antibodies, voltage-gated potassium channel antibodies were measured and an elevated titre of anti-CASPR2 antibodies (1:320) was found through indirect immunofluorescence in a cell-based assay with transfectants cells (Autoimmune Encephalitis Mosaic 1, Euroimmun Medizinische Labordiagnostik AG). Other anti-neuronal antibodies were measured, such as anti-Hu (ANNA 1), anti-Ri (ANNA 2), anti-Yo, anti-Tr, anti-MAG, anti-GAD, anti-myelin, anti-glutamate receptors, anti-Ma, anti-amphiphysin, anti-GABA-b, anti-LGI1 and anti-CV 2 were negative. Thymoma and ovarian teratoma were excluded.

Due to the rapid progression of neurological signs (despite the high dose corticotherapy) intravenous IgG Kiovo[®] 10% (20 g/day for five days, from D51 to D55) was started and after the exclusion of CSF infection cyclophosphamide (CYC) was initiated (750 mg/m², preceded by ondasetron 8 mg, in association with MESNA (300 mg + 150 mg + 150 mg at 0 h, 4 h and 8 h respectively). A total of six pulses were repeated monthly (the dose of CYC was reduced at the third pulse – white blood cell nadir less than 1500–2000/mm³). After the second pulse of CYC, with no neurological improvement we considered the hypothesis of autoimmune encephalopathy due to anti-neuronal antibodies (elevated titre of anti-CASPR2 antibodies 1:320) and the patient started plasmapheresis (eight sessions, from D71 to D80) followed by a slow and gradual clinical improvement.

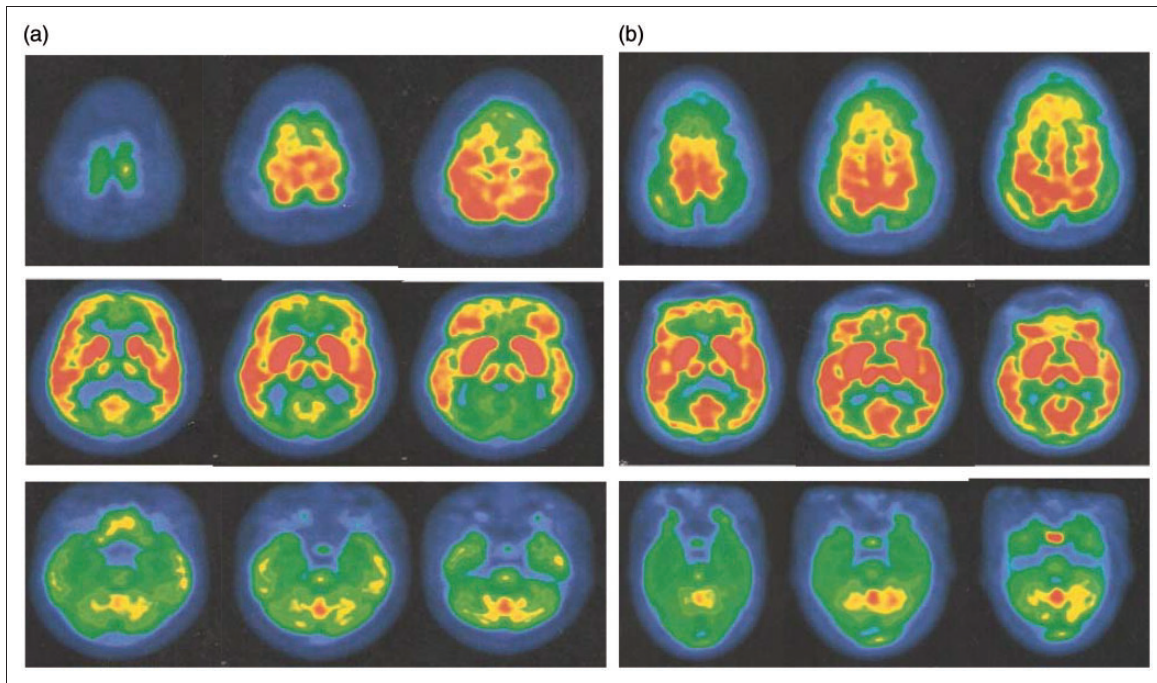


Figure 1 Brain positron emission tomography (PET) scan. a) Brain PET scan performed at day 73 showing frontal and occipito-temporal hypometabolism and striatal hypermetabolism. b) Brain PET scan repeated at D111, after plasmapheresis, with improvement of cerebral metabolism.

The PET scan was repeated at D111 and documented an improvement of cerebral metabolism (Figure 1b). Repeated anti-CASPR2 antibodies (D108) were negative.

We began steroid tapering gradually after eight weeks to a stable dose of 20 mg at the time of the beginning of azathioprine as a remission maintenance agent. At 12-month follow-up, on 5 mg/day steroids and 100 mg/day azathioprine, the patient has a mild right foot drop, has stable disease and is back to her usual life.

Discussion

We present a case where typical SLE psychosis evolved to an encephalopathy with atypical features (trismus, aphagia, tone changes, asymmetric myoclonus), normal MRI, EEG slowing and frontal and occipito-temporal hypometabolism on fluorodeoxyglucose positron emission tomography (FDG PET). Memory deficits, bizarre behaviour, psychosis, neuromyotonia and movement disorders have been described in autoimmune central nervous system disorders and associated with specific antibodies.^{2,4} Brain MRI may be normal and cortical brain hypometabolism on FDG PET scans has

been reported.⁵ We have not found any report of limbic encephalitis or other SLE neurological manifestation associated with positive titres of anti-CASPR2 antibodies and this may warrant systematic investigation. In the rare cases of limbic encephalitis associated with SLE^{6,7} no specific antibodies were documented. Anti-CASPR2 antibodies have been associated not only with limbic encephalitis but also with neuromyotonia and Morvan syndrome. Although our patient had a specific pattern of tone abnormalities with an impressive cervical and upper limb hypertonicity and flaccid lower limbs, no myotonic discharges were found. We did not find any association between myoclonus and anti-CASPR2 antibodies.³ We cannot exclude that a non determined autoantibody could have played a role; however, clinical and FDG PET improvement supports an antibody-mediated injury in this case of NSLE.

Declaration of Conflicting Interests

The author(s) declared no potential conflicts of interest with respect to the research, authorship, and/or publication of this article.

Funding

The author(s) received no financial support for the research, authorship, and/or publication of this article.

References

- 1 Bertsias GK, Ioannidis JP, Aringer M, *et al.* EULAR recommendations for the management of systemic lupus erythematosus with neuropsychiatric manifestations: Report of a task force of the EULAR standing committee for clinical affairs. *Ann Rheum Dis* 2010; 69: 2074–2082.
- 2 Irani SR, Vincent A. Autoimmune encephalitis – new awareness, challenging questions. *Discov Med* 2011; 11: 449–458.
- 3 Vincent A, Bien CG, Irani SR, Waters P. Autoantibodies associated with diseases of the CNS: New developments and future challenges. *Lancet Neurol* 2011; 10: 759–772.
- 4 Graus F, Titulaer MJ, Balu R, *et al.* A clinical approach to diagnosis of autoimmune encephalitis. *Lancet Neurology* 2016; 15: 391–404.
- 5 Fauser S, Talazko J, Wagner K, *et al.* FDG-PET and MRI in potassium channel antibody-associated non-paraneoplastic limbic encephalitis: Correlation with clinical course and neuropsychology. *Acta Neurol Scand* 2005; 111: 338–343.
- 6 Bien CG, Elger CE. Limbic encephalitis: A cause of temporal lobe epilepsy with onset in adult life. *Epilepsy Behav* 2007; 10: 529–538.
- 7 Kano O, Arasaki K, Ikeda K, *et al.* Limbic encephalitis associated with systemic lupus erythematosus. *Lupus* 2009; 18: 1316–1319.
- 8 Samarasekera SR, Vincent A. Course and outcome of acute limbic encephalitis with negative voltage-gated potassium channel antibodies. *J Neurol Neurosurg Psychiatry* 2007; 78: 391–394.