

CASE REPORT

Paradoxical cerebral air embolism causing large vessel occlusion treated with endovascular aspiration

Patrick J Belton,¹ Ashish Nanda,² Syeda L Alqadri,³ Gurpreet S Khakh,³ Premkumar Nattanmai Chandrasekaran,³ Christopher Newey,³ William E Humphries¹

¹Division of Neurosurgery, University of Missouri Columbia School of Medicine, Columbia, Missouri, USA
²SSM Health Medical Group, Fenton, Missouri, USA
³Department of Neurology, University of Missouri Columbia School of Medicine, Columbia, Missouri, USA

Correspondence to

Dr W E Humphries, Division of Neurosurgery, University of Missouri Columbia School of Medicine, Columbia, MO 65212, USA; humphriesw@health.missouri.edu

Accepted 20 June 2016

SUMMARY

Cerebral air embolism is a dreaded complication of invasive medical procedures. The mainstay of therapy for patients with cerebral air embolism has been hyperbaric oxygen therapy, high flow oxygen therapy, and anticonvulsants. We present a novel therapeutic approach for treatment of cerebral air embolism causing large vessel occlusion, using endovascular aspiration. Our patient developed a cerebral air embolism following sclerotherapy for varicose veins. This caused near total occlusion of the superior division of the M2 segment of the right middle cerebral artery. Symptoms included unilateral paralysis, unintelligible speech, and hemianopia; National Institutes of Health Stroke Scale (NIHSS) on presentation was 16. The air embolism was treated using a distal aspiration technique. Angiography following aspiration showed Thrombolysis in Cerebral Infarction 2B reperfusion. Following aspiration, the patient was re-examined; NIHSS at that time was 4. At 1 month follow-up, the modified Rankin Scale score was 1 and NIHSS was 1. Treatment of cerebral air embolism is discussed.

BACKGROUND

Cerebral air embolism is a potentially devastating sequela of invasive medical procedures. In our case, the patient developed cerebral air embolism after sclerotherapy for varicose veins, a rare but known complication of this procedure.¹ Treatment has mainly been systemic, with hyperbaric or high flow oxygen.² Despite these measures, the fatality rate for these patients is 20% or higher in certain series.³ Here we present the novel use of a previously described technique⁴ for the treatment of cerebral air embolism using endovascular aspiration in a patient who presented with acute hemiplegia and dysarthria secondary to an intracranial air embolism. Cerebral endovascular aspiration of air occluding a large vessel soon after symptom onset produced a remarkable recovery in the patient.

CASE PRESENTATION

The patient was a 73-year-old right handed Caucasian male with a past medical history significant for acute ischemic stroke 27 years prior without any residual deficits; skull fracture, traumatic subdural hematoma, and cerebral contusion 7 years prior; cardiovascular disease; hypertension and hyperlipidemia; and was receiving sclerotherapy

for symptomatic varicose veins resistant to compression socks at an outpatient surgery center. This was the sixth time that the patient had received this therapy, reportedly without prior complication. The patient was given 12 mL of sodium tetradecyl sulfate 1% foam solution injected into the affected left leg veins under ultrasound guidance. The patient developed sudden onset left-sided weakness, facial droop, and speech difficulties 15–20 min after the injections. He was transported by ambulance to the University of Missouri Hospital for evaluation and treatment.

On arrival, approximately 25 min after symptom onset, the patient's National Institutes of Health Stroke Scale (NIHSS) score was 16 (complete hemianopia, major facial paralysis, left upper extremity and lower extremity hemiplegia, mild to moderate decrease in sensation on left, near unintelligible speech or unable to speak, and extinction).

INVESTIGATIONS

Non-contrast and CT angiography of the head and neck were completed within 15 min of arrival. A non-contrast CT scan revealed no evidence of intracranial hemorrhage but was notable for hypodense foci concerning for air in the right sylvian fissure and within the subarachnoid spaces of the right frontal lobe (figure 1). CT angiography was notable for punctate air within the right M2 middle cerebral artery (MCA) with severe narrowing of the right MCA superior division (figure 2).

TREATMENT

Tissue plasminogen activator was not administered. The patient was taken emergently to the endovascular suite. After arterial catheterization, digital subtraction angiography was performed. Intracranial views of the right internal carotid artery injection revealed an occlusion of the superior division of the right MCA with significantly diminished anterior grade flow distal to this (figure 3). After identification of the right superior division MCA occlusion, a 5 Fr vertebral catheter was exchanged for a Neuron 088 guide catheter (Penumbra, Alameda, California, USA) using a Rosen exchange length wire. The guide catheter was positioned in the cervical portion of the right internal carotid artery. An Ace 64 (Penumbra) reperfusion catheter was directed over a Headway 17 microcatheter (Microvention, Tustin, California, USA) and a Synchro 2 microwire (Stryker Neurovascular, Fremont, California, USA)



CrossMark

To cite: Belton PJ, Nanda A, Alqadri SL, et al. *BMJ Case Rep* Published online: [please include Day Month Year] doi:10.1136/bcr-2016-012535

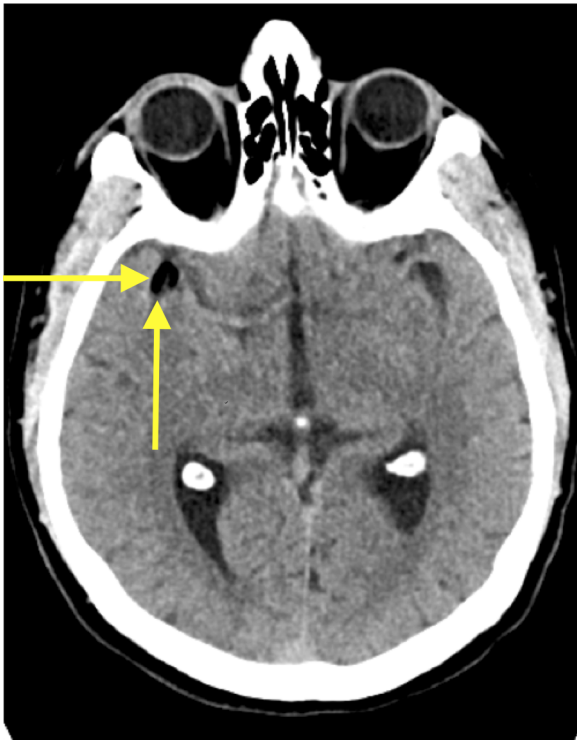


Figure 1 Non-contrast axial CT showing air density material near the expected bifurcation of the middle cerebral artery (arrows).

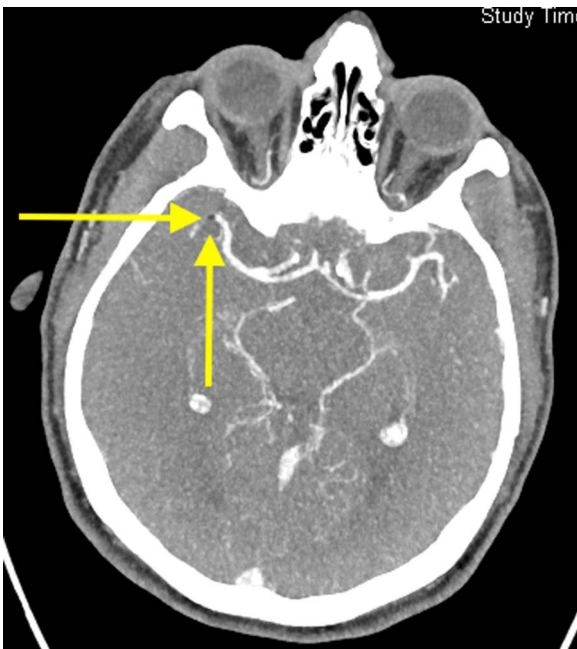


Figure 2 CT angiography showing air density material in the middle cerebral artery, superior division, with minimal filling past the stenosis (arrow).

and positioned in the superior M2 division of the right MCA. The Headway 17 and microwire were removed and the Ace 64 reperfusion catheter was then connected to a mechanical suction device (Penumbra) for aspiration and pulled slowly back into the guide catheter. This was repeated two times.

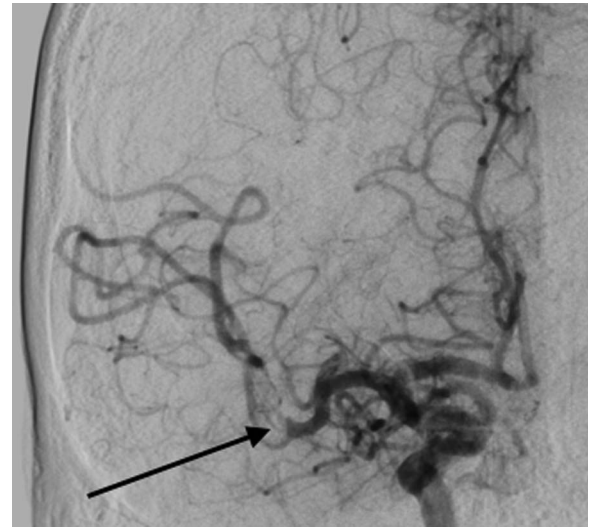


Figure 3 Digital subtraction angiography, internal carotid artery injection, showing split flow in the vessel lumen, around the presumed air bubble (arrow).

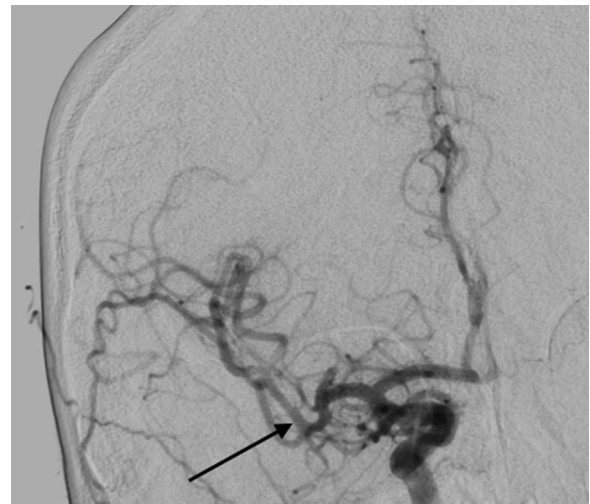

Figure 4 Digital subtraction angiography, internal carotid artery injection, after aspiration, showing recanalization and restoration of blood flow (arrow).

OUTCOME AND FOLLOW-UP

Following aspiration, repeat angiography showed Thrombolysis in Cerebral Infarction 2B reperfusion (figure 4). The procedure was completed in 37 min (1 hour 49 min after symptom onset). On completion of the procedure, the patient's NIHSS was 4 (mild left upper and lower extremity drift, minor facial paralysis, and mild dysarthria). During the procedure as well as afterwards, the patient received 2 L/min of oxygen via nasal cannula. A brain MRI the following day was notable for some small foci of diffusion restriction in the right frontal, parietal, and temporal lobes, but no large territory infarct (figure 5). Echocardiogram with bubble study was notable for a right to left shunt that increased significantly with Valsalva, consistent with a patent foramen ovale (figure 6). The patient's remaining hospital stay was uncomplicated, and he was discharged to inpatient rehabilitation on day 3 with an NIHSS score of 3.

Figure 5 MRI of the brain, performed the day following the procedure, showing hyperintensity on diffusion weighted imaging (left) and apparent diffusion coefficient hypointensity (right) on both sides of the central sulcus.

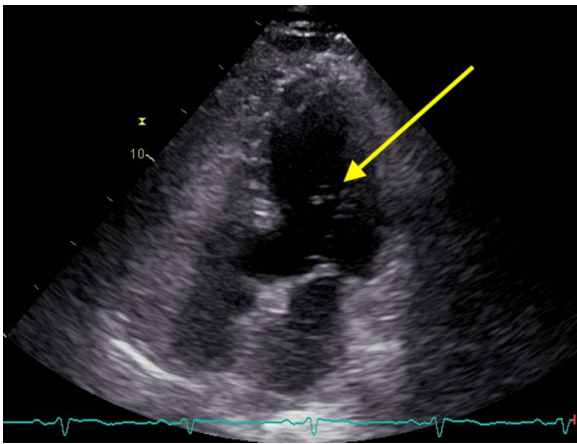
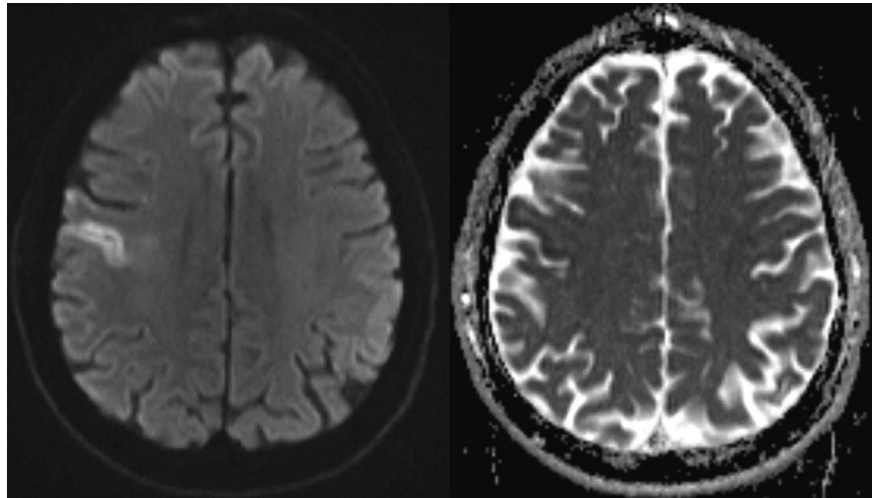


Figure 6 Echocardiography bubble study, performed with Valsalva maneuver, showing egress of agitated saline bubbles into the left atrium and left ventricle (arrows).

At 1 month follow-up the modified Rankin Scale score was 1 and NIHSS was 1.

DISCUSSION

While intracranial air embolism is a known complication of sclerotherapy¹ and other medical procedures, the treatment modality used in this particular case has not been reported previously and represents a novel therapeutic technique.

Air embolism is a risk for many medical procedures. Most commonly air embolism affects the pulmonary vasculature.⁵ One treatment sometimes advocated for pulmonary gas embolism is right atrial gas aspiration using a central venous catheter.^{6 7} Arterial air embolism is less commonly encountered. Arterial air embolism occurs via a direct introduction of air into the arterial system, via a patent foramen ovale, in the presence of an arteriovenous shunt, or via transmission through pulmonary capillary beds.⁷ Cerebral arterial air embolism has been reported from procedures as varied as lung biopsy,⁸ endoscopic gastrointestinal procedures,⁹ and cerebral angiograms.¹⁰

Depending on the quantity and distribution of air in the arterial system, symptoms of cerebral air embolism can range from temporary motor weakness and headache to hemianopia, hemiparesis, convulsions, coma, and death.⁷ Patients like this one who present with advanced age, mental status changes,

hemiparesis, and gyriform air on initial CT are noted to have an unfavorable prognosis.¹¹

The mainstay of treatment in symptomatic cerebral air embolism has been hyperbaric oxygen therapy, high flow oxygen, and anticonvulsants.¹⁰ Despite these measures, within published case reports there is a mortality rate as high as 22%.^{3 11} For cardiac arterial air embolism, direct aspiration has been applied, with some promising results.^{12 13} To the authors' knowledge, there have been no reported cases of endovascular aspiration in the treatment of patients with intracranial air embolism. We adapted a distal aspiration technique described previously⁴ for treatment of our patient with excellent results. Based on the rapid response of our patient to aspiration of entrapped air, we believe this may represent a new therapeutic option for certain patients with large vessel occlusion caused by intracranial air embolism.

Learning points

- ▶ Cerebral air embolism is a potentially devastating sequela of invasive medical procedures.
- ▶ The mainstay of treatment has been high flow oxygen and hyperbaric oxygen.
- ▶ Some patients with large vessel occlusion caused by intracranial air emboli may benefit from endovascular aspiration.

Contributors PJB, AN, SLA, GSK, PNC, and WEH all contributed equally to the writing and editing of this submission and approved the submission. CN contributed to the writing of the article and approved its submission.

Competing interests None declared.

Patient consent Obtained.

Ethics approval The study was approved by the University of Missouri Institutional Review Board.

Provenance and peer review Not commissioned; externally peer reviewed.

Data sharing statement Additional data from the case (other images in the identified studies, laboratory values) are available on request to the corresponding author.

REFERENCES

- 1 Bush RG, Derrick M, Manjoney D. Major neurological events following foam sclerotherapy. *Phlebology* 2008;23:189–92.

- 2 Bartolini L, Burger K. Pearls & oysters: cerebral venous air embolism after central catheter removal: too much air can kill. *Neurology* 2015;84:e94–6.
- 3 Pinho J, Amorim JM, Araújo JM, *et al.* Cerebral gas embolism associated with central venous catheter: Systematic review. *J Neurol Sci* 2016;362:160–4.
- 4 Turk AS, Frei D, Fiorella D, *et al.* ADAPT FAST study: a direct aspiration first pass technique for acute stroke thrombectomy. *J Neurointerv Surg* 2014;6:260–4.
- 5 Bessereau J, Genotelle N, Chabbaut C, *et al.* Long-term outcome of iatrogenic gas embolism. *Intensive Care Med* 2010;36:1180–7.
- 6 Stallworth JM, Martin JB, Postlethwait RW. Aspiration of the heart in air embolism. *J Am Med Assoc* 1950;143:1250–1.
- 7 Muth CM, Shank ES. Gas embolism. *N Engl J Med* 2000;342:476–82.
- 8 Um SJ, Lee SK, Yang DK, *et al.* Four cases of a cerebral air embolism complicating a percutaneous transthoracic needle biopsy. *Korean J Radiol* 2009;10:81–4.
- 9 Pee L, Basu S, Loganayagam A. Cerebral air embolism: a rare complication following balloon dilation. *Endoscopy* 2013;45(Suppl 2) UCTN:E93–4.
- 10 Tan LA, Keigher KM, Lopes DK. Symptomatic cerebral air embolism during stent-assisted coiling of an unruptured middle cerebral artery aneurysm: intraoperative diagnosis and management of a rare complication. *J Cerebrovasc Endovasc Neurosurg* 2014;16:93–7.
- 11 Cheng CK, Chang TY, Liu CH, *et al.* Presence of gyriiform air predicts unfavorable outcome in venous catheter-related cerebral air embolism. *J Stroke Cerebrovasc Dis* 2015;24:2189–95.
- 12 Solodky A, Birnbaum Y, Assali A, *et al.* Coronary air embolism treated by bubble aspiration. *Catheter Cardiovasc Interv* 2000;49:452–4.
- 13 Patterson MS, Kiemeneij F. Coronary air embolism treated with aspiration catheter. *Heart* 2005;91:e36.

Copyright 2016 BMJ Publishing Group. All rights reserved. For permission to reuse any of this content visit <http://group.bmj.com/group/rights-licensing/permissions>.
BMJ Case Report Fellows may re-use this article for personal use and teaching without any further permission.

Become a Fellow of BMJ Case Reports today and you can:

- ▶ Submit as many cases as you like
- ▶ Enjoy fast sympathetic peer review and rapid publication of accepted articles
- ▶ Access all the published articles
- ▶ Re-use any of the published material for personal use and teaching without further permission

For information on Institutional Fellowships contact consortiasales@bmjgroup.com

Visit casereports.bmj.com for more articles like this and to become a Fellow