



# A long-living case of carotid aneurysm caused by inflammatory leiomyosarcoma

Ichiro Morita, Ryuutaro Isoda, Youko Hirabayashi and Yoshio Naomoto

## Abstract

We report here on a long-surviving patient with a vascular leiomyosarcoma arising in the right common carotid artery, and some possible reasons for the long-term survival. The patient was a 40-year-old woman who was diagnosed with a right common carotid aneurysm and underwent aneurysmectomy with graft replacement. Two years and nine months after her surgery, she developed a cerebral infarction and left hemiparesis due to graft occlusion, but later achieved functional recovery through physical rehabilitation. She has been alive for 20 years since her surgery.

## Keywords

Aneurysm, Carotid artery, common, Diagnosis, differential, Inflammation, Leiomyosarcoma, Vascular neoplasms

## Introduction

Vascular leiomyosarcomas are very rare, accounting for only 2%–5% of all leiomyosarcomas. The majority arise in the inferior vena cava or the pulmonary artery, and approximately 20 have been reported to arise in peripheral arteries. We describe a very rare case of leiomyosarcoma arising in the common carotid artery. It is also very unusual for such a patient to be alive for 20 years after surgery.

## Case report

A 40-year-old woman presented with a 2 × 4-cm pulsating mass in the middle of the right side of her neck. A cervical magnetic resonance scan revealed aneurysmal dilation of the common carotid artery with a markedly thickened wall and mural thrombosis (Figure 1a). Aortic and right carotid angiography showed a 4-cm saccular aneurysm protruding posteriorly from the origin of the right common carotid artery (Figure 1b). The patient underwent surgery under general anesthesia with a preoperative diagnosis of right common carotid aneurysm. Creating a temporary bypass was more advantageous than an inner shunt graft to secure the surgical field and ensure sufficient cerebral blood flow, because the lesion was near the origin of the right common carotid artery. Resection of the aneurysm was performed under temporary bypass with a 5-mm

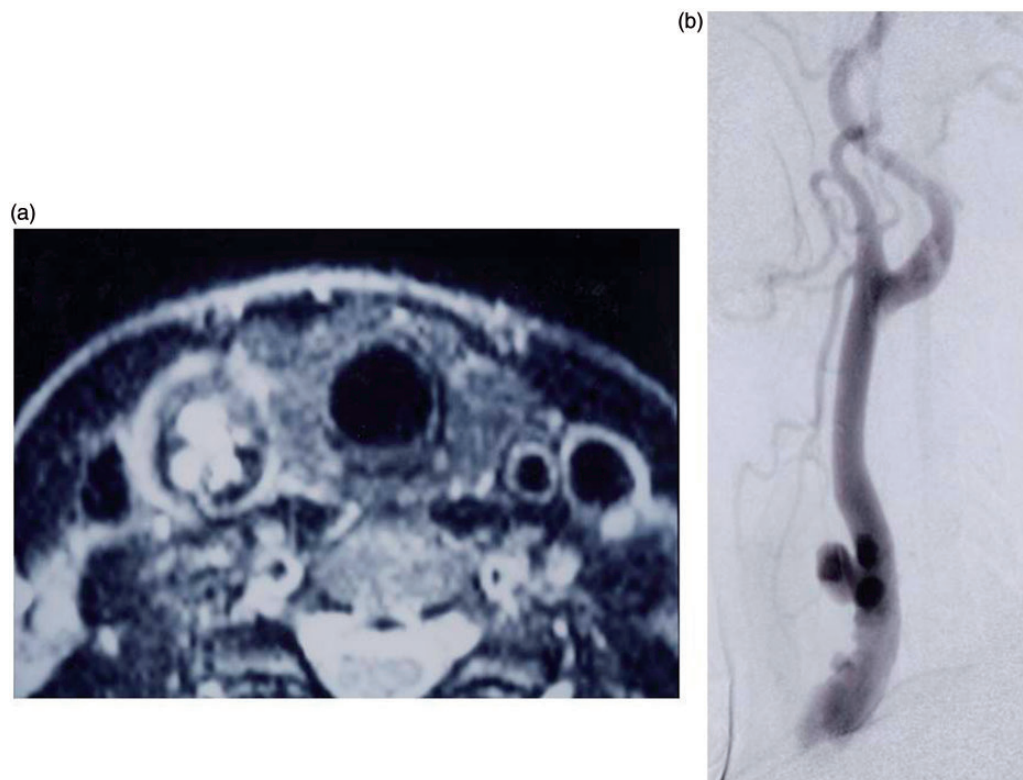
expanded polytetrafluoroethylene prosthetic graft between the left axillary artery and the right common carotid artery (Figure 2). Around the origin of the right common carotid artery, two continuous aneurysms, 2 × 3 cm and 3 × 4 cm, were adhering to the surrounding tissue. The aneurysmal lumen contained a thrombus as big as 2 × 2 cm, and the aneurysmal wall had a markedly thickened intima and 3 intimal defects. The diameter of the bilateral great saphenous vein was 3 mm and was therefore considered inappropriate as a graft. Prosthetic grafting of the right common carotid artery with an 8-mm prosthetic graft (Intervascular) was performed. Intraoperative brain monitoring with transcranial Doppler ultrasound showed no signs of a major event. Pathological examination showed that the mass involved the arterial wall, partially destroying the wall and growing over the luminal and external surfaces. Spindle-shaped tumor cells exhibited marked atypia with pleomorphic nuclei with irregular borders and hyperchromasia accompanied by prominent infiltration

Department of General Surgery, Kawasaki Medical School, Okayama, Japan

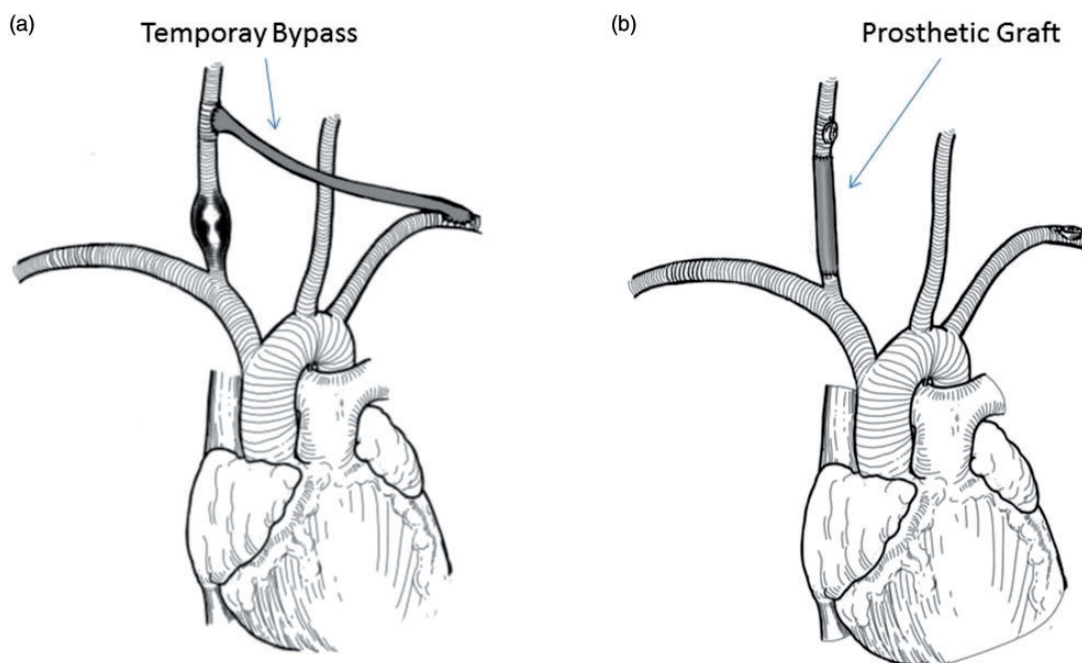
### Corresponding author:

Ichiro Morita, 2-1-80 Nakasange Kitaku Okayama, Okayama 700-8505, Japan.

Email: [ichiro@med.kawasaki-m.ac.jp](mailto:ichiro@med.kawasaki-m.ac.jp)



**Figure 1.** (a) Magnetic resonance scan showing a mural thrombus within the dilated artery, the wall of which is also markedly thickened. (b) Digital subtraction angiography in lateral view, demonstrating marked segmental dilatation of the right common carotid artery. A prominent aneurysmal portion protrudes laterally and posteriorly.<sup>1</sup>

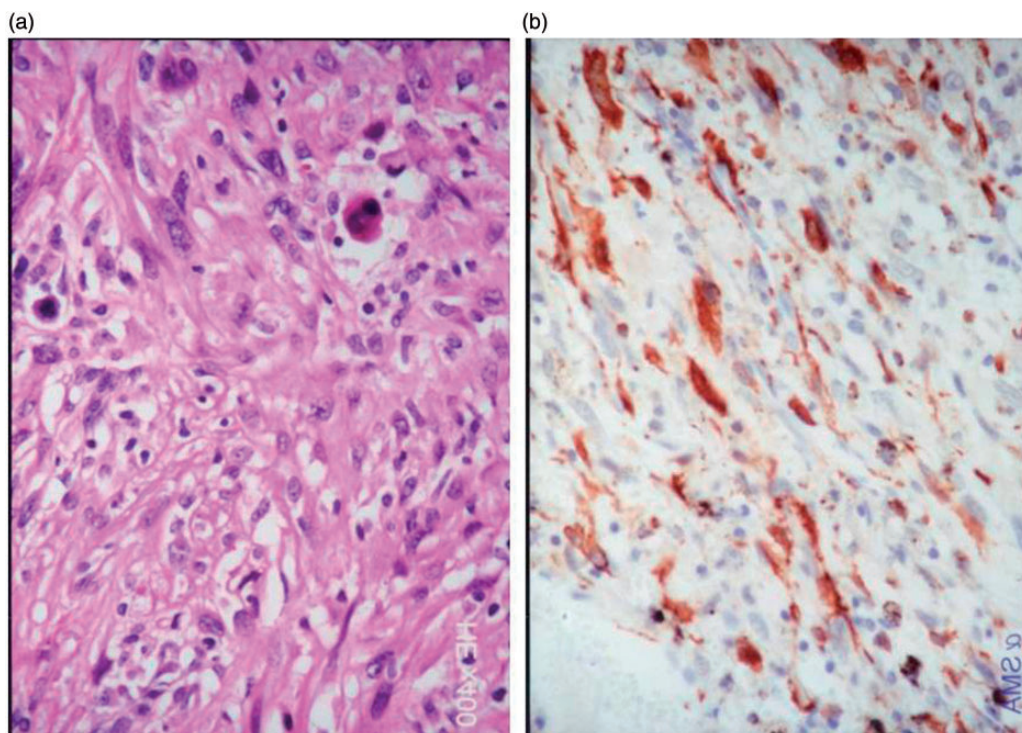


**Figure 2.** (a) Resection of the aneurysm was performed under a temporary bypass with a 5-mm prosthetic graft between the left axillary artery and the right common carotid artery. (b) Prosthetic grafting of the right common carotid artery was performed with an 8-mm graft.

of inflammatory cells consisting mainly of lymphocytes (Figure 3a). The tumor component was located between the media and adventitial fibrous tissue. The tumor cells were positive on periodic acid-Schiff staining, suggestive of smooth muscle cells rather than fibroblastic cells. Upon immunostaining, they were positive for vimentin and smooth muscle actin (Figure 3b), partially positive for anti-muscle actin antibody, and negative for desmin, S-100, human alveolar macrophage antibody, keratin, CD34, and factor VIII. These findings led to a diagnosis of inflammatory leiomyosarcoma. The patient's postoperative course was uneventful, and she had regular oral cilostazol postoperatively. She was discharged on the 25th postoperative day because of a persistent mild headache, and was followed up regularly at the outpatient department. However, 2 years and 9 months after her surgery, she suddenly developed a cerebral infarction and left hemiparesis due to right carotid artery graft occlusion, and was readmitted to our department. After 3 months of inpatient physical rehabilitation, she was discharged home under the care of her family doctor. Since that time, 17 years (20 years after the surgery) have passed with no recurrence of the tumor but she is confined to a wheelchair at present.

## Discussion

Leiomyosarcomas are relatively common tumors, accounting for 10% of all malignant soft tissue tumors. They usually affect individuals 40–60 years of age, and arise from smooth muscle tissue in all sites in the body, most frequently from the gastrointestinal tract and the uterus, but rarely from blood vessel walls.<sup>2</sup> Because the clinical course varies with the site of tumor origin, leiomyosarcomas are classified as: retroperitoneal-peritoneal type (40%–45%), deep soft tissue type (30%–35%), dermal type (14%–20%), and vessel wall type (5%).<sup>2</sup> Leiomyosarcomas arising from the retroperitoneal space or the inferior vena cava have a female predominance, whereas those arising from the skin have a male predominance.<sup>2</sup> The vessel wall type accounts for only 2%–5% of all leiomyosarcomas, more than 80% of which arise from veins, most frequently from the inferior vena cava. Of the remaining primary arterial leiomyosarcomas (representing less than 20%), half arise from the pulmonary artery, and the other half arise from the aorta and peripheral arteries, including the iliac, femoral, popliteal, subclavian, axillary, renal, and splenic arteries.<sup>3,4</sup> However, our search of the literature revealed that a report by Mikami and colleagues<sup>1</sup> was the first



**Figure 3.** (a) The neoplastic component consisted of spindle cells arranged in an interlacing bundle pattern. The large nuclei of spindle cells showed an irregular and blunt-ended configuration, coarsely granular chromatin, and conspicuous nucleoli. Mitotic figures were frequently observed. Hematoxylin and eosin stain, original magnification  $\times 400$ . (b) Immunohistochemical staining of  $\alpha$ -smooth muscle actin. The tumor cells were positive for actin. Original magnification  $\times 400$ .



documented case of primary leiomyosarcoma of the carotid artery.

Primary leiomyosarcomas of arteries, including the one reported here, often pose diagnostic difficulties, and are commonly diagnosed during surgery as an aneurysm. The prognosis of leiomyosarcoma varies greatly with the location of the primary tumor. Leiomyosarcomas arising in the dermis have little tendency to metastasize, although they may recur. Many other leiomyosarcomas have a poor prognosis; those arising in the abdominal cavity, deep soft tissue, or a vascular wall have 5-year survival rates of 20%–30%, 60%–65%, and 20%, respectively.<sup>2</sup> Sixty percent of vascular leiomyosarcomas metastasize, mainly to the lungs, liver, lymph nodes, and soft tissues.<sup>5</sup> Gustafson and colleagues<sup>6</sup> evaluated vascular invasion as a prognostic factor, and reported that leiomyosarcomas with and without vascular invasion had 5-year survival rates of 36% and 80%, respectively. Therefore, the vessel wall type of leiomyosarcoma has a poor prognosis. Our patient has been recurrence- and metastasis-free for 20 years since her surgery, without receiving postoperative therapy, probably because the tumor was relatively small with a diameter of 4 cm, and the peritumor tissue was removed completely en bloc. One factor related to a better prognosis is a strong inflammatory reaction, seen in the pathological findings. Merchant and colleagues<sup>9</sup> reported 12 cases of inflammatory leiomyosarcoma observed from the first month to the 11th year. Four cases were recurrent; 3 of these were local and one had a distal metastasis to the lung, but all of the patients were still alive. The precise reasons for these successful survivals are unclear; however, the fact that the prognosis is better in inflammatory than in non-inflammatory cases, and our patient had strong inflammatory findings, might explain her survival up to 20 years after surgery without any recurrence or metastasis.

The treatment of choice is complete removal of the tumor, that is, extended tumor resection. Some studies have recommended aggressive radiotherapy if complete removal is not feasible, to prevent local recurrence.<sup>6–8</sup> This condition is rarely diagnosed before surgery, and is often resected surgically as an aneurysm. When, instead of a common aneurysm, a saccular aneurysm adherent to the surrounding tissue (i.e., an inflammatory aneurysm) is suspected, it is important to remove the aneurysm en bloc with the surrounding tissue. We used a prosthetic graft as a bypass graft for carotid

artery reconstruction. However, we speculate that if the size of an autologous vein matches that of the carotid artery, use of an autologous vein would avoid graft occlusion, achieve long-term patency, and prevent cerebral complications. Appropriate use of steroids is important to control the inflammation. This case highlights the fact that carotid aneurysm caused by an intramural leiomyosarcoma can be successfully treated by surgical resection.

#### Declaration of conflicting interests

The author(s) declared no potential conflicts of interest with respect to the research, authorship, and/or publication of this article.

#### Funding

The author(s) received no financial support for the research, authorship, and/or publication of this article.

#### References

1. Mikami Y, Manabe T, Lie JT, Sakurai T and Endo K. Intramural sarcoma of the carotid artery with adventitial inflammation and fibrosis resembling inflammatory aneurysm. *Pathol Internat* 1997; 47: 569–574.
2. General Rules for Clinical and Pathological Studies on Malignant Soft Tissue Tumors: The JOA Committee of Tumors, Japan, 3rd edition. 2002:132–134.
3. Giangola G, Migaly J, Crawford B, Moskowitz P and Sebenick M. Leiomyosarcoma of the subclavian artery. *J Vasc Surg* 1995; 22: 496–500.
4. Caldarelli GF, Barellini L, Faviana P and Guerra M. Leiomyosarcoma of the popliteal artery: case report and review of the literature. *J Vasc Surg* 2003; 37: 206–209.
5. Kevorkian J and Cento DP. Leiomyosarcoma of large arteries and veins. *Surgery* 1973; 73: 390–400.
6. Gustafson P, Willén H, Baldetorp B, Fernö M, Akerman M and Rydholm A. Soft tissue leiomyosarcoma: a population-based epidemiologic and prognostic study of 48 patients, including cellular DNA content. *Cancer* 1992; 70: 114–119.
7. van Doorn R, Gallee MP, Hart A, et al. Resectable retroperitoneal soft tissue sarcomas. The effect of extent of resection and postoperative radiation therapy on local tumor control. *Cancer* 1994; 73: 637–642.
8. Malone MD, Kerr K, Kavanah M and Menzoian JO. Primary leiomyosarcoma of the abdominal aorta. *J Vasc Surg* 1996; 24: 487–493.
9. Merchant W, Calonje E and Fletcher CD. Inflammatory leiomyosarcoma: a morphological subgroup within the heterogeneous family of so-called inflammatory malignant fibrous histiocytoma. *Histopathology* 1995; 27: 525–532.