

Henoch-Schönlein purpura from vasculitis to intestinal perforation: A case report and literature review

Butsabong Lerkvaleekul, Suporn Treepongkaruna, Pawaree Saisawat, Pornsri Thanachatchairattana, Napat Angkathunyakul, Nichanan Ruangwattanapaisarn, Soamarat Vilaiyuk

Butsabong Lerkvaleekul, Soamarat Vilaiyuk, Division of Rheumatology, Department of Pediatrics, Faculty of Medicine Ramathibodi Hospital, Mahidol University, Bangkok 10400, Thailand

Suporn Treepongkaruna, Division of Gastroenterology, Department of Pediatrics, Faculty of Medicine Ramathibodi Hospital, Mahidol University, Bangkok 10400, Thailand

Pawaree Saisawat, Division of Nephrology, Department of Pediatrics, Faculty of Medicine Ramathibodi Hospital, Mahidol University, Bangkok 10400, Thailand

Pornsri Thanachatchairattana, Division of Pediatric Surgery, Department of Surgery, Faculty of Medicine Ramathibodi Hospital, Mahidol University, Bangkok 10400, Thailand

Napat Angkathunyakul, Department of Pathology, Faculty of Medicine Ramathibodi Hospital, Mahidol University, Bangkok 10400, Thailand

Nichanan Ruangwattanapaisarn, Department of Diagnostic and Therapeutic Radiology, Faculty of Medicine Ramathibodi Hospital, Mahidol University, Bangkok 10400, Thailand

Author contributions: Lerkvaleekul B designed the report and collecting data; Lerkvaleekul B and Vilaiyuk S participated in patient care and writing the manuscript; Treepongkaruna S, Saisawat P, Thanachatchairattana P, Angkathunyakul N, and Ruangwattanapaisarn N participated in patient care and editing the manuscript; Angkathunyakul N provided the histology and pathology images; all authors have read and approved the final manuscript.

Institutional review board statement: This report was reviewed and approved by the Ramathibodi Hospital Institutional Review Board.

Informed consent statement: The legal guardian of the study participant provided informed written consent prior to study enrollment.

Conflict-of-interest statement: All authors declare that they have no conflicts of interest.

Open-Access: This article is an open-access article which was selected by an in-house editor and fully peer-reviewed by external reviewers. It is distributed in accordance with the Creative Commons Attribution Non Commercial (CC BY-NC 4.0) license, which permits others to distribute, remix, adapt, build upon this work non-commercially, and license their derivative works on different terms, provided the original work is properly cited and the use is non-commercial. See: <http://creativecommons.org/licenses/by-nc/4.0/>

Manuscript source: Unsolicited manuscript

Correspondence to: Soamarat Vilaiyuk, MD, Assistant Professor, Chief, Division of Rheumatology, Department of Pediatrics, Faculty of Medicine, Ramathibodi Hospital, Mahidol University, 270 Rama VI road, Ratchathewi, Bangkok 10400, Thailand. soamarat21@hotmail.com
Telephone: +66-2-2012865
Fax: +66-2-2011494

Received: March 28, 2016

Peer-review started: March 29, 2016

First decision: April 14, 2016

Revised: May 7, 2016

Accepted: May 21, 2016

Article in press: May 23, 2016

Published online: July 14, 2016

Abstract

Henoch-Schönlein purpura (HSP) is generally a self-limited vasculitis disease and has a good prognosis. We report a 4-year-old Thai boy who presented with palpable purpura, abdominal colicky pain, seizure, and eventually developed intestinal ischemia and perforation despite adequate treatment, including corticosteroid and intravenous immunoglobulin therapy. Imaging modalities, including ultrasonography and contrast-enhanced computed tomography, could not detect intestinal ischemia prior to perforation. In this patient, we also postulated that vasculitis-induced mucosal

ischemia was a cause of the ulcer, leading to intestinal perforation, and high-dose corticosteroid could have been a contributing factor since the histopathology revealed depletion of lymphoid follicles. Intestinal perforation in HSP is rare, but life-threatening. Close monitoring and thorough clinical evaluation are essential to detect bowel ischemia before perforation, particularly in HSP patients who have hematochezia, persistent localized abdominal tenderness and guarding. In highly suspicious cases, exploratory laparotomy may be needed for the definite diagnosis and prevention of further complications.

Key words: Henoch-Schönlein purpura; Corticosteroids; Vasculitis; Intestinal perforation; Bowel ischemia; Peritonitis

© **The Author(s) 2016.** Published by Baishideng Publishing Group Inc. All rights reserved.

Core tip: Henoch-Schönlein purpura (HSP) with intestinal perforation during the course of corticosteroid treatment was a rare condition. We report a HSP patient with vasculitis-induced mucosal ischemia, eventually leading to ulcer and intestinal perforation. No imaging modality could detect bowel ischemia before perforation. Histopathology of resected bowel also suggested that high-dose corticosteroids might be a contributing factor to intestinal perforation in this patient. Early treatment by surgical resection of ischemic bowel can prevent intestinal perforation and peritonitis, which are life-threatening complications.

Lerkvaleekul B, Treepongkaruna S, Saisawat P, Thanachathairattana P, Angkathunyakul N, Ruangwattanapaisarn N, Vilaiyuk S. Henoch-Schönlein purpura from vasculitis to intestinal perforation: A case report and literature review. *World J Gastroenterol* 2016; 22(26): 6089-6094 Available from: URL: <http://www.wjgnet.com/1007-9327/full/v22/i26/6089.htm> DOI: <http://dx.doi.org/10.3748/wjg.v22.i26.6089>

INTRODUCTION

Henoch-Schönlein purpura (HSP) is the most common childhood vasculitis disorder and is characterized by palpable purpura, arthritis or arthralgia, abdominal colicky pain, and nephritis. It is multi-systemic small vessel vasculitis, 50%-80% of which typically involves the gastrointestinal tract (GI), causing diffuse colicky pain due to submucosal or subserosal hemorrhage and edema. This GI disease is generally benign and has a good response to corticosteroid therapy in most cases. However, severe complications such as intussusception, massive GI bleeding, and intestinal perforation can occur. HSP-associated intestinal perforation is a rare complication but it is life-threatening and mortalities have been reported^[1]. We present here a pediatric patient with severe HSP who developed intestinal

ischemia and perforation without intussusception despite early and adequate corticosteroid therapy.

CASE REPORT

A 4-year-old Thai boy was referred to our hospital due to persistent severe abdominal pain and seizure. He had been hospitalized at a private hospital due to colicky abdominal pain and palpable purpura for two days prior to admission. On admission, the abdomen was soft on palpation and not tender. Furthermore, there was palpable purpuric rash on both legs. His CBC revealed hemoglobin 125 g/L, WBC $11.4 \times 10^9/L$, platelet $501 \times 10^9/L$. ESR was 14 mm/h. Kidney function was normal; BUN was 1.99 mmol/L, Creatinine was 23 $\mu\text{mol/L}$, and the urinary analysis showed specific gravity 1.020, no protein, no glucose, no blood, no bilirubin, WBC 0-1 cells/HPF, RBC 0-1 cells/HPF. The serum electrolyte showed sodium 132 mmol/L, potassium 4.2 mmol/L, chloride 94 mmol/L, bicarbonate 17.2 mmol/L, and the skin biopsy demonstrated small vessel vasculitis. Therefore, HSP was diagnosed and intravenous methylprednisolone (IVMP) 2 mg/kg per day was started promptly. His abdominal pain had improved after the treatment, however two days later (D5) the pain recurred and was progressive. Abdominal ultrasonography revealed no intussusception. Abdominal computed tomography (CT) showed mild bowel wall edema at duodenum and proximal jejunum. On day six, he developed status epilepticus and alteration of consciousness. He was intubated and put on ventilator support. Antiepileptic drug treatment was started. While he was in an euvoletic state, his serum sodium was 120 mmol/L, urine osmolarity 100 mmol/kg, and serum osmolarity 256 mmol/kg. The etiology of seizure was thought to be hyponatremia due to syndrome of inappropriate antidiuretic hormone. MRI and MRA of the brain revealed no evidence of central nervous system (CNS) vasculitis. CSF fluid analysis was normal. Blood tests for anti-nuclear antibody, anti-double stranded DNA, and C3 were normal. Since CNS vasculitis could not be excluded, one dose of pulse methylprednisolone (MP) 30 mg/kg was commenced. Then he was referred to our hospital for further management. On the first day of presentation in our hospital (D7), his physical examination revealed drowsiness and no abdominal distension or guarding. CBC revealed thrombocytosis ($553 \times 10^9/L$), WBC $10 \times 10^9/L$, and hemoglobin 110 g/L. ESR and CRP were 32 mm/h and 5 mg/L respectively. Urinalysis and serum creatinine level were normal. He subsequently regained consciousness and was extubated after serum sodium returned to normal level. The EEG was normal, therefore antiepileptic drug treatment was discontinued. The purpura faded away and the abdominal pain markedly improved, therefore IVMP was continued at the dose of 2 mg/kg per day. Abdominal pain recurred five days after admission to our hospital (D12) with

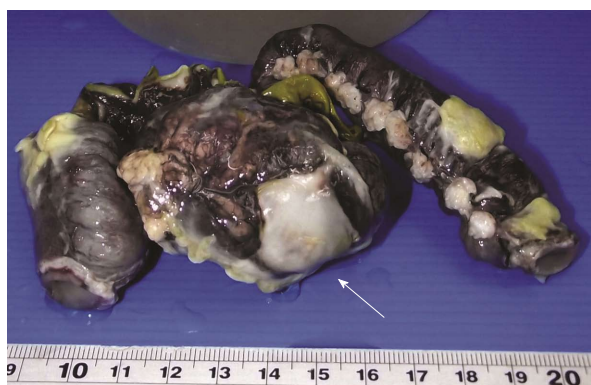


Figure 1 Specimen after fixation revealed a perforated ulcer with fibrofibrinous exudate (arrow).

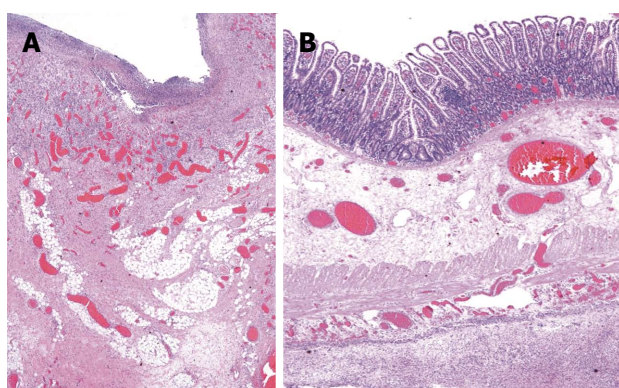


Figure 2 Histopathologic findings (hematoxylin-eosin staining, magnification $\times 40$). A: Base of ulcer revealed inflammation, granulation tissue and fibrosis; B: Remaining ileum showed lymphoid follicle depletion, submucosal and serosal congestion with diffuse peritonitis.

tenderness and voluntary guarding at the right lower quadrant. Abdominal ultrasound revealed diffuse small bowel wall thickening and minimal ascites without intussusception. Corticosteroid resistant HSP was considered, and intravenous immunoglobulin (IVIG) 2 g/kg was initiated. Two days later (D14), he developed hematochezia with tenderness and voluntary guarding at the right lower quadrant. Intestinal ischemia was suspected. A contrast-enhanced CT of the whole abdomen was performed and revealed a long segment of mild circumferential bowel wall thickening with preserved wall enhancement involving jejunum and ileum, but the evidence of bowel ischemia was inconclusive. He was also evaluated by pediatric surgeons and the continuation of medical treatment was suggested. Three days later (D17), he developed signs of peritonitis with abdominal distension, generalized guarding and tenderness. His body temperature was 38.3°C , blood pressure was 100/60 mmHg, pulse rate was 130 beats/min, and respiratory rate was 26 breaths/min. Upright abdominal radiograph demonstrated intraperitoneal free air. An emergency exploratory laparotomy was performed and revealed ischemic ileum of 35 cm at 35 cm proximal to the ileocecal valve and large perforated ulcers, size 3.5

cm \times 1.5 cm, on the ischemic bowel. The pathological examination macroscopically revealed a large perforated ulcer with fibrofibrinous exudates (Figure 1). The histopathology revealed mixed inflammatory cell infiltrate with granulation tissue and fibrosis at the base of ulcer. The remaining bowel showed depletion of lymphoid follicles (Peyer's patch), submucosal and subserosal congestion and diffuse peritonitis (Figure 2). After surgery, his general symptoms gradually improved and abdominal pain resolved. IVMP was switched to oral prednisolone, and then discontinued in week 3. The patient was discharged thirteen days after surgery (D31). He has been well without disease recurrence at the 4 mo follow-up. The summaries of clinical data, investigations, and treatment during the course of disease are shown in Table 1.

DISCUSSION

This patient developed intestinal perforation due to a bowel ischemia-related ulcer at day 17 after the onset of disease despite receiving corticosteroid and IVIG therapy. HSP-associated intestinal perforation is a rare complication with an estimated prevalence of 0.38%^[2]. To the best of our knowledge, only 11 pediatric cases have been reported in the English literature (Table 2). The most common site of perforation is the small intestine, particularly the ileum followed by the jejunum. The pathogenesis of bowel perforation may result from vasculitis-induced thrombosis, leading to ischemia and consequently total necrosis of the bowel wall^[1]. In addition, intussusception and spontaneous bowel perforation can concurrently occur in children with HSP^[3-6].

Treatment of HSP remains controversial. Patients with mild GI disease may recover without any therapy. Corticosteroids have been used in patients with moderate to severe GI involvement as the standard therapy, whereas IVIG is an alternative treatment for steroid-resistant disease^[7,8]. Other reported treatment for refractory GI diseases in HSP were plasma exchange and immunosuppressive drugs, including cyclophosphamide, azathioprine, and cyclosporine^[9]. Early corticosteroid therapy in HSP patients results in better resolution of abdominal pain within 24 h and reduces the risk of persistent renal disease^[8]. In contrast, some studies demonstrated that corticosteroids may increase the risk of bowel perforation through the reduction of mucosal renewal and lymphoid patches^[2]. A presentation of persistent severe abdominal pain despite corticosteroid therapy is uncommon and could be due to refractory disease, intussusception and intestinal ischemia. In our case, we postulated that vasculitis-induced mucosal ischemia was the cause of the ulcer which subsequently perforated, leading to diffuse peritonitis. Based on the histopathological findings of granulation tissue and fibrosis at the base of ulcer, we inferred that the perforation happened some time prior to

Table 1 Summaries of clinical data, investigations, and treatment in this case report

Category	D1-3 8-10/1/15 Private hospital	D5 12/1/15	D6 13/1/15	D7 14/1/15 This hospital	D12 19/1/15	D14 21/1/15	D17 24/1/15	D31 7/2/15
Symptoms	Intermittent abdominal pain, purpuric rash	Abdominal pain progressed	Seizure	Regained consciousness, abdominal pain improved, purpura faded away	Abdominal pain progressed	Persistent abdominal pain with hematochezia	Low grade fever, severe abdominal pain	No abdominal pain, normal appetite
Abdominal signs	Soft, mild tenderness	Generalized voluntary guarding		Soft, not tender	Localized guarding and tenderness at RLQ	Localized guarding and tenderness at RLQ	Distend, generalized guarding	Soft, not tender
Investigations		US - no intussusception	Hyponatremia MRI/MRA - no vasculitis, CSF fluid - normal	Normal EEG	US - Diffuse small bowel wall thickening, minimal ascites, no intussusception	Radiograph - no free air, CT - bowel wall thickening, normal homogeneous enhancement	Radiograph - intraperitoneal free air	
IVMP (mg/kg/d)	2	1	30	2	2	2	2	Switch to oral prednisolone
Treatment		Nexium, sucralfate	ET tube, 3% NaCl, Keppra, Refer	Extubation, off Keppra	NPO, IVIG 2 gm/kg/dose	NPO	NPO, ATB, exploratory laparotomy	

RLQ: Right lower quadrant; US: Ultrasonography; CT: Computerized tomography; EEG: Electroencephalogram; IVIG: Intravenous immunoglobulin; IVMP: Intravenous methylprednisolone; NPO: Nothing by mouth; ATB: Antibiotic; ET: Endotracheal; NaCl: Sodium chloride.

surgery. However, the exact time of perforation cannot be accurately estimated. It is likely that he had concealed bowel perforation, masking the symptoms and signs and leading to a delay in detecting the bowel perforation. We also speculated that high-dose corticosteroid treatment was a contributing factor due to reducing mucosal lymphoid follicles (Peyer's patches) and compromising mucosal renewal and healing.

Early detection of intestinal ischemia is crucial for early surgical resection. Delayed diagnosis can result in intestinal perforation and peritonitis which are severe and life-threatening complications. Unfortunately, the signs and symptoms of intestinal ischemia are not specific, ranging from decreased bowel sound, abdominal tenderness, abdominal distension, to hematochezia. Moreover, some patients had transient improvement during the course of disease^[2]. The gold standard investigation for intestinal ischemia is arteriography but it is invasive and difficult to perform in children. CT scan, particularly multidetector computed tomography, is a major investigation in the diagnosis of bowel ischemia. The diagnostic findings in CT scan include decreased or absent bowel wall enhancement and intramural gas in the bowel wall, however, these findings are found infrequently. Frequent findings are thickening of intestinal wall, dilatation of lumen, and intra-abdominal fluid, which cannot be differentiated from other diseases^[10]. Therefore, bowel ischemia cannot be excluded based on the absence of intramural gas in the bowel wall

from a contrast-enhanced CT scan, as seen in this patient. A plain abdominal radiograph is useful only in cases of perforation but it could not detect bowel ischemia. Abdominal ultrasound is more frequently used to identify other abdominal pathology, such as intussusception and bowel perforation. However, this technique is limited if the patient has a large amount of air in the bowel loops. Ultrasonography may be useful in the late phase of ischemic bowel by demonstrating bowel wall thickening, a fluid-filled lumen, decreased or absent bowel movement, and extra-luminal fluid^[11]. Since bowel perforation can occur at 1 to 4 wk after initial presentation^[1,6,9-15], close observation and frequent physical examination are essential for the early detection of bowel ischemia, especially when the patients have hematochezia, persistent localized abdominal tenderness, and guarding. Finally, in highly suspicious patients, exploratory laparotomy may be needed for the definite diagnosis and treatment of intestinal ischemia and bowel perforation.

In conclusion, HSP is generally a self-limited disease and rarely requires surgical intervention. Corticosteroid therapy is indicated in moderate to severe GI involvement. Persistent severe abdominal pain after initiating corticosteroid therapy is uncommon and physicians should be concerned about GI complications. Bowel ischemia and perforation are rare but life-threatening conditions. Therefore, early diagnosis by clinical evaluation and proper investigations, and prompt surgical treatment are

Table 2 The characteristics and outcome in pediatric patients with Henoch-Schönlein purpura associated-intestinal perforation

Ref.	Age (yr)	Sex	Interval between the onset of symptoms and perforation	Location of the perforation	Associated findings	Treatment before perforation	Symptoms before perforation	Reason for surgery	Outcome
Choong <i>et al</i> ^[1]	5.0	M	16 d	Ileum	Intussusception (ileocolic)	Prednisolone	Fever	Peritonitis	Survive
Shiohama <i>et al</i> ^[6]	7.0	M	15 d	Distal ileum	No	Prednisolone	Melena	Subphrenic free air	Survive
	11.0	M	11 d	Jejunum and ileum	No	Prednisolone	Melena, hematemesis	Abdominal rigidity	Survive
Başaran <i>et al</i> ^[9]	4.5	M	> 15 d	Ileum	Intussusception (ileoileal)	NA	NA	Free air below the right diaphragm	Death
	8.5	M	> 10 d	Distal ileum	Small bowel adhesions	Prednisolone	NA	Free air in peritoneal cavity	Death
Blachar <i>et al</i> ^[10]	5.0	M	28 d	Distal ileum	Intussusception (jejunojejunal)	Hydrocortisone	Hematochezia, hematemesis, fever	Generalized peritonitis	Survive
Reginelli <i>et al</i> ^[11]	4.0	F	19 d	Ileum	Bowel necrosis	Cortisol hemisuccinate	Melena, fever	Peritonitis	Survive
Rodriguez-Erdmann <i>et al</i> ^[12]	5.0	M	> 12 d	Proximal ileum	Intussusception (ileocolic)	Prednisolone	Fever	Abdominal rigidity	Survive
Law <i>et al</i> ^[13]	3.0	M	4 wk	Ileum	Ileal stricture	Prednisolone	Fever	Pneumoperitoneum	Survive
Yigiter <i>et al</i> ^[14]	13.0	M	7 d	Ileum	Ileal necrosis	Prednisolone	Bile-stained vomiting, bloody stools	Peritonitis	Survive
Wang <i>et al</i> ^[15]	5.0	F	22 d	Terminal ileum	Intestinal necrosis, and adhesion	Broad spectrum antibiotics	Abdominal bulge	Abdominal rigidity	Death
This case	4.0	M	21 d	Ileum	Intestinal ischemia, necrosis	IVMP, IVIG	Hematochezia, RLQ pain and guarding	Subphrenic free air	Survive

NA: Not available; IVMP: Intravenous methylprednisolone; IVIG: Intravenous immunoglobulin; RLQ: Right lower quadrant.

necessary for decreasing morbidity and mortality in these patients.

ACKNOWLEDGMENTS

The authors thank Dr. Mahipathorn Chinnapha and Adam Dale, a native speaker of English with former journalism experience now working as an English language Instructor at IGenius Language Institute for proofreading the English.

COMMENTS

Case characteristics

A 4-year-old Thai boy, who was diagnosed with Henoch Schönlein purpura (HSP), had persistent severe abdominal pain despite receiving corticosteroid therapy.

Clinical diagnosis

Physical examination revealed abdominal distention, localized guarding and tenderness.

Differential diagnosis

Gastrointestinal vasculitis from refractory HSP, intussusception, intestinal

ischemia.

Laboratory diagnosis

Acute phase reactants were elevated.

Imaging diagnosis

Upright abdominal radiograph demonstrated intraperitoneal free air.

Pathological diagnosis

A large perforated ulcer with fibrofibrinous exudates and the remaining bowel showed depletion of lymphoid follicles (Peyer's patch), submucosal and subserosal congestion and diffuse peritonitis.

Treatment

Exploratory laparotomy with ileal resection and end to end ileoileoanastomosis.

Related reports

HSP with intestinal perforation is a rare condition. To the best of our knowledge, only 11 pediatric cases have been reported in the English literature. The literature reports showed that bowel perforation can occur 1 to 4 wk after initial presentation.

Term explanation

Syndrome of inappropriate antidiuretic hormone secretion is the condition that causes increased secretion or enhanced antidiuretic hormone, resulting in

excess fluid in the body and leading to hyponatremia.

Experiences and lessons

Despite adequate corticosteroid therapy and non-specific findings in the abdominal computed tomography, intestinal ischemia could not be excluded especially in HSP patients with hematochezia, persistent severe abdominal pain and localized guarding.

Peer-review

This is a very interesting case report and review of the literature. The authors did a very nice job of presenting all of the pertinent information from the case. Additionally, the discussion was well-balanced and provided needed information. The table and figures were also appropriate for the case and manuscript. Even if the manuscript doesn't present important new methods or novel findings, it reminds pediatricians and gastroenterologists that close observation and frequent physical examination are essential for the early detection of bowel ischemia as possible cause of bowel perforation.

REFERENCES

- 1 **Choong CK**, Beasley SW. Intra-abdominal manifestations of Henoch-Schönlein purpura. *J Paediatr Child Health* 1998; **34**: 405-409 [PMID: 9767498 DOI: 10.1046/j.1440-1754.1998.00263.x]
- 2 **Yavuz H**, Arslan A. Henoch-Schönlein purpura-related intestinal perforation: a steroid complication? *Pediatr Int* 2001; **43**: 423-425 [PMID: 11472592 DOI: 10.1046/j.1442-200X.2001.01417.x]
- 3 **BASU R**. Perforation of the bowel in Henoch-Schonlein purpura. *Arch Dis Child* 1959; **34**: 342-343 [PMID: 13797466 DOI: 10.1136/adc.34.176.342]
- 4 **Lindenauer SM**, Tank ES. Surgical aspects of Henoch-Schönlein's purpura. *Surgery* 1966; **59**: 982-987 [PMID: 5937971]
- 5 **Martinez-Frontanilla LA**, Haase GM, Ernster JA, Bailey WC. Surgical complications in Henoch-Schönlein Purpura. *J Pediatr Surg* 1984; **19**: 434-436 [PMID: 6481588]
- 6 **Shiohama T**, Kitazawa K, Omura K, Honda A, Kozuki A, Tanaka N, Omata A, Ooe K, Suzuki Y. Intussusception and spontaneous ileal perforation in Henoch-Schönlein purpura. *Pediatr Int* 2008; **50**: 709-710 [PMID: 19261128 DOI: 10.1111/j.1442-200X.2008.02716.x]
- 7 **Yang HR**, Choi WJ, Ko JS, Seo JK. Intravenous immunoglobulin for severe gastrointestinal manifestation of Henoch-Schonlein purpura refractory to corticosteroid therapy. *Korean J Pediatr* 2006; **49**: 784-789 [DOI: 10.3345/kjp.2006.49.7.784]
- 8 **Weiss PF**, Feinstein JA, Luan X, Burnham JM, Feudtner C. Effects of corticosteroid on Henoch-Schönlein purpura: a systematic review. *Pediatrics* 2007; **120**: 1079-1087 [PMID: 17974746 DOI: 10.1542/peds.2007-0667]
- 9 **Başaran Ö**, Cakar N, Uncu N, Çelikel BA, Kara A, Cayci FS, Taktak A, Gür G. Plasma exchange therapy for severe gastrointestinal involvement of Henoch Schönlein purpura in children. *Clin Exp Rheumatol* 2015; **33**: S-176-S-180 [PMID: 25436762 DOI: 10.1186/1546-0096-12-S1-P357]
- 10 **Blachar A**, Barnes S, Adam SZ, Levy G, Weinstein I, Precler R, Federle MP, Sosna J. Radiologists' performance in the diagnosis of acute intestinal ischemia, using MDCT and specific CT findings, using a variety of CT protocols. *Emerg Radiol* 2011; **18**: 385-394 [PMID: 21655965 DOI: 10.1007/s10140-011-0965-4]
- 11 **Reginelli A**, Genovese E, Cappabianca S, Iacobellis F, Berritto D, Fonio P, Coppolino F, Grassi R. Intestinal Ischemia: US-CT findings correlations. *Crit Ultrasound J* 2013; **5** Suppl 1: S7 [PMID: 23902826]
- 12 **Rodriguez-Erdmann F**, Levitan R. Gastrointestinal and roentgenological manifestations of Henoch-Schoenlein purpura. *Gastroenterology* 1968; **54**: 260-264 [PMID: 5711909]
- 13 **Law F**, Davidson PM, Robinson M, Stokes KB. Ileal perforation: a late surgical complication of Henoch-Schönlein purpura. *Pediatr Surg Int* 1987; **2**: 187-188 [DOI: 10.1007/BF00185150]
- 14 **Yigiter M**, Bosnali O, Sekmenli T, Oral A, Salman AB. Multiple and recurrent intestinal perforations: an unusual complication of Henoch-Schonlein purpura. *Eur J Pediatr Surg* 2005; **15**: 125-127 [PMID: 15877262 DOI: 10.1055/s-2004-821179]
- 15 **Wang HL**, Liu HT, Chen Q, Gao Y, Yu KJ. Henoch-Schonlein purpura with intestinal perforation and cerebral hemorrhage: a case report. *World J Gastroenterol* 2013; **19**: 2574-2577 [PMID: 23674862 DOI: 10.3748/wjg.v19.i16.2574]

P- Reviewer: Caronna R, Chen JQ, Swanson JR **S- Editor:** Yu J
L- Editor: A **E- Editor:** Ma S





Published by **Baishideng Publishing Group Inc**
8226 Regency Drive, Pleasanton, CA 94588, USA
Telephone: +1-925-223-8242
Fax: +1-925-223-8243
E-mail: bpgooffice@wjgnet.com
Help Desk: <http://www.wjgnet.com/esps/helpdesk.aspx>
<http://www.wjgnet.com>



ISSN 1007-9327



9 771007 932045