



REVISTA BRASILEIRA DE REUMATOLOGIA

www.reumatologia.com.br



Case report

Intracerebral hemorrhage with a favorable outcome in a patient with childhood primary angiitis of the central nervous system



Marco Felipe Silva^a, Ana Raquel Feitosa^a, José A. Paz^b, Nádia Emi Aikawa^{a,c}, Clovis A. Silva^{a,c,*}

^a Pediatric Rheumatology Unit, Faculdade de Medicina, Universidade de São Paulo, São Paulo, SP, Brazil

^b Pediatric Neurology Unit, Faculdade de Medicina, Universidade de São Paulo, São Paulo, SP, Brazil

^c Division of Rheumatology, Faculdade de Medicina, Universidade de São Paulo, São Paulo, SP, Brazil

ARTICLE INFO

Article history:

Received 20 December 2013

Accepted 21 May 2014

Available online 30 November 2015

Keywords:

Childhood primary angiitis

Central nervous system

Vasculitis

Intracerebral hemorrhage

Stroke

ABSTRACT

Childhood primary angiitis of the central nervous system (cPACNS) is a rare inflammatory brain disease of unknown etiology. Of note, brain hemorrhage has been rarely reported in cPACNS patients, generally associated with a delayed clinical diagnosis, or with a diagnosis only at necropsy. We present the case of a boy with cPACNS that previously suffered an ischemic stroke. At the age of 7 years and 10 months, he presented a sudden and severe headache, vomiting and reduction in consciousness level (Glasgow coma scale 7), requiring prompt tracheal intubation. Brain computed tomography demonstrated intraparenchymal hematoma in the right parieto-occipital lobe and a small focus of bleeding in the right frontal lobe, vasogenic edema, herniation of the uncus and a 10 mm deviation to the left from the midline. C-reactive protein (9.2 mg/dL) and von Willebrand factor (vWF) antigen (202%) were elevated. Decompressive craniotomy was performed and methylprednisolone and cyclophosphamide were administered. One week later, the patient had left hemiparesis without other sequelae. Importantly, motor deficits have been improving progressively. Our case reinforces the inclusion of this vasculitis as a differential diagnosis in children and adolescents with CNS hemorrhage.

© 2014 Elsevier Editora Ltda. This is an open access article under the CC BY-NC-ND license (<http://creativecommons.org/licenses/by-nc-nd/4.0/>).

Hemorragia intracerebral com evolução favorável em paciente com angíite primária do sistema nervoso central juvenil

RESUMO

Angíite primária do sistema nervoso central juvenil (APSNCJ) é uma doença inflamatória cerebral rara e de etiologia desconhecida. Hemorragia cerebral tem sido raramente reportada em pacientes com APSNCJ, geralmente associada com atraso diagnóstico, ou com um

Palavras-chave:

Angíite primária na infância

Sistema nervoso central

* Corresponding author.

E-mail: clovisaasilva@gmail.com (C.A. Silva).

<http://dx.doi.org/10.1016/j.rbre.2014.05.007>

2255-5021/© 2014 Elsevier Editora Ltda. This is an open access article under the CC BY-NC-ND license (<http://creativecommons.org/licenses/by-nc-nd/4.0/>).

Vasculite
Hemorragia intracerebral
Acidente vascular encefálico

diagnóstico somente por necrópsia. Relata-se um caso de um paciente do gênero masculino com APSNCJ e que previamente sofreu um acidente vascular cerebral isquêmico. Aos 7 anos e 10 meses de idade, o menino apresentou subitamente cefaleia intensa, vômitos e redução do nível de consciência (escala de coma de Glasgow 7), requerendo imediata intubação traqueal. Uma tomografia computadorizada cerebral demonstrou hematoma intraparenquimatoso no lobo parieto-occipital direito e um pequeno foco de sangramento no lobo frontal direito, edema vasogênico, herniação do úncus e um desvio de 10 mm da linha média para a esquerda. A proteína C-reativa (9.2 mg/dL) e o fator antígeno de von Willebrand (202%) estavam elevados. Foi realizada uma craniotomia descompressiva, seguida pela administração de metilprednisolona e ciclofosfamida. Transcorrida uma semana, o paciente apresentava hemiparesia esquerda, sem outras sequelas. É digno de nota que o déficit motor tem melhorado progressivamente. Nosso caso reforça a inclusão dessa vasculite como diagnóstico diferencial em crianças e adolescentes com hemorragia do sistema nervoso central.

© 2014 Elsevier Editora Ltda. Este é um artigo Open Access sob uma licença CC BY-NC-ND (<http://creativecommons.org/licenses/by-nc-nd/4.0/>).

Introduction

Vasculitides are characterized by inflammation and necrosis of endothelium.¹ They can affect blood vessels of any organ and system, including the central nervous system (CNS). CNS vasculitis most often is secondary to an underlying condition, such as infectious, neoplastic, vascular, metabolic or inflammatory disorders, but it also can be idiopathic.^{2,3}

Of note, childhood primary angiitis of the CNS (cPACNS) is a rare inflammatory brain disease of unknown etiology that occurs in previously healthy children. It has protean clinical manifestations, such as seizures, cognitive dysfunction, behavior changes, headaches, neurologic deficits and strokes.³

Ischemic stroke seems to occur more often than hemorrhagic events, which are seldom described in the literature. As far as we are concerned, only seven cases were reported regarding hemorrhagic stroke and cPACNS in the literature, most of which had delayed clinical or necropsy diagnosis.^{1,4-8}

We describe a patient with cPACNS and intracerebral hemorrhage submitted to prompt drainage and immunosuppressive therapy with good prognosis.

Case report

At the age of 7 years and 2 months, a boy presented intense headache during about 5 minutes with spontaneous improvement. In the next twenty-four hours, he had labial commissure deviation to the right side and left hemiparesis, being hospitalized in another hospital. Laboratory exams were: hemoglobin 12.7 g/L, hematocrit 36%, white blood cell count 10,300/mm³ (neutrophils 39%, lymphocytes 52%, monocytes 5% and eosinophils 4%), platelets 300,000/mm³, urea 30 mg/dL (normal range 10-50), creatinine 0.53 mg/dL (normal range 0.32-0.60), C-reactive protein (CRP) 1.1 mg/dL (normal < 5), erythrocyte sedimentation rate (ESR) 7 mm/1st hour (normal range 0-20) and activated partial thromboplastin time 27.2 s, International Normalized Ratio (INR) 1.1. Homocysteine levels were 5.5 micromol/L (normal range 5-15), total cholesterol 176 mg/dL (normal < 200), low-density lipoprotein

cholesterol 112 mg/dL (normal < 100), high-density lipoprotein cholesterol 49 mg/dL (normal > 40) and triglycerides 79 mg/dL (normal < 150). Brain magnetic resonance imaging (MRI) showed ischemic areas in the right middle cerebral artery territory, characterized by subcortical foci of restricted diffusion in the nucleocapsular region, whereas carotid and vertebral magnetic resonance angiography, conventional angiography and carotid Doppler ultrasound were unremarkable, as well as cerebrospinal fluid analysis. Immunological tests were positive for antinuclear antibodies (ANA) 1:80 (fine dense speckled pattern) and negative for other serum antibodies: anti-double stranded DNA (anti-dsDNA), anti-Sm, anti-RNP, anti-Ro, anti-La, anticardiolipin IgM, anticardiolipin IgG, lupus anticoagulant, anti-β₂-glycoprotein-1 and antineutrophil cytoplasmic antibodies. Urinalysis was normal, and blood culture was negative. Protein C (115%), protein S (126%) and factor VIII (87%) activities were within the normal range. Factor V Leiden mutation and prothrombin gene polymorphism were both absent. Aspirin (5.0 mg/kg/day) was introduced, and after 4 months of rehabilitation physiotherapy, complete recovery of the motor deficits was achieved and aspirin was withdrawn. At the age of 7 years and 8 months, he returned asymptomatic in an outpatient visit, bringing a new brain MRI that revealed encephalomalacia in the right nucleocapsular region and leptomeningeal enhancement in the left precentral sulcus, left central sulcus, right occipital sulcus, sphenoid portion of the right Sylvian fissure and inferior aspect of the cerebellar hemispheres, compatible with CNS angiitis (Fig. 1). Prophylactic aspirin was reintroduced, and he was referred to our University Hospital. At that moment, the patient did not have complaints. He had normal weight and height development. Peripheral artery pulses were palpable, there was no claudication of extremities, and blood pressure was 99 × 65 mmHg, without differences in the limbs. No right-left shunt was observed during echocardiography with microbubbles, CRP was 0.9 mg/dL, and ESR was 11 mm/1st hour. At the age of 7 years and 10 months, he had a sudden and severe headache, vomiting and reduction in consciousness level (Glasgow coma scale 7), requiring prompt tracheal intubation. Urgent brain computed tomography demonstrated intraparenchymal hematoma in

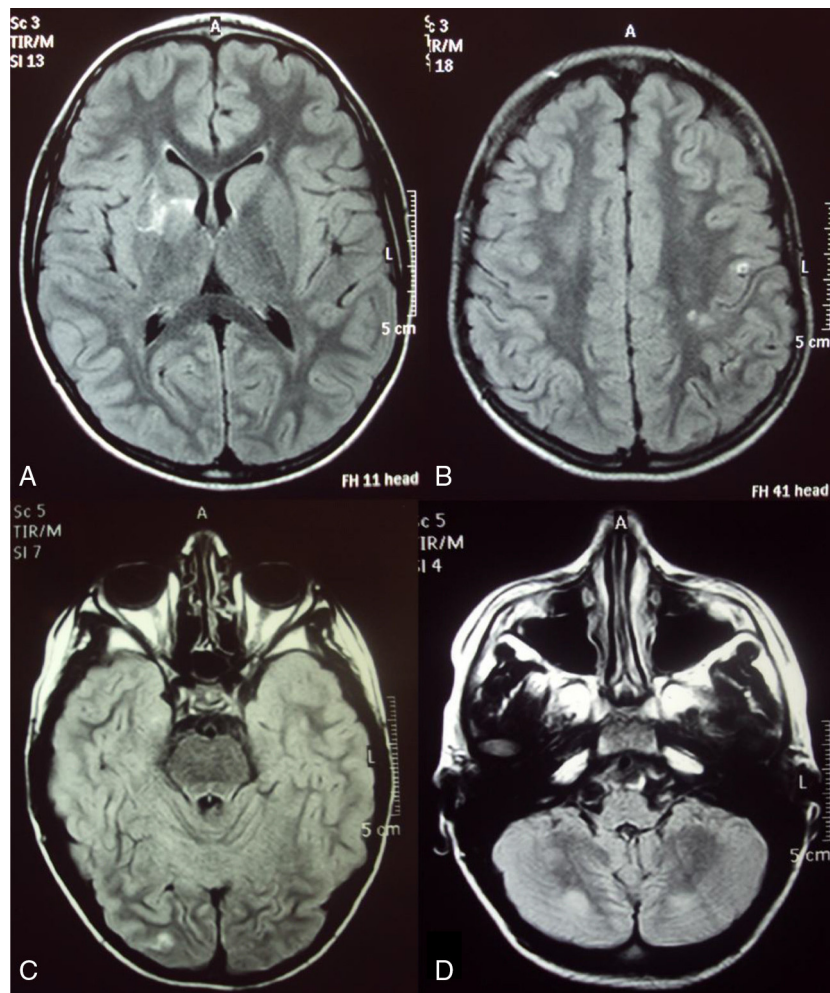


Figure 1 – MRI showing gliosis (A), paramagnetic contrast enhancement in the leptomeningeal compartment (left precentral sulcus, left central sulcus, right occipital sulcus – B and C) and hyperintense lesions involving inferior aspect of the cerebellar hemispheres (D).

the right parieto-occipital lobe (Fig. 2) and a small focus of bleeding in the right front lobe, vasogenic edema, uncal herniation and a 10 mm deviation from the midline to the left. Decompressive craniotomy was promptly performed, and cerebral specimen was obtained for histopathological study. Methylprednisolone pulse therapy for three consecutive days (1.0 g/day) was administered, followed by cyclophosphamide 500 mg/m² of body surface. Laboratory tests showed hemoglobin 13.1 g/L, hematocrit 39.7%, white blood cell count 23,300/mm³ (neutrophils 88%, lymphocytes 5%, monocytes 6% and 1% eosinophils), platelets 352,000/mm³, urea 23 mg/dL, creatinine 0.37 mg/dL, ESR 8 mm/1st hour, activated partial thromboplastin time 0.91 s, and INR was 1.27. The CRP was elevated (9.2 mg/dL), and vWF antigen was 202% (normal range 50-160%). New immunological tests for detection of anticardiolipin IgM, anticardiolipin IgG and lupus anticoagulant were persistently negative in three occasions. Biopsy revealed large quantity of blood clots containing several fragments of cerebral tissue with gliosis, with no evidence of active vasculitis. After a week of hospitalization, he still had left hemiparesis, but no other sequelae; he was discharged with prednisone

2 mg/kg/day. One month after the neurosurgery, prednisone was tapered to 1.5 mg/kg/day, and a new dose of cyclophosphamide 500 mg/m² was administered. The vWF antigen was 108%, and ESR, 5 mm/1st hour. Importantly, motor deficits are progressively improving, with very light left hemiparesis and left hemianopsia, without apparent cognitive dysfunction.

Discussion

We describe herein a case of cPACNS that presented hemorrhagic event with a favorable outcome after prompt drainage and immunosuppressive therapy. The association of cPACNS and hemorrhagic stroke has been reported only in seven cases in the literature, mostly with poor outcome associated with death or severe disabilities.^{1,4-8}

cPACNS shows inflammation only in CNS vessels, without involvement of other organs and systems. Moreover, this illness is not associated with secondary CNS vasculitis, caused by infection, other inflammatory diseases, vascular, metabolic and neoplastic etiologies.

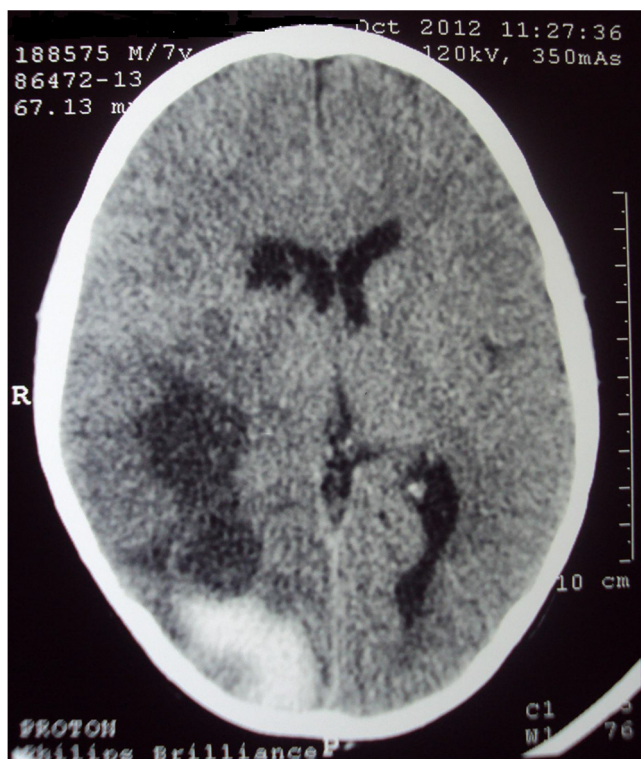

Figure 2 – Intraparenchymal hematoma in the right parieto-occipital lobe.

Of note, cPACNS is diagnosed according to Calabrese criteria: acquired unexplained neuropsychiatric deficit, classic angiographic or histopathologic features of CNS angiitis and no evidence of systemic vasculitis.³ Recently, it has been proposed two clinical subdivisions for this disorder: small vessel vasculitis (SV-cPACNS) or angiography-negative cPACNS and large and medium-sized vessel vasculitis, also known as angiography-positive cPACNS.²

Approximately 30% of biopsies performed in children with suspected SV-cPACNS were negative.² The first choice to brain biopsy in this population is in non-dominant frontal lobe. The absence of vasculitis observed in the histologic findings of our patient might be explained by a sample of inadequate location at the edge of the hematoma with consequent gliosis predominance, probably due to the emergency neurosurgical procedure.

MRI is an available tool to identify lesions of active SV-cPACNS.² Although there is no pathognomonic radiologic finding, patients with angiography-negative c-PACNS usually exhibit multifocal lesions affecting more than one cerebral vessel territory.⁹ Indeed, Benseler et al. reported four cases of biopsy-confirmed SV c-PACNS and all of the patients had multifocal injuries involving both gray and white matter,⁹ similarly as observed in the present case.

Regarding clinical manifestations, SV-cPACNS has been reported with seizures, cognitive dysfunction, headaches and rarely with intracranial hemorrhage.¹⁰ Large- and medium-sized vessels subtype shows predominantly motor deficits and speech changes, and positive angiography is the fundamental tool for its classification.¹⁰

Interestingly, the inflammatory markers, such as CRP and ESR, may help to assess disease activity, although these exams may oscillate during the disease course. The vWF antigen has been described as a reliable biomarker for patients with active systemic vasculitis. It is a plasma protein synthesized by megakaryocytic and an endothelial cell that reaches higher levels in the presence of damaged or inflamed vascular endothelium.^{2,11} Moreover, increased levels of vWF antigen were reported in 65% of c-PACNS population. Remarkably, these levels decreased significantly after treatment, as observed herein.¹¹

Additional detections of antiphospholipid antibodies were prospectively collected, since these antibodies may fluctuate during the disease course, reaching non-detectable levels at the acute vascular events.¹²

The early neurosurgical treatment in conjunction with immunosuppressant provided favorable outcome for our patient. Indeed, the therapy for SV-cPACNS includes induction with glucocorticoids and intravenous cyclophosphamide during the first six months and subsequent maintenance therapy with mycophenolate mofetil for 18 months.^{2,3}

In conclusion, we reported a favorable prognosis in a SV-cPACNS patient with brain hemorrhage, reinforcing the inclusion of these vasculitis as a differential diagnosis in children and adolescents with CNS hemorrhage.

Conflicts of interest

The authors declare no conflicts of interest.

Acknowledgments

This study was supported by Fundação de Amparo à Pesquisa do Estado de São Paulo – FAPESP (grant #08/58238-4 to CAS), Conselho Nacional de Desenvolvimento Científico e Tecnológico – CNPq (302724/2011-7 to CAS), Federico Foundation to CAS and Núcleo de Apoio à Pesquisa “Saúde da Criança e do Adolescente” da USP (NAP-CriAd). We thank the colleagues of Intensive Care Unit of Centro Médico de Campinas.

REFERENCES

1. Pistracher K, Gellner V, Riegler S, Schöckler B, Scarpatetti M, Kurschel S. Cerebral haemorrhage in the presence of primary childhood central nervous system vasculitis – a review. *Childs Nerv Syst.* 2012;28:1141–8.
2. Cellucci T, Benseler SM. Diagnosing central nervous system vasculitis in children. *Curr Opin Pediatr.* 2010;22:731–8.
3. Iannetti L, Zito R, Bruschi S, Papetti L, Ulgiati F, Nicita F, et al. Recent understanding on diagnosis and management of central nervous system vasculitis in children. *Clin Dev Immunol.* 2012;2012:698327.
4. Gallagher KT, Shaham B, Reiff A, Tournay A, Villablanca JP, Curran J, et al. Primary angiitis of the central nervous system in children: 5 cases. *J Rheumatol.* 2010;28:616–23.
5. Greenan TJ, Grossman RI, Goldberg HI. Cerebral vasculitis: MR imaging and angiographic correlation. *Radiology.* 1992;182:65–72.

6. Kumar R, Wijdicks EF, Brown RD Jr, Parisi JE, Hammond CA. Isolated angiitis of the CNS presenting as subarachnoid haemorrhage. *J Neurol Neurosurg Psychiatry*. 1997;62:649-51.
7. Matsell DG, Keene DL, Jimenez C, Humphreys P. Isolated angiitis of the central nervous system in childhood. *Can J Neurol Sci*. 1990;17:151-4.
8. Nishikawa M, Sakamoto H, Katsuyama J, Hakuba A, Nishimura S. Multiple appearing and vanishing aneurysms: primary angiitis of the central nervous system. Case report. *J Neurosurg*. 1998;88:133-7.
9. Benseler SM, deVeber G, Hawkins C, Schneider R, Tyrrell PN, Aviv RI, et al. Angiography-negative primary central nervous system vasculitis in children: a newly recognized inflammatory central nervous system disease. *Arthritis Rheum*. 2005;52:2159-67.
10. Cellucci T, Tyrrell PN, Sheikh S, Benseler SM. Childhood primary angiitis of the central nervous system: identifying disease trajectories and early risk factors for persistently higher disease activity. *Arthritis Rheum*. 2012;64:1665-72.
11. Cellucci T, Tyrrell PN, Pullenayegum E, Benseler SM. von Willebrand factor antigen – a possible biomarker of disease activity in childhood central nervous system vasculitis? *Rheumatology (Oxford)*. 2012;51:1838-45.
12. Campos LM, Kiss MH, D'Amico EA, Silva CA. Antiphospholipid antibodies and antiphospholipid syndrome in 57 children and adolescents with systemic lupus erythematosus. *Lupus*. 2003;12:820-6.