

## Left Non-dominant Hand Mirror Writing

RECAREDO RODRÍGUEZ

*Speech Clinic of the National Institute of Neurology and Neurosurgery, S.S.A.  
Insurgentes Sur No. 3877, Tlalpan, México, D.F. México*

MARTHA AGUILAR

*Speech Clinic of the National Institute of Neurology and Neurosurgery, S.S.A.  
Insurgentes Sur No. 3877, Tlalpan, México, D.F. México*

AND

GUILLERMO GONZÁLEZ

*Psychology Department of the National Institute of Neurology and Neurosurgery, S.S.A.  
Insurgentes Sur No. 3877, Tlalpan, México, D.F. México*

A 38-year-old right-handed woman, who had suffered a left cerebral hemisphere infarction, was studied. She developed right hemiparesis, motor and sensory aphasia, and left hand mirror writing. All possible brain mechanisms involved in writing, either perceptual or motor, were investigated in search of the one responsible for her mirror writing; however, no abnormality was detected. On examination of the left handwriting, in the directionality of writing tracings as related to the body midline, we detected a lack of inversion of the right handwriting motor patterns—at the moment they are transmitted from the left to the right cerebral hemisphere—implicating a motor rather than a perceptual mechanism.

© 1989 Academic Press, Inc.

Mirror writing is a kind of writing accomplished in exactly the same sequence but in the opposite direction of the normal one (Gaddes, 1980). This type of writing can be reversed by means of a mirror to give an image of normal writing; so this abnormality owes its name to this fact.

The authors thank Dr. Raúl Alvarado Calvillo from the Brain Research Unit of the National Institute of Neurology and Neurosurgery of Mexico City for reviewing the manuscript and for his useful suggestions and comments. Address correspondence and reprint requests to Recaredo Rodriguez, Speech Clinic, National Institute of Neurology and Neurosurgery, S.S.A., Insurgentes Sur No. 3877, Tlalpan, México, D.F., 14410 México.

Mirror writing may be present at two levels of complexity, at single letters, and at word levels (Gaddes, 1980). Mirror writing may also be for script or for manuscript writing, or both. It may be found in left or right handwriting, in the dominant or in the nondominant hand or in both (Kalizhnyuk, 1970). It is also more frequently seen in children than in adults and in left-handed than in right-handed individuals (Gordon, 1920).

Mirror writing in adults has not been frequently reported in medical literature. Leonardo da Vinci, the celebrated genius of the Italian Renaissance (1452–1519) was left-handed; although, later he became ambidextrous. One of the most outstanding features of this great man was that he wrote in complete mirror writing, even his signature was executed in mirror fashion (Verdejo, 1969; La Fay, 1970).

Javal (1906) emphasized that complete reversal of letters direction is the normal written expression for the left-handed. Gordon (1920) found a great percentage of left-handed children among the population of schools for the "deficient" in London, 8% of them were also mirror writers. He thought that something had occurred that interfered with the normal function of the dominant cerebral hemisphere. Sereni (1923) considered that the innervation of the muscles of the left hand would give a motion exactly opposite to that resulting from the comparable innervation applied to the right hand. Orton (1925, 1933) described mirror writing in some slow and subnormal school children, although he did not venture any explanation about its cause.

Critchley (1927) thought that the natural movements of the left hand were the mirror counterpart of those of the right one, and if this tendency were not straightened by the visual memory of the correct orientation of the word, mirror writing would result.

Kalizhnyuk (1970) reported 30 children with cerebral palsy. The author found that mirror writing frequently occurred when the left hand was used to write. Mirror writing with both hands was present in 4 cases. According to the author, his observations indicated that the elements of opticospatial agraphy discovered might be incorporated to Gerstmann's syndrome.

Sunohara, Saku, Kenoshita, and Satoyoshi (1978) reported a case of left-hand mirror writing in a right-handed woman as a result of a focal cerebral lesion in the left parietal region. Mirror writing only lasted for 40 days despite the persistence of the focal cerebral lesion. The authors ascribed left-hand mirror writing to a disturbance of the imagery of Chinese Kanji constructions.

Sato (1979) found six cases of mirror writing among 63 patients with cerebrovascular diseases due to cerebral aneurysms, thrombosis, and arteriovenous malformations. Mirror writing was more frequently found in patients with aneurysms who had undergone surgery than in the other two diseases. The authors thought that mirror writing with the right hand

was caused by an imagery confusion of Kanji constructions and emphasized the importance of distinguishing factors influencing muscle movements from psychological factors when analyzing this problem.

Heilman, Howell, Valenstein, and Rothi (1980) studied a 58-year-old left-handed man who suddenly developed dysarthric speech, right hemiparesis, right hemihypesthesia, difficulty in walking, bilateral extensor plantar responses, mirror reading, and left-hand mirror writing. Mirror writing was variable according to the afferent pathway used; thus, from 11 words verbally presented (dictation), he wrote all of them in mirror fashion, but when copying 13 printed words that contained 60 letters he only wrote one 5-letter word in mirror writing; the remaining 12 words containing 55 letters were written correctly excepting 4 letters which were written with reversed orientation but in normal order. The patient also presented directional confusion concerning the side of the road he would drive along, the way he would open and glance through the pages of a picture book, how he would place the numbers in the dial of a telephone, and how he would run the bases while playing baseball; he did all in a reversed direction. The mirror writing and the directional confusion disappeared within 3 months after the onset of his symptoms.

The authors thought that a reversal of the learned left-to-right scanning process with the availability of mirror engrams induced mirror reading, and that reversal of the normal left-to-right writing pattern with the availability of mirror engrams induced mirror writing.

Tankle and Heilman (1983) examined 88 undergraduate students, 48 right-handers and 40 left-handers, to test their ability to write in mirror fashion. The authors found that the left-handers wrote mirror words faster than the right-handers did with either hand, left-handers made fewer errors than right-handers when using the hand they preferred, and that the left hand was superior to the right one in mirror writing, both in right- and left-handers. The authors thought that these findings were compatible with the hypothesis that the right hemisphere contains mirror engrams to the ones harbored in the left hemisphere or that movements away from the body are more accurate than the ones made toward it.

Complete mirror writing in adults seems to be a rare finding. The authors have observed only two cases of left nondominant hand mirror writing since the aphasia test they use includes writing with both hands as a routine procedure (Rodríguez & Camacho, 1976a). One case is the reported one, and the other was the mother of a family with congenital language apraxia or "dilapidated speech" (Ferry, Hall, & Hicks, 1975).

### CASE REPORT

The subject is a 38-year-old, right-handed female with a sixth-grade primary school education without scholar failure. However a sister reported

that the patient did not like school activities very much, especially writing, where she made many spelling mistakes.

On April 17, 1981, the patient had a cerebral infarction of the left middle cerebral artery secondary to a rheumatic heart disease. As a result the patient developed a moderate sensory and motor aphasia with a right central facial paresis, a right hemiparesis with hyperactive deep tendon reflexes, and a right Babinski's sign. There was also a right hemihypesthesia with good stereognosis and good position sense. A CT scan showed a left subcortical occipitoparietal infarction with an anterior extension involving the striatum and the internal capsule (Fig. 1). One week later, she had shown good spontaneous recovery to the point of being able to walk unaided, had communication with her family, and had greatly improved. There was an orolingual and upper limbs apraxia. The right hemihypesthesia with good stereognosis was still present and there was no visual field defect. The deep tendon reflexes were symmetrical with an equivocal plantar response on the right, and the right central facial paresis had disappeared. She was sent to the National Institute of Cardiology for surgical correction of a mitral valve stenosis. On July 15, 1981, a prosthetic mitral valve was successfully placed.

On returning to the Neurology Institute, 3 months later, the first formal language examination showed that there was a disturbance of the sensory association processes among others, the verbal acoustic, verbal visual, nonverbal visual, and somesthetic sensibilities as well as alteration of speech and writing. Several dysnomias and literal paraphasias were observed in verbal language. There were omissions, substitutions, and transpositions of letters in right handwriting and mild difficulty in reading. Left handwriting showed, besides the above-mentioned abnormalities, a complete mirror writing with a directionality from right to left which persisted even when copying the verbal stimuli permanently displayed (Fig. 2). The patient could read her own mirror writing with the same mild difficulty she had in reading her right normal handwriting.

A severe deficit of recent memory was observed, so that one of the authors (G.G.) applied the Wechsler Memory Scale Form No. 1 which showed a memory quotient of 53, with a visual nonverbal memory of 20% and an acoustic verbal memory of 23% (Wechsler, 1972).

## METHOD AND RESULTS

To accomplish normal handwriting, it is necessary that all cerebral functions and mechanisms depending upon the hand visuomotor circuit work together. These mechanisms involve visual reception and perception, visual association processes mainly with acoustic information, motor handwriting performance which in turn is monitored by visual and auditory mechanisms (Luria, 1966; Johnson & Myklebust, 1967), as well as other higher brain functions such as body image integration (Calanchini &

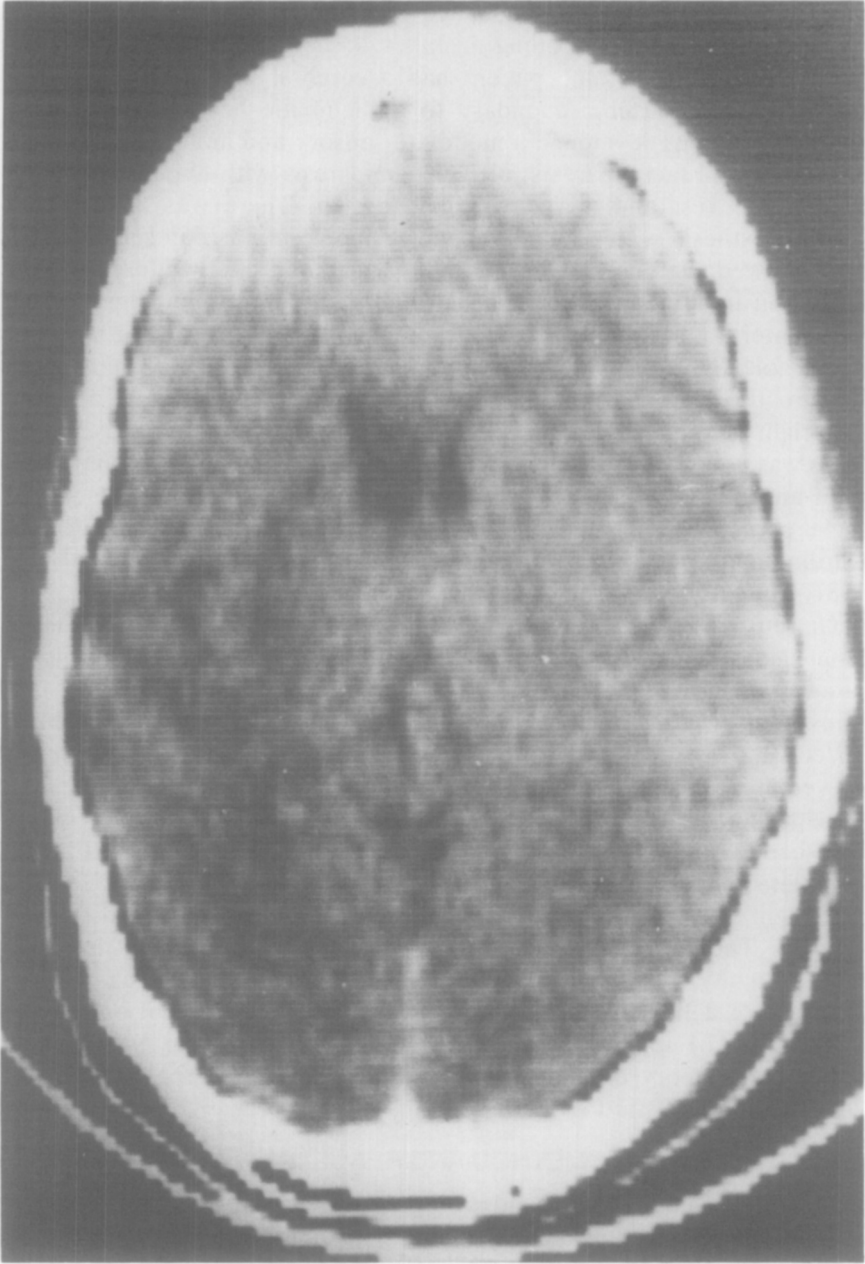

FIG. 1. CT scan showing a left subcortical parieto-occipital infarction with a deep anterior extension.




FIG. 2. Right and left handwriting samples. The right-hand normal writing is in the left column and the left-hand mirror writing is in the right column. The stimuli are words written in boldface type letters on 7.5 by 12.5-cm white cards, which were permanently exposed so that the patient could check visually as many times as needed. The stimuli were goma (eraser), peine (comb), lápiz (pencil), canica (marble), cuchara (spoon), cepillo (brush), gotero (dropper), seguro (safety pin), tornillo (screw), and pirinola (small spinning top). (\*) Occasional visual monitoring in short words; (\*\*) continuous visual monitoring, sometimes letter by letter in long words.

Trout, 1971), recognition of right and left sides of the body (Gaddes, 1980), and visuomotor coordination (Johnson & Myklebust, 1967).

It was thought that the study of all the above-mentioned cerebral functions and mechanisms, as well as the effect of the modification or suppression of some of them, when possible, could provide and aid in understanding the physiopathology of the patient's left-hand mirror writing.

Bearing the above considerations in mind, the following research program was carried out:

- (a) Examination of the visual functions which includes visual acuity, visual fields, visual discrimination, and visuospatial orientation;
- (b) Body image integration and right and left identification;
- (c) Hand-motor performance in right and left handwriting;
- (d) Visuomotor coordination.

### *Visual Functions*

Visual acuity and visual fields were normal. Visual discrimination was examined by one of the authors (M.A.) who applied the Luria Neuropsychological Diagnostic Test with the portion which explores higher visual functions (Christensen, 1974). It was concluded that the visual perception of objects, drawings, and symbols was within normal limits, except when the visual function is mediated by complex intellectual processes such as language.

To examine visuospatial orientation, the patient was asked to guide the examiner (R.R.) from the Institute's main entrance to the medical office where she had been examined previously. This involved going through a series of corridors, going upstairs from the first to the second floor of different buildings, identifying the information desk, the outpatient clinic, and the speech therapist's office, on her way to the examiner's. All this was done without difficulty; thus, it was concluded that the patient had a good visuospatial orientation.

### *Body-Image Integration and Identification of Right and Left Sides of the Body*

Body-image integration was explored through the identification of different segments, right and left, on the patient's own body and on the examiner's. The examination included seven orders according to which she had to cross her body's midline. On 28 items the patient only made one mistake; when asked to point to her right foot, she pointed to her right knee, but corrected immediately.

### *Motor Performance of the Upper Limbs in Right and Left Handwriting*

The features of the patient's right handwriting made identification of different letters easy; however, the linguistic errors previously noticed were again identified. The features of the patient's left handwriting were also easily identified by means of a mirror, making allowance for the lesser skill and firmness of the tracings. There were similar linguistic errors as the ones noted in her right handwriting, which occasionally were exactly the same. The patient wrote PINE, CIPILLO, CIGURO, TORILLO, and COMA, instead of PEINE, CEPILLO, SEGURO, TOR-

NILLO, and GOMA, respectively (which correspond to the English words COMB, BRUSH, SAFETY PIN, SCREW, and ERASER).

### *Visuomotor Coordination*

There was no incoordination in handwriting performance either with the right or the left hand; nevertheless, the left hand was slower than the right since it is the nondominant one.

Because of the negative results so far obtained, it was thought convenient to introduce some modifications in the visual fields aimed at disrupting the spatial relationships between the performing hand and the midline of the visual fields, and the following experimental situations were implemented:

(a) *Right and left handwriting performance with closure of the eye opposite to the performing hand.* In this experimental situation, although the contralateral visual field to the performing hand was eliminated, the spatial relationships of the performing hand and the midline of the visual fields remained unchanged (Figs. 3 and 4). This part of the study included writing using the four afferent pathways considered in the aphasia test, employed by the authors: verbal acoustic (dictation), nonverbal visual (writing the names of the objects shown), verbal visual (copying the names of objects written in boldface type letters on 7.5 by 12.5-cm white cards, exposing the stimuli both momentarily and permanently), and somesthetic (writing the names of the objects palpated with the eyes closed). This experimental situation neither modified the patient's right-hand normal writing, nor her left-hand mirror writing.

(b) *Right and left handwriting performance with closure of the eye ipsilateral to the performing hand.* This experimental situation was intended to force the performing hand to cross the midline of the visual fields and thus modifying the visuospatial relationships between the writing hand and the midline of the visual fields as shown in Figs. 3 and 4. To test this assumption an experiment with 50 adult normal eyesighted subjects was carried out, they were asked to draw an "X" inside of one of the squares of a 5-mm<sup>2</sup> sheet of paper. The "x" was to be drawn at approximately the center of the page under the control of binocular vision. The subjects were asked to close both eyes for a few seconds, to eliminate the fusional vergence reflex. Then they were requested to open just one of the eyes and mark out the most clearly seen square upon the horizontal writing line where the "x" was previously drawn, trying to keep the eye in a relaxed neutral position. After this was accomplished the same operation was carried out with the other eye.

It was found that under conditions of monocular control the macular vision experienced an outward displacement from the visual fields midline, to the right for the right eye and to the left for the left eye. The mean value displacement was of  $36.7 \pm 17.8$  mm for the right eye and 36.8



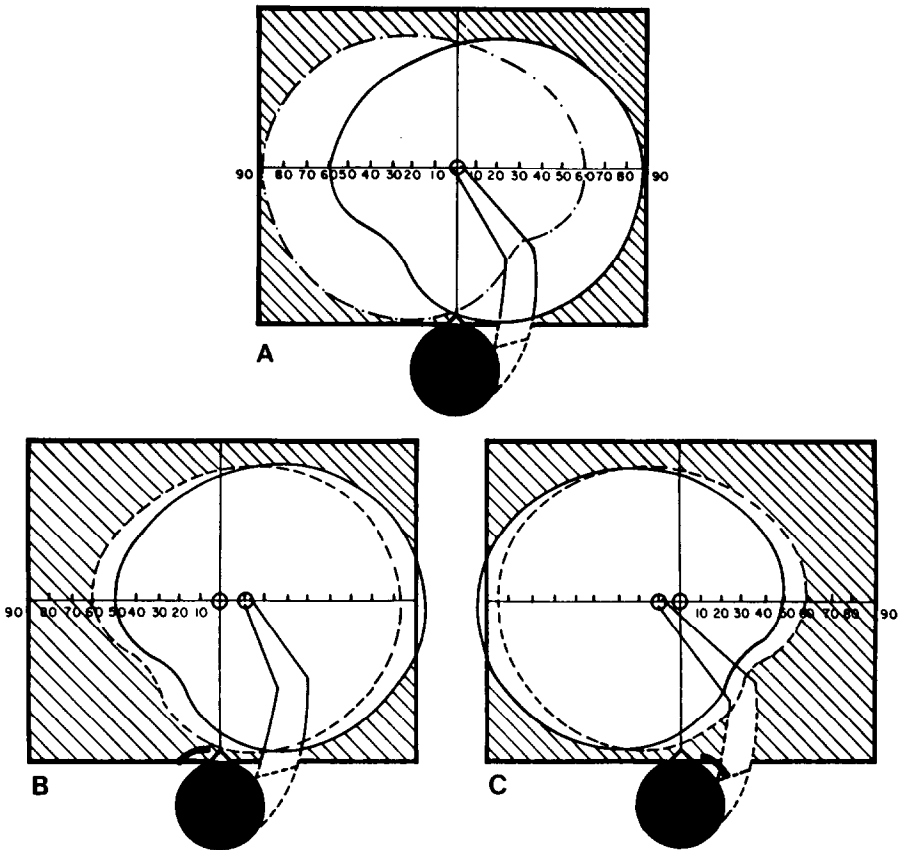


FIG. 3. Three experimental situations in which the right hand is the writing hand. (A) The right hand is writing under binocular vision control. The superimposition of both visual fields is about  $120^\circ$  of arc,  $60^\circ$  to each side of the visual fields midline. The right hand will be writing at the center of this superimposition area where both macular visions are also superimposed. (B) The right hand is writing with closure of the contralateral eye, in this experimental condition the macular vision of the right monocular visual field—according with the clinical experiment summarized in the manuscript—will experience a  $36.7 \pm 17.8$  mm displacement to the right of the visual fields midline. This displacement does not modify the visuospatial relationship between the visual fields midline and the writing hand. (C) The right hand is writing with closure of the ipsilateral eye. In this experimental situation the macular vision of the left monocular visual field will undergo a  $36.8 \pm 19.4$  mm displacement to the left of the visual fields midline. This displacement will force the right hand to cross the visual fields midline to the opposite side thus modifying the visuospatial relationship between the right hand and the visual fields midline. In (B) and (C) the continuous line monocular visual fields correspond to the displaced monocular visual fields after the occlusion of one of the eyes.

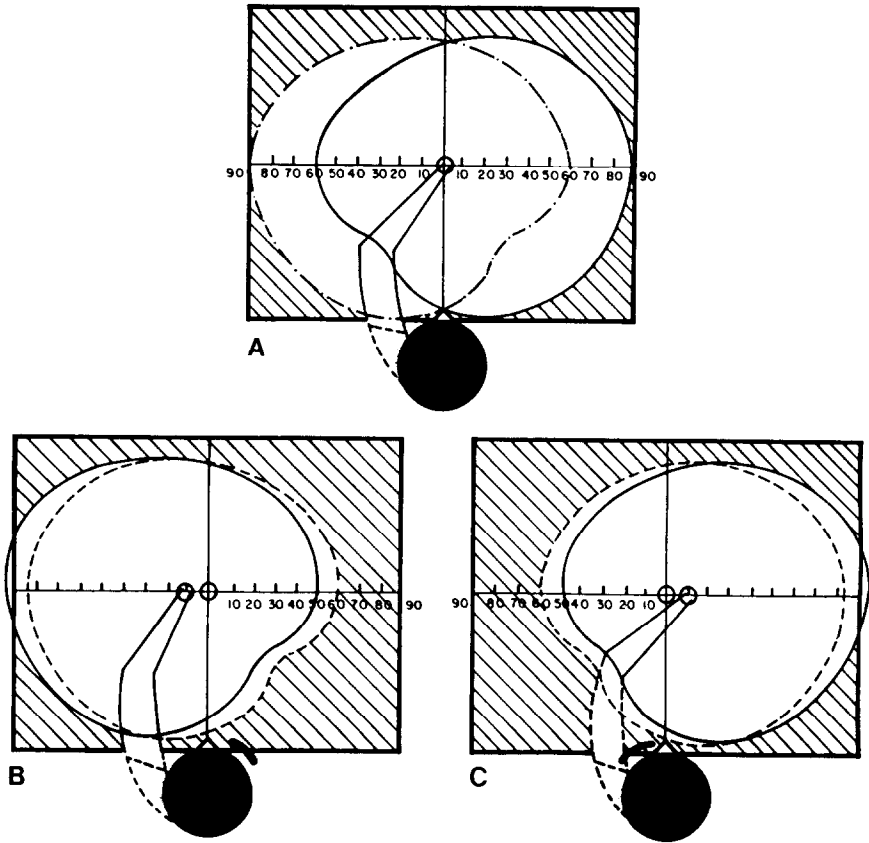


FIG. 4. Same experimental situation depicted in Fig. 3, the only difference is that the writing hand is now the left hand. The experimental situation that will modify the visuospatial relationship between the writing hand and the visual fields midline is the one wherein the occluded eye is the eye ipsilateral to the performing hand. (A) Binocular vision control. (B) Closure of the contralateral eye. (C) Closure of the ipsilateral eye. In (B) and (C) the continuous line monocular visual fields correspond to the displaced monocular visual fields after the closure of one of the eyes.

$\pm 19.4$  for the left eye. Two of the 50 subjects examined had to be excluded—one right-handed and one left-handed—due to the repeated variable responses obtained with one of their eyes.

The authors think that these overall results are in agreement with the assumption postulated by them, in view of the fact that when a subject had to mark out the most clearly seen square with the hand ipsilateral to the occluded eye this hand had to cross the visual fields midline toward the opposite side. Similar results were obtained in three left-handed subjects included in the experimental sample.

This part of the study included the examination of writing employing

as afferent channels the four pathways mentioned in the preceding paragraph. This experimental situation did not affect the patient's mirror writing (Fig. 5).

Because negative results again were obtained in attempting to modify the patient's mirror writing, it was thought useful to explore the effects of eliminating all visual monitoring.

(c) *Right and left handwriting performance with both eyes closed.* In this experimental situation the patient was asked to try to write with both eyes closed to eliminate all visual monitoring, leaving her to be guided only by the somesthetic control. Due to the high degree of difficulty

11 de ENERO de 1984 ~~(Ojo ipsilateral oculto)~~  
 II B. (Estimulo permanentemente expuesto)  
 RXX

goma	goma
(pen)	enig
pluma	pluma
lapis	(cañeta)
cañeta	cañeta
cuchara	cañeta
	cañeta
cepillo	cañeta
gotero	cañeta
seguro	cañeta
tornillos	cañeta
pirinola	

RXX Monitoreo constantemente o medida que cañeta o ves letra por letra

FIG. 5. Right-hand normal writing and left-hand mirror writing: both remained unchanged by the experimental situation which held occluded the eye ipsilateral to the performing hand. The visual verbal stimuli were permanently exposed. Close visual monitoring was observed sometimes letter by letter.

involved in the task to be performed, it was decided to carry out the experiment only through the verbal acoustic pathway. Again, this experimental situation did not modify the patient's mirror handwriting (Fig. 6).

Because of the total failure to identify any neuropsychological mechanism responsible for the patient's mirror writing, it was considered useful to review the motor performance of both hands in writing isolated letters in the material already available, paying special attention to the directionality of the writing movements in relation to the body midline.

Letters written correctly with the right hand were compared with the same letters written in mirror fashion with the left hand, which were the writing modalities presented by the patient. The letters were divided into several segments, for example, letter "a" was divided into three segments as shown by Fig. 7. When this letter is written normally with the right hand, the first segment has a directionality toward the body midline, and the second and third segments have a directionality away from it. The first segment of the same letter in mirror writing with the left hand has a directionality toward the body midline and the second and third segments


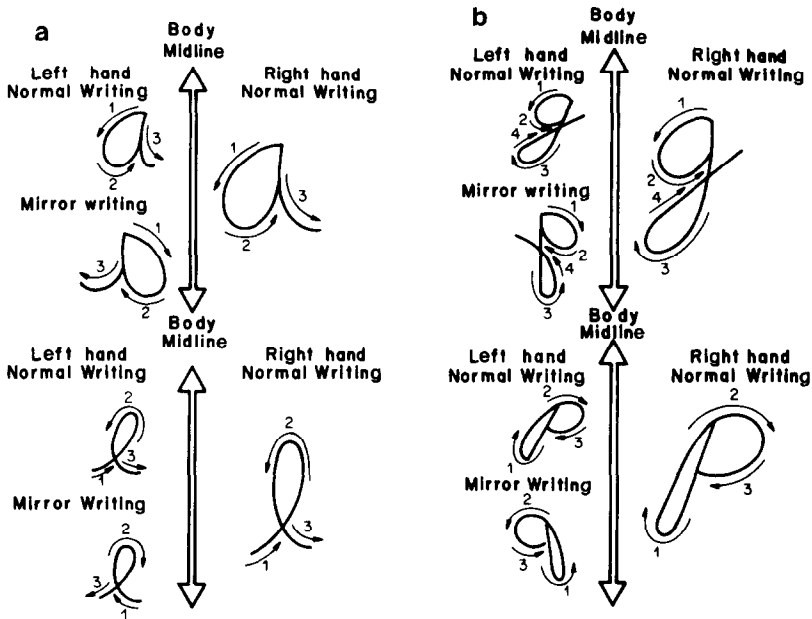


FIG. 6. Experimental situation in which the patient was asked to write with both eyes closed to eliminate all visual monitoring, leaving the patient only aided by somesthetic control. There were no changes either in right-hand normal writing or in left-hand mirror writing. The afferent pathway used was the acoustic verbal one as explained in the text.



FIGS. 7a AND 7b. Letters a, e, g, and p, written in right-hand normal writing, in left-hand normal writing and in left-hand mirror writing. The letters have been divided into three or four segments to show the direction of each segment in relation to the midline of the body represented by a vertical double-headed arrow line. It is observed that the different segments in which the letters have been parceled out follow the same direction in relation to the midline of the body in right-hand normal writing and left-hand mirror handwriting. This means that the motor patterns of the right-hand normal writing have not been reversed in the course of left-hand mirror writing as it is necessary to accomplish left-hand normal writing. For further explanation see the text.

away from it. In other words, the directionality of the three segments in which letter "a" has been divided is the same, in relation to the body midline, in the right hand normal writing than in the left-hand mirror writing. As it can be appreciated the motor patterns of her right hand have not been reversed when the patient executes the left-hand mirror writing; exactly the opposite that happens in normal left handwriting.

The above considerations are also applicable to letters "e," "p," and "g," which can also be divided into three or four different segments as shown in Fig. 7b. In fact, the same comments are valid for all handwritten letters and most of script and boldface type letters.

Besides, it was thought interesting to explore whether this lack of inversion of the hand-motor patterns was also present when copying nonverbal material. To investigate this possibility the patient was asked to reproduce the 10 drawings shown in Fig. 8. Each tracing was presented

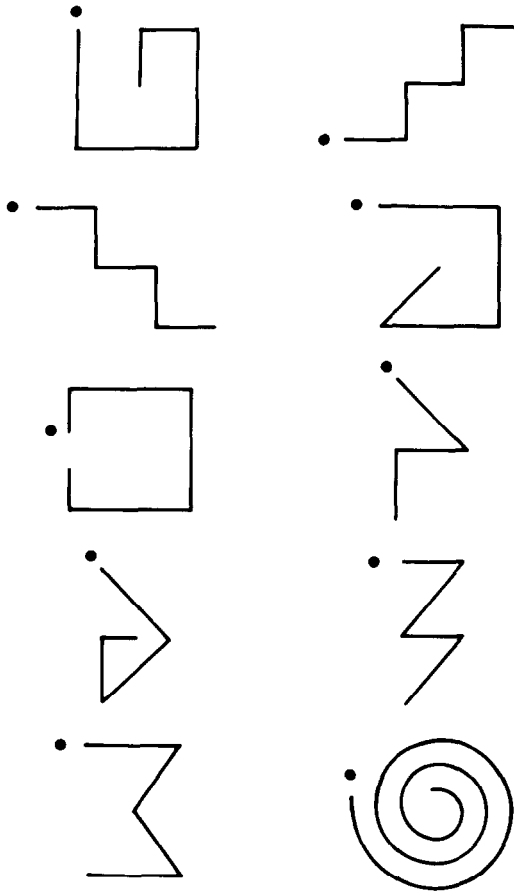


FIG. 8. Ten drawings used in the hand-motor nonverbal task. They were numbered from top to bottom, beginning with left column and ending with the right one. Each drawing has a dot to indicate the starting point.

alone on a 7.5 by 12.5-cm white card with a dot to indicate the starting point.

The patient had to reproduce the drawings first with the right and then with the left hand in four experimental situations: (a) with both eyes open and with the model momentarily—for 3 sec—and then permanently exposed; (b) with closure of the eye contralateral to the performing hand, exposing the model both, momentarily and permanently; (c) with closure of the eye ipsilateral to the performing hand, with the model momentarily and permanently exposed; and (d) with both eyes closed.

The purpose of each one of these experimental situations was the same as when similar experiments were performed with writing.

The patient drew the tracings correctly either with the right or with

the left hand in the four different experimental situations previously described, except with the following mistakes; in drawing with the right hand with both eyes open and with the stimulus permanently exposed, she drew the spiral in clockwise direction instead of the counterclockwise indicated by the model (Fig. 9). She also substituted Drawing 4 with Drawing 8 when working with the stimulus *momentarily exposed* in the following experimental situations: (a) drawing with the left hand with

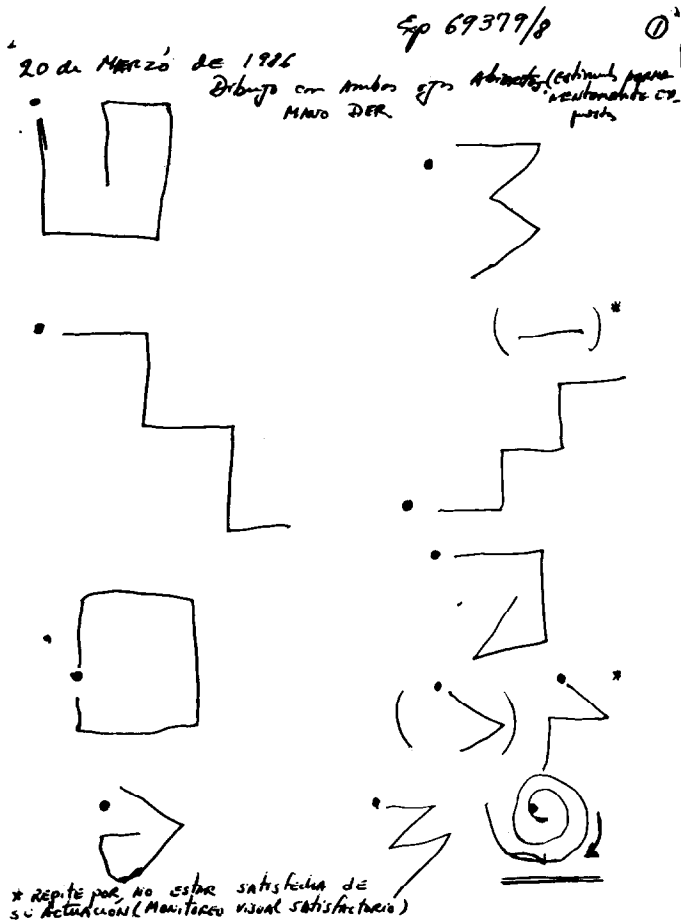


FIG. 9. Drawings reproduced with the right hand, with both eyes open and with the stimuli permanently exposed. It is observed that there was no figure reproduced in mirror image. In stimuli 6 and 8 the patient interrupted the tracing at the beginning because she was not satisfied with her performance (tracings within parentheses), accomplishing the drawings in a second trial. Stimulus 10, the spiral, was started at the center of the figure instead of at the periphery as indicated by the starting point. It was also drawn clockwise instead of counterclockwise as shown by the model.

both eyes open, (b) drawing with the right and left hand with the contralateral eye occluded, (c) drawing with the right hand with the ipsilateral eye occluded, and (d) drawing with the right and left hand with both eyes occluded (Fig. 10).

Finally, the patient was requested to write in normal fashion with her left hand to investigate what would happen.

To be sure that she was aware of her left-hand mirror writing, the authors showed to the patient samples of her own right and left handwriting; after some questioning she recognized that her left handwriting sample was written "backwards." Then, she was subjected to the written section

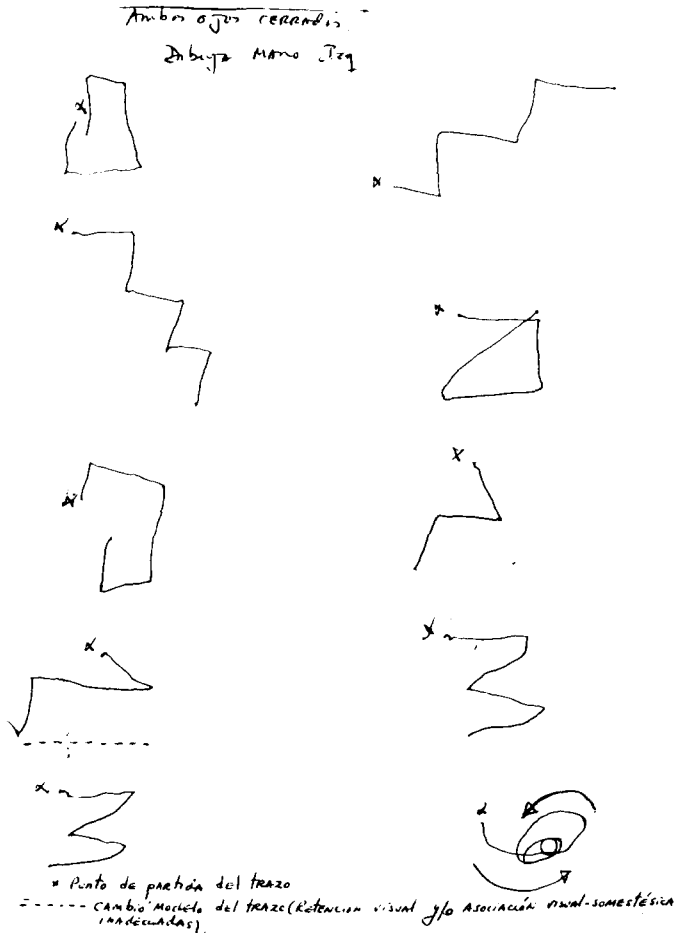


FIG. 10. Drawings reproduced with the left hand and with both eyes closed. There was not any figure reproduced in mirror image, the only mistake was the substitution of drawing 4 by 8 which might represent a failure to revisualize the correct drawing.



of the aphasia test employed by the authors in its four modalities of afference—verbal acoustic, verbal visual, nonverbal visual, and somesthetic—with the indication to try to write in normal fashion. It was very soon observed that there was a mixture of normal and abnormal letters, some of them written in a reversed direction. Due to this observation every effort was made to indicate, by means of arrows, the directionality of the different segments of the letters at the very moment the patient was writing. The task was not an easy one due to some interference between the patient and the examiner, each one engaged in their own activity. There was a further complication because the patient and the examiner sat down facing each other, with the table between them, so that the examiner was looking at the top of the patient's handwriting. This situation made it even more difficult to mark out the directionality of the different segments of the letters.

To measure the patient's performance during corrected left handwriting, each letter was analyzed separately. Quite often, it was necessary to make use of a magnifying glass to follow and determine the direction of the more complex tracings.

The following performances were considered abnormal: (a) all letters and tracings whose direction was the opposite to the one observed in normal writing, (b) all letters and tracings written in duplicated form, either with normal or reversed direction, (c) all letters and tracings in mirror writing, (d) the horizontal tracing of letters "A" and "T" written in reversed direction, from right to left, (e) all letters and tracings with one or more loops, and (f) all letters and tracings whose direction was impossible to follow due to its complexity—hence, they were classified as illegible—(Figs. 11 and 12).

It was also observed that when the patient tried to write normally with the left hand, a great deal of difficulty and awkwardness was noticed. When questioned about this, she admitted that her left hand and forearm were stiff and clumsy. She stated that it was much easier for her to write in mirror fashion than in normal handwriting with that hand.

In all the samples of her corrected left handwriting, regardless of the afferent pathways employed, there were letters with abnormal tracings. From a total of 237 letters produced by the patient's corrected left handwriting 55.5% were normal and 44.5% were abnormal.

It was also observed that there were several interruptions in writing which were not present in the patient's spontaneous mirror writing (Fig. 12). These interruptions appeared in 28.6% of the letters produced.

## DISCUSSION

The examination of the different neurophysiologic and neuropsychologic mechanisms which contribute to writing such as visual acuity, visual

III

Exp. 69379/8

21 de Agosto 1984

Ambos ojos Abiertos

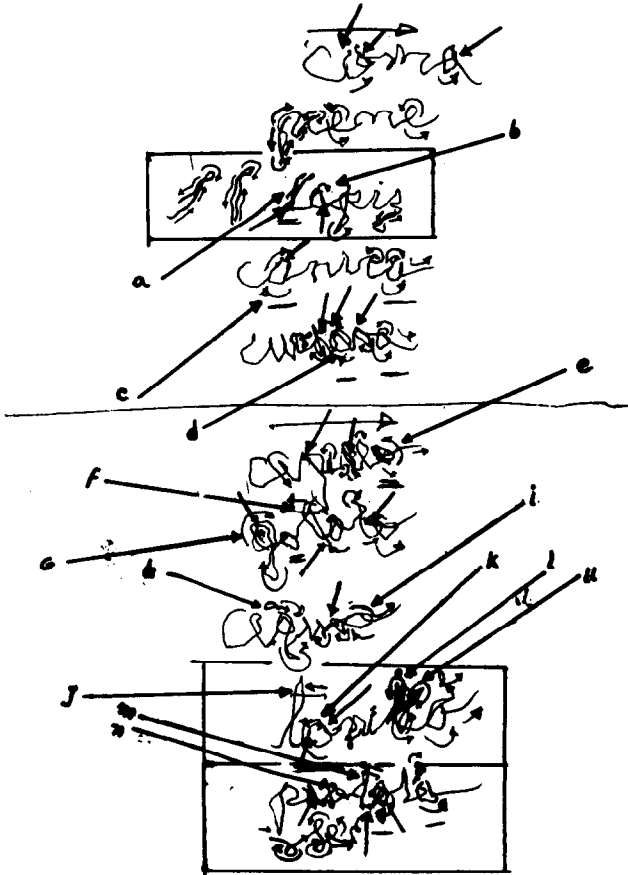


FIG. 11. Corrected left-hand writing obtained by writing the names of the stimuli palpated by the patient (somesthetic afferent pathway). The following abnormal letters can be seen: letters with reversed direction tracings (heavy arrows d, i, and k); letters with duplicated reversed direction tracings [heavy arrows c, g, and h (g and h are the upper part of letter g)]; mirror writing letters [heavy arrows a and ll (in heavy arrow a there were two trials which resulted in two letters l in mirror writing fashion)]; horizontal tracing of T in reversed direction (heavy arrows f, j, and m); letters with one or more loops (heavy arrows b, l, and n); and illegible letters (heavy arrow e). Straight small arrows point out to interruptions in writing and curved small arrows indicate direction of tracings (the reader is advised to resort to a magnifying glass when looking at the letters).

discrimination (for objects, drawings, and symbols), visuospatial orientation, motor performance of both hands, and visuomotor coordination did not disclose important abnormalities to explain the patient's left nondominant hand mirror writing.

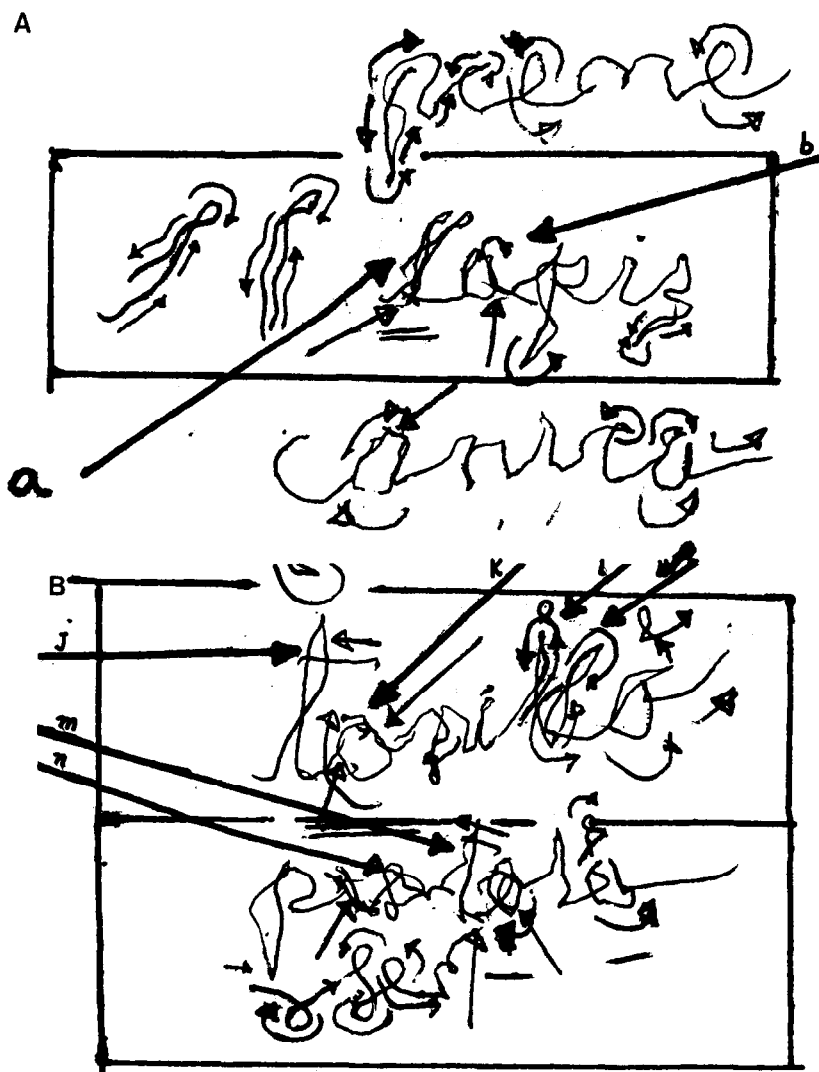


FIG. 12. (A) Inset of upper portion of Fig. 11 to better show in heavy arrow "a" two trials at writing the letter "l" of LAPIZ (PENCIL) which resulted in two superimposed mirror writing letters. The two separate "l" letters to the left of them were written by the author to show the directionality of them without disturbing the original patient's writing. Heavy arrow "b" is a letter "a" with two loops. The second loop has a small curved arrow indicating its directionality. The lower part of letter "p" has a reversed directionality and the lower part of letter "z" seems to be a very tight loop with reversed directionality of the tracing. The small curved arrows indicate directionality and the straight small arrows point out interruptions of writing. (B) Inset of lower portion of Fig. 11 shows in heavy arrow "k" a reversed direction tracing of the first "o" of the word TONILLO (SCREW). Heavy arrows "j" and "m" show a horizontal tracing of "T" in reversed direction. Heavy arrows "l" and "n" show letters with one or more loops in the first "l" of TONILLO and the first "o" of PIOTOLA. Heavy arrow "ll" shows a mirror-writing "l," the second "l" of TONILLO. The second "o" of PIOTOLA probably represents an

TABLE 1

Total number of letters produced	Normal letters	Abnormal letters	Interruptions in writing
237 (100%)	131.5 (55.5%)	105.5 (44.5%)	68 (28.6%)

With regard to somesthetic sensibility, it was found that stereognosis as well as the sense of position were well preserved; this is also confirmed by the fact that the patient could write and draw with both eyes closed. This last situation is only possible when there is an adequate position sense monitoring.

There were no alternations of the body image, and there was no confusion between the left and the right sides of the body or difficulty in identifying different segments either in her own body or in the examiner's body.

The experimental situation which introduced modifications in the relationship between the writing hand and the midline of the visual fields by occluding the eye ipsilateral to the performing hand, as well as the one that eliminated all visual monitoring by closing both eyes, without producing alterations in the patient's mirror writing strongly suggests that vision is not very important in determining this disturbance. This assumption is further strengthened by the fact that all visual functions studied were found to be within normal limits.

It was not until the motor performance of the upper limbs was examined, with special attention to the midline of the body, that the main disturbance which could explain the patient's mirror writing was detected. This abnormality was a lack of inversion of the right hand motor patterns when transmitted from the left to the right cerebral hemisphere (Rodríguez & Comacho, 1976b; Gur, Gur, Sussman, O'Connor, & Vey, 1984; Goldman-Rakic & Schwart, 1982), so that the left hand could write in the correct fashion.

Nevertheless, when nonverbal material was used there were no tracings in mirror fashion when drawing with the left hand in all experimental situations described in methodology. Drawing 10, the spiral, was traced clockwise instead of counterclockwise as shown in the model, starting at the center of the figure rather than at the periphery. This happened when drawing with the right hand, and not with the left one as expected, with both eyes open and with the stimulus permanently exposed which can be considered the easiest experimental situation. The authors do not

---

illegible letter. Notice that TORNILLO is written as TONILLO and PIRINOLA as PIOTOLA. Beneath the last word there is an author's drawing which tries to simplify the three loop tracings representing the first "o" of PIOTOLA. There are five interruptions of writing in both words indicated by the straight small arrows. The direction of the tracings is shown by the small curved arrows.

have any explanation for this fact at present. The substitution of Drawing 4 by Drawing 8 could be explained by failure to retain the visual pattern of the drawing, since this happened only when the model was momentarily exposed or when both eyes were closed.

The previously described results seem to indicate that the abnormal motor mechanism proposed as responsible for left-hand mirror writing in the patient reported is only operating when verbal material is involved but not when nonverbal is implicated. The explanation for this fact could be that nonverbal information can be handled satisfactorily by the right nondominant cerebral hemisphere. However, when verbal material is used, it has to be processed first by the left dominant hemisphere and then transferred to the right nondominant one to be expressed as left handwriting and it is at this point where the failure to reverse the motor handwriting patterns occurs.

The mixture of normal and abnormal letters, principally mirror writing letters and letters with reversed directionality, produced when the patient was asked to write in normal fashion with her left hand seems to be also in favor of an abnormal motor mechanism as the explanation for mirror writing. These abnormal letters could be taken as evidence of the persistence of some of the mirror writing patterns or mirror engrams (Heilman et al., 1980; Tankle & Heilman, 1983) despite the availability of adequate visual and somesthetic monitoring mechanisms.

The anatomical basis for these mirror writing patterns could be the fact that the corpus callosum fibers connect symmetrical cortical areas of the two cerebral hemispheres (Selnes, 1974), thus the neurons responsible for the flexor action of the thumb, the index finger, and the middle finger—which are the fingers more involved in writing—in both cerebral hemispheres would be connected by the same callosal fibers. This would also apply to the neurons in charge of the extension for the same fingers of both hands, as well as to the neurons responsible for the flexion and extension of both wrists and for the adduction and abduction of both forearms. This would result in mirror movements of each other at the level of the fingers, hand, and forearms, respectively.

Regarding the innermost organization of this abnormal cerebral motor mechanism, it is not possible to elaborate further until more is known about the way in which the neurons of the kinetic premotor areas receive and process the sensory information they will use to integrate the sequential motor activity that constitutes writing, and how this sequential motor activity is transmitted to the neurons of the primary hand-motor area so that it may be expressed in the form of writing. In the case reported here, it is also necessary to know how the neurons of the premotor kinetic areas of the two cerebral hemispheres form a relationship with each other, and how the inversion of the neuronal hand-motor patterns from the left dominant hemisphere can be accomplished after they are

transferred to the right nondominant one so that left nondominant hand normal writing can be carried out.

The question whether mirror writing, with the left nondominant hand, is related to the left cerebral hemisphere lesion presented by the patient will remain unanswered. The authors think that this could not be determined from the present study because the patient never attempted to write with the left hand before the cerebrovascular accident occurred. This circumstance does not allow us to know if the abnormal cerebral motor mechanism responsible for the patient's mirror writing existed previously.

It is highly possible that other neuropsychological mechanisms, in other patients, could be responsible for mirror writing, but it is equally likely that this lack of inversion of the hand-motor patterns could exist in other cases with this abnormality of writing so that it might be useful to keep it in mind whenever the problem of mirror writing arises.

### CONCLUSIONS

From the foregoing, the following conclusions can be drawn:

(1) All the experimental evidence gathered seems to indicate that a lack of inversion of the hand-motor patterns, transmitted from the left dominant hemisphere to the right nondominant one, is the cause of the left-hand mirror writing of the patient reported.

(2) The above-mentioned abnormal hand-motor mechanism is only operating when verbal information is used, but not when nonverbal material is involved. This peculiarity highlights the fact that the cerebral hemispheres can work independently in certain tasks but not in others.

(3) The authors did not find any supporting evidence of a perceptual mechanism, either visual or somesthetic, which could explain the left-hand mirror writing of the patient presented in this report.

(4) The question of the relation of the patient's left-hand mirror writing to the left subcortical occipitoparietal infarction will remain unanswered from the evidence available, mainly because the authors did not know if the patient had left-hand mirror writing prior to the occurrence of the cerebrovascular accident.

### REFERENCES

- Calanchini, P. R., & Trout, S. S. 1971. In L. Tarnopol (Ed.), *Learning disorders in children*. Boston: Little, Brown. P. 246.
- Christensen, A. L. 1974. In Pablo del Rio (Ed.), *El diagnóstico Neuropsicológico de Luria*. S.A. Madrid, España. 1a. edición en español. Pp. 12-19.
- Critchley, M. 1927. The significance of Mirror Writing. *Proceedings of the Royal Society of Medicine. Section of Neurology*, 20, 397.
- Ferry, P. C., Hall, S. M., & Hicks, J. L. 1975. "Dilapidated Speech": Developmental verbal dyspraxia. *Developmental Medicine and Child Neurology*, 17, 749-756.

- Gaddes, W. H. 1980. *Learning disabilities and brain function. A neuropsychological approach*. New York: Springer-Verlag. Pp. 187–189.
- Goldman-Rakic, P. S., & Schwart, M. L. 1982. Interdigitation of contralateral and ipsilateral columnar projections in frontal association cortex in primates. *Science*, **216**, 755–757.
- Gordon, H. 1920. Left handedness and mirror writing especially among defective children. *Brain*, **43**, 4.
- Gur, R. E., Gur, R. C., Sussman, N. M., O'Connor, M. J., & Vey, M. M. 1984. Hemispheric control of the writing hand: The effect of callosotomy in a left-hander. *Neurology*, **34**, 904–908.
- Heilman, K. M., Howell, G., Valenstein, E., & Rothi, L. 1980. Mirror reading and writing in association with right–left spatial disorientation. *Journal of Neurology, Neurosurgery and Psychiatry*, **43**, 774–780.
- Javal, 1906. *Physiology de la lecture et l'écriture*. Paris. Quoted by S. T. Orton in "Word-blindness" in *school children and other papers on strephosymbolia*. Compiled by J. L. Orton. The Orton Society, Inc., Pamfret, CT. Monograph No. 2, p. 33, 1966.
- Johnson, D. J., & Myklebust, H. R. 1967. *Learning disabilities (Educational principles and practices)*. New York: Grune & Stratton. Pp. 195–201.
- Kalizhnyuk, E. S. 1970. On mirror writing in children with cerebral palsies. *Zhurnal Neuropathologii i Psikiatrii*, **70**(10), 1566–1571.
- La Fay, H. 1970. *The world of Leonardo da Vinci. The Renaissance, maker of modern man*. Washington, DC: National Geographic Society. First printing, pp. 142.
- Luria, A. R. 1966. *Higher cortical functions in man*. New York: Basic Books. Pp. 417–423.
- Orton, S. T. 1925. "Word-Blindness" in school children. *Archives of Neurology and Psychiatry*, **14**, 581–615.
- Orton, S. T. 1933. Special disability in writing. *Bulletin of the Neurological Institute of New York*, **III**(1, 2).
- Rodríguez, R., & Camacho, I. 1976a. A new method for the examination of language in aphasics. Internal and external reliability coefficients. In *Proceedings IV Panamerican Congress of Neurology (México). Neurología–Neurocirugía–Psiquiatría. Suplementos 2 y 3*. Vol. 17, pp. 17–25.
- Rodríguez, R., & Camacho, I. 1976b. Aphasia due to lesions of the kniesthetic speech areas. In *Proceedings IV Panamerican Congress of Neurology (México). Neurología–Neurocirugía–Psiquiatría. Suplementos 2 y 3*. Vol. 18, pp. 115–125.
- Sato, K. 1979. A clinical study on aphasic agraphia of cerebral vascular disease origin, in reference to mirror writing and perseveratory paragrammia. *Tohoku-igaku-zasshi*, **92**(1), 26–42.
- Selnes, O. A. 1974. The corpus callosum: Some anatomical and functional considerations with special reference to language. *Brain and Language*, **1**, 111–139.
- Sereni, E. 1923. *Rev. di Psicol.* 19: 135. Quoted by S. T. Orton in "Word-Blindness" in *school children and other papers on strephosymbolia*. Compiled by J. L. Orton. The Orton Society Inc. Pamfret, CT. Monograph No. 2, p. 35, 1966.
- Sunohara, N., Saku, A., Kinoshita, M., & Satoyoshi, E. 1978. A case of mirror writing due to a focal cerebral lesion. *Rinsho Shinkeigaku*, **18**(9), 525–531.
- Tankle, R. S., & Heilman, K. M. 1983. Mirror writing in right-handers and in left-handers. *Brain and Language*, **19**, 115–123.
- Verdejo, C. 1969. *Leonardo da Vinci*. Biblioteca Hispania Ilustrada. Figuras. Editorial Ramon Sopena, S.A. Barcelona. Vol. 13, p. 205.
- Wechsler, D. 1972. *The Wechsler memory scale*. New York: Psychological Corp.