

## Treatment of Refractory Status Epilepticus with Vagus Nerve Stimulator in an Elderly Patient

Joseph S. Yazdi and Jean A. Schumaker

### Key words

- Antiepileptic medication
- Elderly
- Status epilepticus
- Subdural hematoma
- Vagus nerve stimulator

### Abbreviations and Acronyms

- CT:** Computed tomography  
**EEG:** Electroencephalogram  
**IV:** Intravenous  
**POD:** Postoperative day  
**RSE:** Refractory status epilepticus  
**SDH:** Subdural hematoma  
**SE:** Status epilepticus  
**VNS:** Vagus nerve stimulator

Division of Neurosurgery, St. Elizabeth's Hospital, Belleville, Illinois, USA

To whom correspondence should be addressed:  
 Joseph S. Yazdi, M.D.  
 [E-mail: joeyaz21@yahoo.com]

Citation: *World Neurosurg.* (2016).  
<http://dx.doi.org/10.1016/j.wneu.2016.08.017>

Journal homepage: [www.WORLDNEUROSURGERY.org](http://www.WORLDNEUROSURGERY.org)

Available online: [www.sciencedirect.com](http://www.sciencedirect.com)

1878-8750/\$ - see front matter © 2016 Elsevier Inc. All rights reserved.

### INTRODUCTION

Status epilepticus (SE) is defined as a continuous seizure lasting more than 30 minutes or 2 or more seizures without full recovery of consciousness between seizures.<sup>1</sup> Seizures are one of the most common complications that can occur after evacuation of subdural hematomas (SDHs).<sup>2</sup> SDHs can produce seizures by causing cortical irritation. The seizures can present in a number of different manners ranging from gross motor movements to a change in mental status. These seizures can be treated by a variety of antiepileptic medications. However, despite treatment, a small percentage of patients will develop SE. Furthermore, 30% of patients with SE will go on to develop refractory status epilepticus (RSE).<sup>3</sup> We present a case of a 67-year-old man who developed RSE after evacuation of a spontaneous SDH despite aggressive medical management.

■ **BACKGROUND:** One of the risks of a traumatically induced intracranial bleed is development of new onset seizures. Rarely would these seizures progress to status epilepticus (SE) or refractory SE. There is a lack of literature on the use of a vagus nerve stimulator in these situations in older adults.

■ **CASE DESCRIPTION:** We present a 67-year-old patient who developed refractory status epilepticus within days after evacuation of a right-sided spontaneous subdural hematoma. He was refractory to multiple antiepileptic agents and phenobarbital- and propofol-induced coma. He then underwent a left vagus nerve stimulator (VNS) implantation. Within a few days of implantation, he improved dramatically. Within 2 weeks of VNS implantation, he was neurologically intact and was transferred to an inpatient rehabilitation facility. Within a short time thereafter, he was fully functional and able to take care of all of his activities.

■ **CONCLUSIONS:** A vagus nerve stimulator should be considered in cases of refractory status epilepticus, regardless of age. Excellent outcome can be achieved even if a short course of medication-induced coma is unsuccessful.

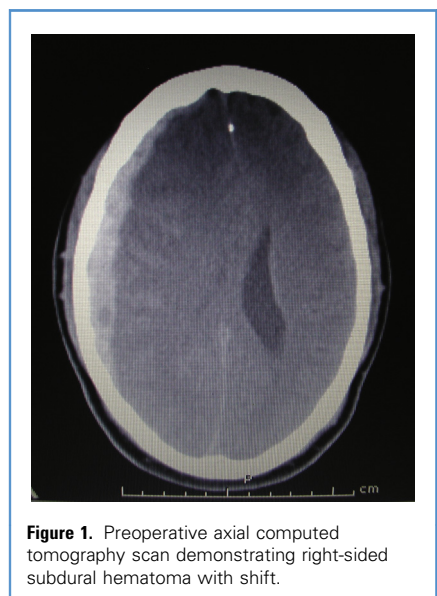
His seizures only stopped when a vagus nerve stimulator (VNS) (Cyberonics, Webster, Texas, USA) was added to his medical treatment. The patient made a remarkably quick and full recovery. Although there have been reports of treating RSE with VNS in children and young adults, to our knowledge, this is the first case involving an elderly patient in the setting of an SDH.

### CASE REPORT

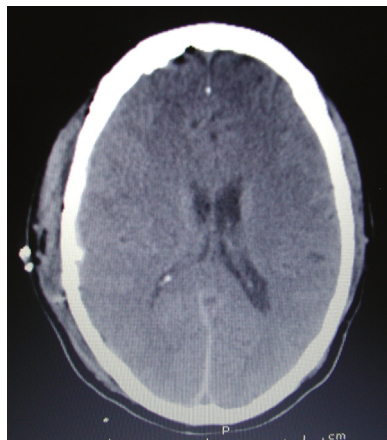
The patient was a 67-year-old man who presented to the emergency department with complaint of sudden onset headache, nausea, and vomiting. His medical history was significant for coronary arterial disease and stent placement. He was on clopidogrel. His examination was significant for slight lethargy and left-sided dysmetria. Computed tomography (CT) scan showed an acute right SDH with herniation to the left (**Figure 1**). Platelet function assay was abnormal. Therefore, he received platelet transfusion, started on levetiracetam 500 mg intravenously twice per day, and then taken to the

operating room emergently for a right-sided craniotomy for evacuation of the SDH.

The following morning a repeat CT scan showed complete resolution of the SDH



**Figure 1.** Preoperative axial computed tomography scan demonstrating right-sided subdural hematoma with shift.

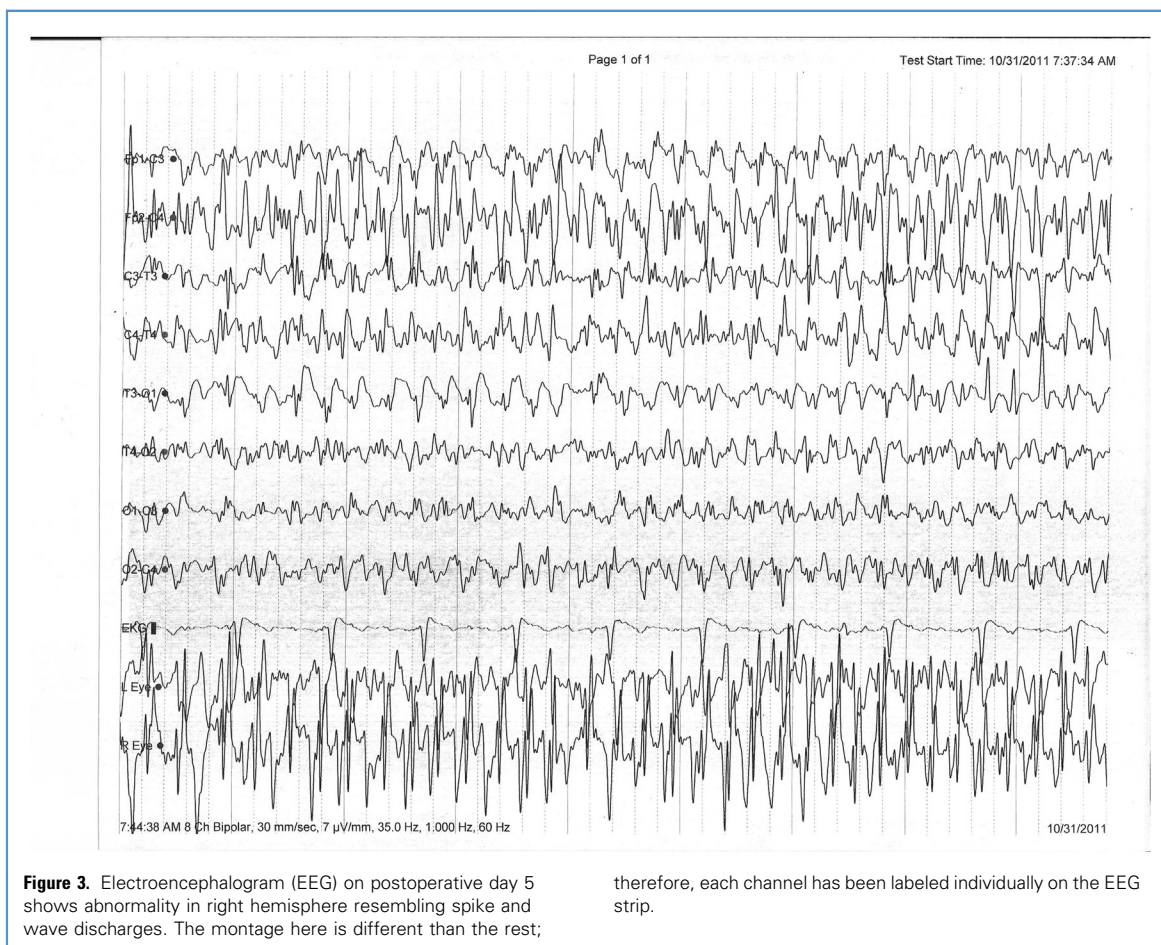

**Figure 2.** Postoperative axial computed tomography scan at the same level as in [Figure 1](#), demonstrating complete resolution of the subdural hematoma.

([Figure 2](#)). His neurologic examination was intact, and he was transferred to telemetry. Over the next day, he experienced more

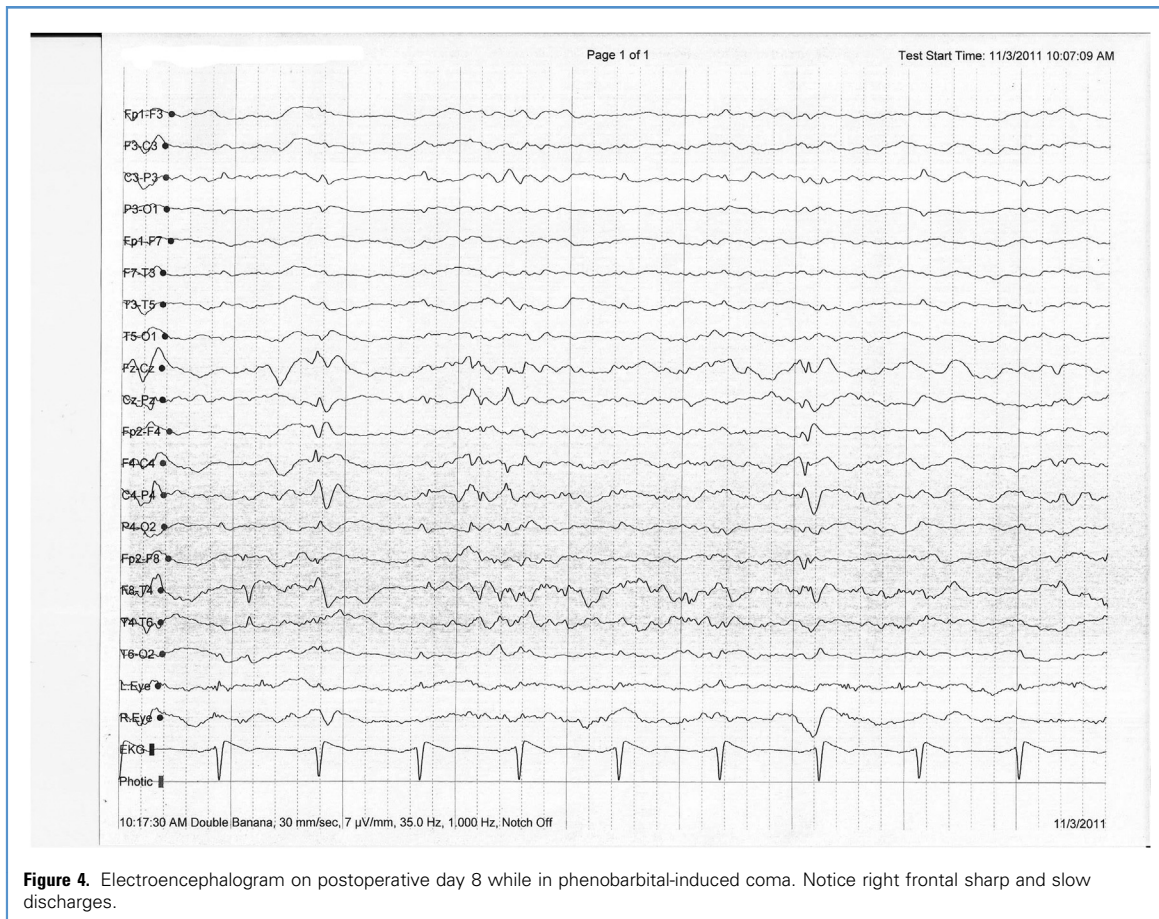
and more frequent episodes of mental status changes. By postoperative day (POD) 3, he had frequent periods of lethargy and demonstrated left-sided weakness. A repeat CT scan showed no changes. Specifically, there was no evidence of a bleed or a stroke. Our main diagnosis was that he was experiencing seizures despite being on levetiracetam. Neurology service was consulted. He was transferred back to the intensive care unit and started on phenytoin. Initially, he received 1 g intravenous (IV) bolus followed by 100 mg intravenously every 8 hours. On POD 4, he was obtunded and demonstrated new onset of brief periods of jaw smacking and left facial twitching. He was intubated. Three boluses of phenytoin 200 mg intravenously were administered, and the levetiracetam dose was increased to 750 mg. Phenytoin level reached up to 17.1  $\mu\text{g/mL}$ . However, the seizures continued. Therefore, 1 g of valproic acid was administered followed by 500 mg intravenously every 8 hours. He was also started on a midazolam

drip both for sedation and seizure control. The initial rate was 1 mg/h, but over the rest of the day, it was gradually increased to 2.5 mg/h. Despite these efforts, he continued to have jaw smacking. Therefore, he was started on phenobarbital. The initial dose was 300 mg intravenously followed by 150 mg every 8 hours. He continued to have seizures on POD 5 as demonstrated by persistent jaw smacking and facial twitching. Therefore, an additional dose of phenobarbital was administered, and carbamazepine was started at 200 mg every 8 hours. The valproic acid level was 44  $\mu\text{g/mL}$ ; therefore, the dose was increased to 750 mg. The valproic acid level stayed steady between 58 and 66  $\mu\text{g/mL}$  from then on. Levetiracetam was discontinued. He was also placed on dexamethasone 10 mg intravenously every 6 hours. Electroencephalogram (EEG) showed almost periodic spike-wave discharges from the right hemisphere ([Figure 3](#)). These were believed to be epileptic discharges because they



**Figure 3.** Electroencephalogram (EEG) on postoperative day 5 shows abnormality in right hemisphere resembling spike and wave discharges. The montage here is different than the rest;

therefore, each channel has been labeled individually on the EEG strip.



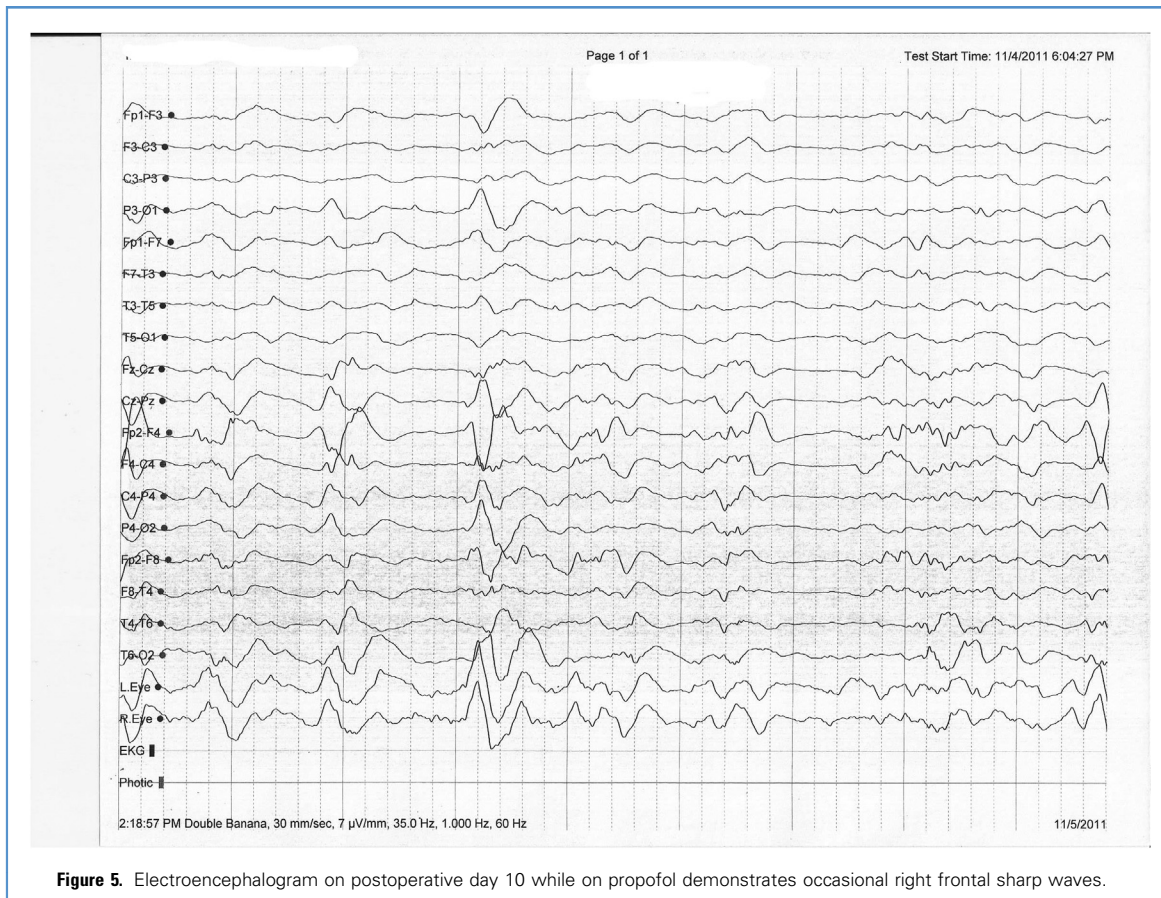
**Figure 4.** Electroencephalogram on postoperative day 8 while in phenobarbital-induced coma. Notice right frontal sharp and slow discharges.

correlated with seizure activity. As a result, we decided to place the patient into phenobarbital-induced coma by administering phenobarbital 300 mg intravenously every 12 hours. The phenytoin level was increased to 200 mg and carbamazepine was increased to 400 mg, both administered every 8 hours. The patient was kept on this phenytoin dose throughout the rest of his hospital stay, and the phenytoin level stayed between 12.5 and 18.1 µg/mL. Finally, the facial and jaw twitching stopped, but by then, phenobarbital had reached a toxic level of 46.9 µg/mL. Despite that, the EEG continued to demonstrate occasional right frontal sharp and slow discharges, which we believed to be epileptogenic (**Figure 4**). Therefore, the phenobarbital was stopped, and propofol was started. Initially, a bolus of 100 mg (1.5 mg/kg) was administered. This was followed by an infusion at a rate of 2 µg/kg/min and titrated based on EEG. When the propofol reached a rate of

5 µg/kg/min, the EEG showed better suppression of the background spike activity. However, the propofol was stopped after 3 days because of cardiac toxicity resulting in bradycardia. By then, his phenobarbital level had already decreased to the mid-30s range, but there were no neurologic improvements. Furthermore, the occasional periodic sharp waves in the right frontal lobe continued (**Figure 5**). Because these were also felt to be epileptogenic in nature, as a last resort treatment option, the patient underwent a left VNS implant. The VNS was placed on POD 14 in the usual manner as previously described.<sup>4,5</sup> The VNS was programmed in the operating room, and the settings were as follows: current output 1.5 mA, signal frequency 30 Hz, pulse width 500 microseconds, signal time on 14 seconds, signal time off 0.8 minute, magnet current 1.75 mA, magnet time on 60 seconds, and magnet pulse width 500 microseconds.

The next day after surgery, the patient was diagnosed with a urinary tract infection and sepsis. He had a temperature of 101.4°F, and low blood pressure requiring boluses of IV fluid. He was placed on appropriate antibiotics. His fever and hemodynamic irregularities resolved after 4 days. The following day, his neurologic examination significantly improved. Two days later, he was awake, alert, and attentive, demonstrated appropriate speech, and was moving all 4 extremities symmetrically to command. By that day, the phenobarbital level had steadily decreased to 19.8 µg/mL. EEG showed very occasional right frontal and central low voltage sharp discharges (**Figure 6**). Within another week, he was discharged to a rehabilitation center. His medications on discharge included phenytoin 200 mg every 6 hours and valproic acid 750 mg every 8 hours.

He was seen for follow-up 6 weeks after he was admitted to the rehabilitation unit.



**Figure 5.** Electroencephalogram on postoperative day 10 while on propofol demonstrates occasional right frontal sharp waves.

He was neurologically intact and able to perform all activities without any restrictions. An EEG done at that time did not demonstrate any seizures (Figure 7). He has been followed clinically for 5 years, and 1 new seizure has been encountered. This was a complex partial seizure that occurred approximately 3 months after discharge from the hospital, and it was believed to be caused by a subtherapeutic phenytoin level. His medications have been slightly decreased to phenytoin 300 mg twice a day and valproic acid 1000 mg twice a day. During this period, the VNS parameters have gradually changed to an output current of 2 mA, signal frequency of 30 Hz, pulse width of 30 microseconds, signal time on of 30 seconds and time off of 10 minutes, magnet current of 2 mA, on time of 30 seconds, and pulse of 250 microseconds. He has continued all of his activities without any limitations.

Because of the patient's long period of bedrest and despite using compression

boots, he developed a deep venous thrombosis on POD 7, which was treated promptly with an inferior vena cava filter.

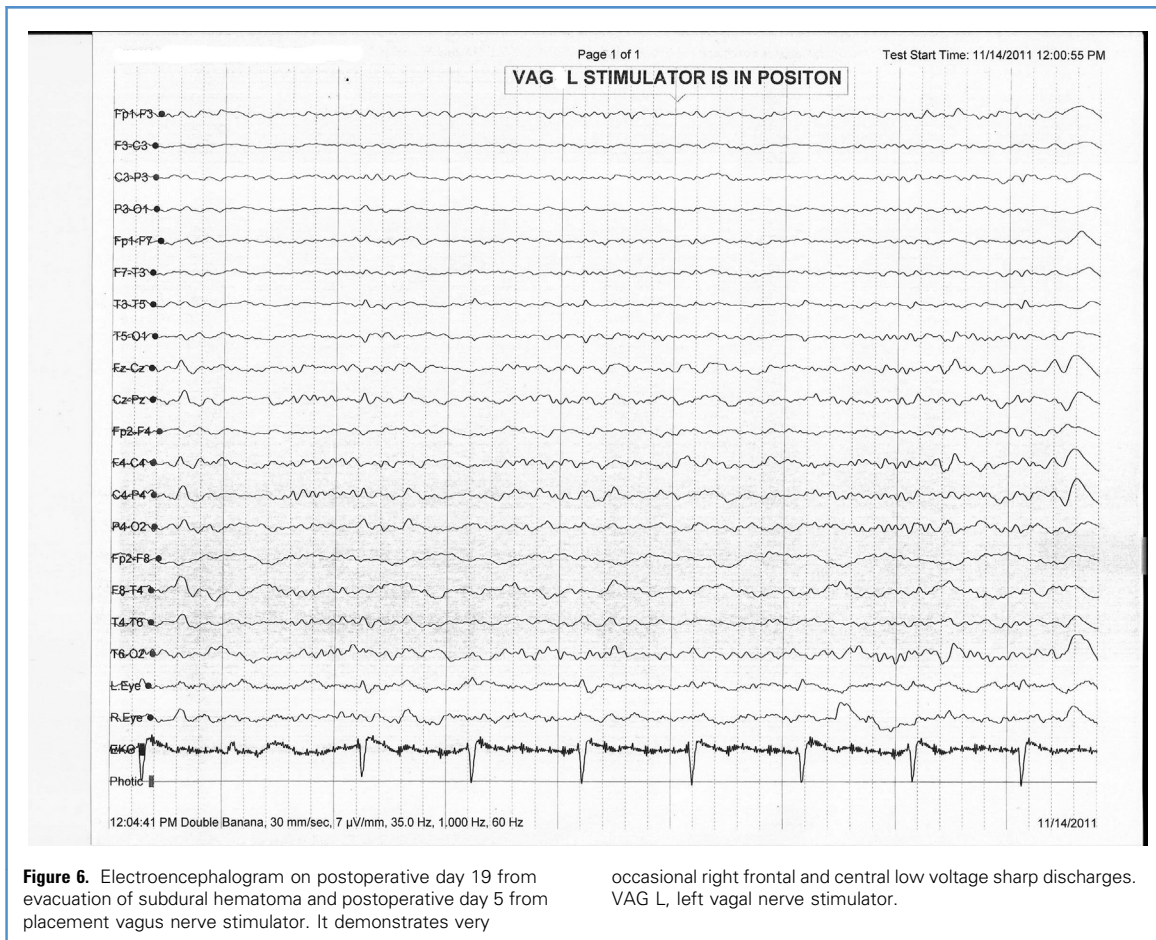
## DISCUSSION

### Definition of RSE

Seizures can be defined as abnormal electrical activity of the brain. Seizures can occur after any insult to the brain, such as trauma, infarct, infection, space-occupying lesions (e.g., tumor, abscess), or metabolic disturbances. They can also be idiopathic. More than 80 per 100,000 people develop new-onset seizures each year. Additionally, about 41 per 100,000 people develop SE annually. For patients with acute SDH who undergo a craniotomy for evacuation of the bleed, up to 25% can develop seizures or epileptiform discharges on EEG.<sup>2</sup> Not all of these seizures are convulsive; therefore, it is important to consider seizures in

patients who are not recovering as expected after evacuation of an SDH. Despite medications to control the seizures, approximately 0.5%–0.7% will go on to develop SE.<sup>6</sup> SE is a medical emergency associated with significant morbidity and mortality. Complications of SE include cardiac dysrhythmias, derangements of metabolic and autonomic function, rhabdomyolysis, and hyperthermia. First-line treatment of SE is benzodiazepines. Approximately one-third of patients with SE will fail first-line medications, and additional medications will be needed, such as barbiturates, levetiracetam, or valproic acid.<sup>1</sup>

Approximately 30% of patients with SE will go on to develop RSE. RSE is described as SE that has failed first- and second-line drugs.<sup>3,7</sup> Typically, at this point, general anesthesia is recommended. Medications that are used at this stage include propofol, pentobarbital, or midazolam.<sup>7</sup> The goal is burst-suppression



on EEG. A very small minority of patients will develop super-RSE. This occurs when no medication is effective in controlling the seizures. Treatment options are few, and outcomes are generally poor.<sup>8</sup>

#### VNS and Mechanism of Action

In 1997, the Food and Drug Administration approved the use of VNS for medically refractory partial onset seizures in adults and adolescents in the United States based on the results of pilot studies and a multicenter, prospectively randomized, double-blinded study.<sup>4,9-12</sup> It was indicated as an adjunctive therapy in reducing the frequency and duration of partial seizures in those patients whose seizures were not controlled by at least 2 medications.<sup>13</sup> Those studies demonstrated that the VNS was able to reduce the frequency of seizures by approximately 50%.<sup>12</sup> However, indications slowly expanded over the

years to include not only children but also those suffering from generalized seizures, including from Lennox-Gastaut syndrome.<sup>14,15</sup>

The specific mechanism of action has not been determined. It is known that VNS activates the vagus nerve in both antegrade and retrograde fashions. Antegrade stimulation can potentially result in increased gastric secretion and bradycardia, but these are rarely observed.<sup>4,16,17</sup> The main hypothesis involves retrograde activation. The vagus nerve carries visceral sensation from the head, neck, abdomen, and thorax to the nucleus of the tractus solitarius. From there, it can take on a number of possible pathways as elucidated by Henry<sup>16</sup> and Schachter and Saper.<sup>5</sup> A brief summary is as follows. Two of the pathways sends signals from carotid and aortic arch baroreceptors and pulmonary stretch receptors to the autonomic preganglionic nuclei, somatic

motor neurons, and reticular formation in the medulla. These pathways mainly deal with heart rate and respiratory rate regulation and therefore most likely do not play a part in seizure control. A third pathway goes through the parabrachial nucleus, which projects fibers to the thalamus and hypothalamus, which subsequently send fibers to the cortex. This may be one pathway of controlling seizure activity. Another hypothesis involves fibers projecting from the nucleus of the tractus solitarius to the locus coeruleus and the raphe nuclei, which in turn project noradrenergic and serotonergic fibers to the entire cortex, respectively.<sup>16</sup> Norepinephrine and serotonin have antiseizure effects on cortical neurons. However, another hypothesis postulates that VNS causes increased blood flow to the thalamus, which allows for better seizure control.<sup>13</sup>



that by placing the VNS at that time, we were able to improve his chances of a great outcome. Unfortunately, because of his postoperative complications, we cannot be absolutely certain that the VNS was the only reason for our patient's clinical improvement.

An argument can be made regarding the efficacy of VNS in our case. There could have been a possibility of natural resolution of seizure focus if given more time so that the 2 antiepileptic medications at discharge would have sufficed. Given his EEG findings while on phenobarbital and propofol, we were reasonably certain that when the phenobarbital level lowered below the toxic level, his seizures would resume. We felt that VNS placement was a reasonable choice in order to help get his seizures under control, stop the sedative medications, get him extubated, and make him ambulatory. The patient had a breakthrough seizure 3 months after VNS implantation while also on 2 antiepileptic drugs, which implies then the epileptic focus was still active.

There are many risks involved with prolonged intubation and bedrest in older adults that have to be taken into account as well. Our patient developed deep venous thrombosis and needed an inferior vena cava filter placement on POD 7. He also developed a urinary tract infection resulting in sepsis. Other possible life-threatening complications include cardiac, pulmonary, and renal failure, pneumonia, and decubitus ulcers. We did not think that waiting for a longer period of time for the possibility of resolution of the seizure focus was an appropriate action in this case.

Our case presentation brings up a number of questions. What is the proper timing of placing a VNS in cases of SE or RSE in older adults? Should they undergo a single or multiple drug-induced coma before deciding on placing a VNS? What are the chances that this treatment will work this well in this situation? These and many other questions will only be answered by larger studies.

## CONCLUSIONS

We want to bring to the attention of neurologists and neurosurgeons that VNS

placement is a viable option for SE and RSE, even in older adults. It may be a better option than prolonged medically induced coma with faster recovery and less morbidity or mortality.

## ACKNOWLEDGMENTS

The authors thank our neurologist, Dr. Panduranga Kini, for assisting in the preparation of this manuscript.

## REFERENCES

- Cherian A, Thomas S. Status epilepticus. *Ann Indian Acad Neurol.* 2009;12:140-153.
- Rabinstein A, Chung SY, Rudzinski L, Lanzino G. Seizures after evacuation of subdural hematomas: incidence, risk factors, and functional impact. *J Neurosurg.* 2010;112:455-460.
- Mayer SA, Claassen J, Lokin J, Mendelsohn F, Dennis LJ, Fitzsimmons B. Refractory status epilepticus: frequency, risk factors, and income on outcome. *Arch Neurol.* 2002;59:205-210.
- Ramsay RE, Uthman BM, Augustinsson LE, Upton RM, Naritoku D, Willis J, et al. Vagus nerve stimulation for treatment of partial seizures: 2. Safety, side effects, and tolerability. *Epilepsia.* 1994;35:627-636.
- Schachter S, Saper C. Vagus nerve stimulation. *Epilepsia.* 1998;39:677-686.
- Seifi A, Asadi-Pooya AA, Carr K, Maltenfort M, Emami M, Bell R, et al. The epidemiology, risk factors, and impact on hospital mortality of status epilepticus after subdural hematoma in the United States. *Springerplus.* 2014;3:332.
- Shorvon S, Ferlisi M. The treatment of super-refractory status epilepticus: a critical review of available therapies and a clinical treatment protocol. *Brain.* 2011;134:2802-2818.
- Ferlisi M, Hocker S, Grade M, Trinka E, Shorvon S. Preliminary results of global audit of treatment of refractory status epilepticus. *Epilepsy Behav.* 2015;49:318-324.
- Perry JK, Dean JC. Prevention of intractable partial seizures by intermittent vagal stimulation in humans: preliminary report. *Epilepsia.* 1990;31 suppl 2:S40-S43.
- Uthman BM, Wilder BJ, Hammond EJ, Reid SA. Efficacy and safety of vagus nerve stimulation in patients with complex partial seizures. *Epilepsia.* 1990;31 suppl 2:S44-S50.
- Wilder BJ, Uthman BM, Hammond EJ. Vagal stimulation for control of complex partial seizures in medically refractory epileptic patients. *Pacing Clin Electrophysiol.* 1991;14:108-115.
- Ben-Menachem E, Manon-Espaillet R, Ristanovic R, Wilder BJ, Stefan H, Mirza W, et al. Vagus nerve stimulation for treatment of partial

seizures: 1. A controlled study of effect on seizures. *First International Vagus Nerve Stimulation Study Group. Epilepsia.* 1994;35:616-626.

- Wheless JW, Baumgartner J. Vagus nerve stimulation therapy. *Drugs Today (Barc).* 2004;40:501-505.
- Wheless JW, Maggio V. Vagus nerve stimulation therapy in patients younger than 18 years. *Neurology.* 2002;59(6 suppl 4):S21-S25.
- You SJ, Kang HC, Kim HD, Ko TS, Kim DS, Hwang YS, et al. Vagus nerve stimulation in intractable childhood epilepsy: a Korean multicenter experience. *J Korean Med Sci.* 2007;22:442-445.
- Henry T. Therapeutic mechanisms of Vagus nerve stimulation. *Neurology.* 2002;59(6 suppl 4):S3-S14.
- Cantarin-Extremera V, Ruiz-Rojas ML, Tamariz-Martel-Moreno A, Garcia-Fernandez M, Duat-Rodriguez A, Rivero-Martin B. Late-onset periodic bradycardia during vagus nerve stimulation in a pediatric patient. A new case and review of the literature. *Eur J Paediatr Neurol.* 2016;20:678-683.
- Lucchi C, Vinet J, Meletti S, Biagini G. Ischemic-hypoxic mechanisms leading to hippocampal dysfunction as a result of status epilepticus. *Epilepsy Behav.* 2015;49:47-54.
- Lapenta L, Frisullo G, Vollono C, Brunetti V, Giannantoni N, Sandroni C, et al. Super-refractory status epilepticus: report of a case and review of the literature. *Clin EEG Neurosci.* 2015;46:335-339.
- Alvarez V, Drislane FW. Is favorable outcome possible after prolonged refractory status epilepticus? *J Clin Neurophysiol.* 2016;33:32-41.
- O'Neil B, Valeriano J, Synowiec A, Thielmann D, Lane C, Wilberger J. Refractory status epilepticus treated with vagal nerve stimulation: case report. *Neurosurgery.* 2011;69:1172-1175.
- Zamponi N, Rychlicki F, Corpaci L, Cesaroni E, Trignani R. Vagus nerve stimulation (VNS) is effective in treating catastrophic 1 epilepsy in very young children. *Neurosurg Rev.* 2008;31:291-297.
- Patwardhan RV, Delabadia J Jr, Rashidi M, Grier L, Nanda A. Control of refractory status epilepticus precipitated by anticonvulsant withdrawal using left vagal nerve stimulation: a case report. *Surg Neurol.* 2005;64:170-173.

*Conflict of interest statement: The authors declare that the article content was composed in the absence of any commercial or financial relationships that could be construed as a potential conflict of interest.*

Received 21 March 2016; accepted 5 August 2016

Citation: *World Neurosurg.* (2016).

<http://dx.doi.org/10.1016/j.wneu.2016.08.017>

Journal homepage: [www.WORLDNEUROSURGERY.org](http://www.WORLDNEUROSURGERY.org)

Available online: [www.sciencedirect.com](http://www.sciencedirect.com)

1878-8750/\$ - see front matter © 2016 Elsevier Inc. All rights reserved.