

## Case Studies

# Resolving Thrombus in the Left Atrial Appendage by Edoxaban Treatment after Acute Ischemic Stroke: Report of 2 Cases

Shin Saito, MD, PhD, Seigo Shindo, MD, Shun Tsudaka, MD, Kazutaka Uchida, MD, Manabu Shirakawa, MD, PhD, and Shinichi Yoshimura, MD, PhD

---

Here we report first 2 cases of patients with nonvalvular atrial fibrillation with acute cardioembolic stroke in whom thrombi in the left atrial appendage (LAA) were resolved by edoxaban administration. Case 1 reports an 86-year-old woman who suddenly showed right hemiparesis and aphasia due to occlusion of the left middle cerebral artery. She received mechanical thrombectomy and recovered neurologically. Transesophageal echocardiography (TEE) performed on day 1 demonstrated thrombus in the LAA. The thrombus was resolved on day 13 after initiation of edoxaban (30 mg once daily) instead of warfarin, which was administered before stroke onset. Case 2 reports a 49-year-old man who was admitted because of the sudden onset of left hemiparesis and aphasia. TEE demonstrated thrombus in the LAA on day 4, and edoxaban therapy (60 mg once daily) was initiated. The thrombus resolution was observed on day 16, and no embolic stroke occurred. **Key Words:** Edoxaban—resolution—left atrial appendage thrombus—atrial fibrillation. © 2016 National Stroke Association. Published by Elsevier Inc. All rights reserved.

---

## Introduction

Direct oral anticoagulant (DOAC) is used commonly for the prevention of cardioembolic stroke in patients with nonvalvular atrial fibrillation (NVAF). Here we report 2 patients with acute cardiogenic cerebral embolism, in

whom thrombi in the left atrial appendage (LAA) were resolved by administration of edoxaban.

## Case Report

Case 1 reports an 86-year-old Japanese woman with NVAF and hypertrophic cardiomyopathy who was transferred to our hospital due to ventricular fibrillation. Her cardiac systolic function was normal, and ejection fraction was 74%, but the value of brain natriuretic peptide was 1110 pg/mL. The left atrium of the patient's heart was large and the size was 47 mm. She received implantation of implantable cardioverter defibrillator when hemodynamics was stable, and the patient noticed the hemiparesis and aphasia 4 days later. National Institutes of Health Stroke Scale score was 24, and prothrombin time international normalized ratio value was 1.54 under the administration of warfarin. There was no early ischemic change in the left cerebral cortex in head computed tomography (Fig 1, A). Tissue plasminogen activator was administered. Digital subtraction angiography showed the left middle cerebral artery

---

From the Neurosurgery, Hyogo College of Medicine, Nishinomiya, Japan.

Received October 20, 2015; revision received July 20, 2016; accepted July 24, 2016.

Grant support: There was no grant support for this study.

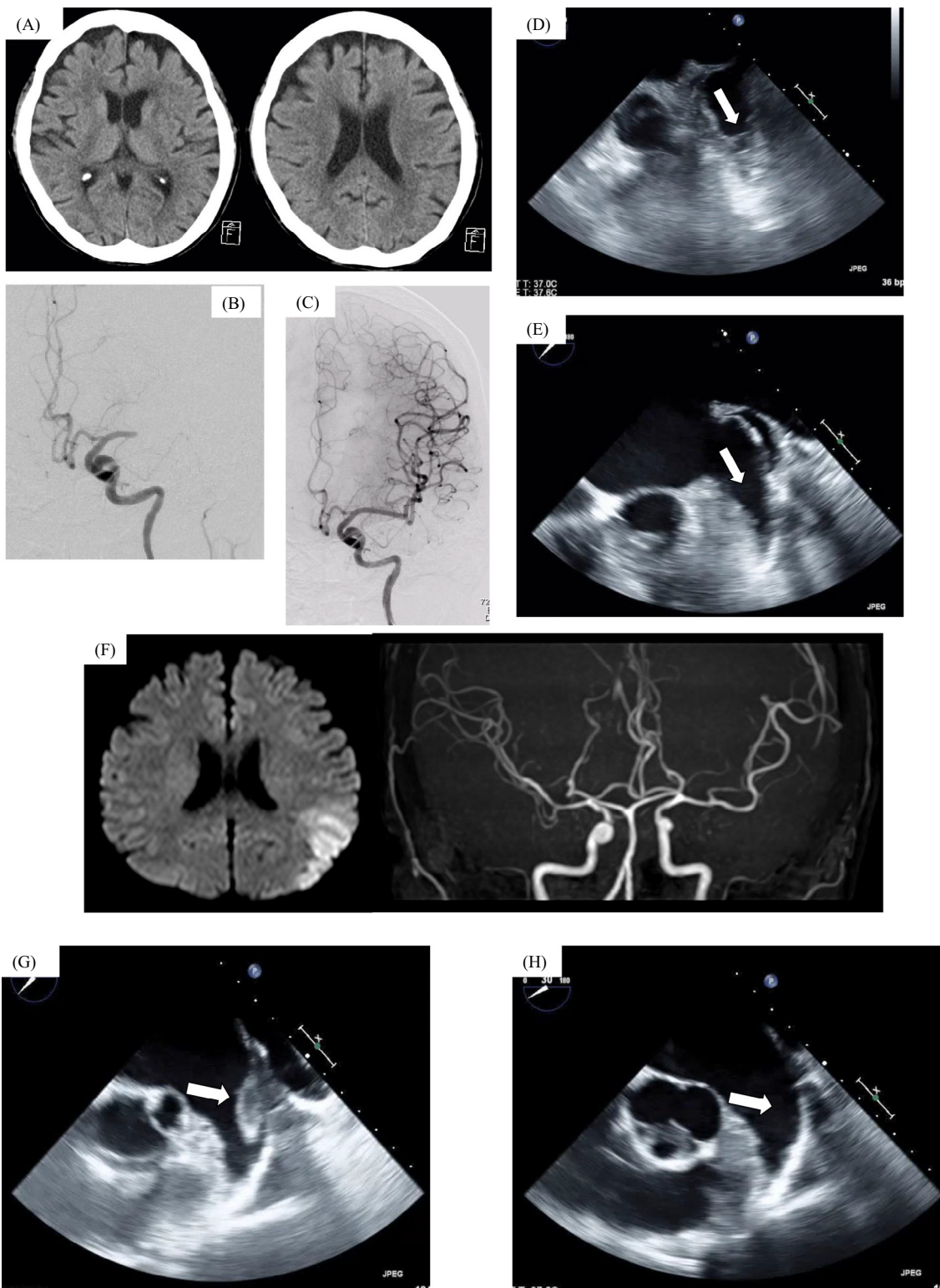
Conflict of interest: Dr. Shinichi Yoshimura received Speakers' Bureau/Honorarium from Boehringer-Ingelheim, Tanabe Mitsubishi Pharma, and Bayer. The other authors have no conflict of interest to disclose. There was no financial support for this study.

Address correspondence to Shinichi Yoshimura, MD, PhD, Department of Neurosurgery, Hyogo College of Medicine, 1-1, Mukogawa, Nishinomiya, Hyogo 663-8501, Japan. E-mail: [s-yoshi@hyo-med.ac.jp](mailto:s-yoshi@hyo-med.ac.jp).

1052-3057/\$ - see front matter

© 2016 National Stroke Association. Published by Elsevier Inc. All rights reserved.

<http://dx.doi.org/10.1016/j.jstrokecerebrovasdis.2016.07.036>



**Figure 1.** Images in case 1 (A–E) and case 2 (F–H). (A) Head computed tomography showed no early ischemic change in the left cerebral cortex. (B) Digital subtraction angiography showed the left middle cerebral artery occlusion. (C) Mechanical thrombectomy was performed and complete reperfusion was obtained. (D) A thrombus (arrow,  $13.3 \times 10.6$  mm) in the left atrial appendage (LAA) detected on transesophageal echocardiography (TEE) performed on day 1. (E) Disappeared thrombus by TEE on day 13 after edoxaban therapy. (F) Brain diffusion-weighted magnetic resonance image showed hyperintense signal in the left cerebral cortex. Cerebral artery occlusion was not clear on magnetic resonance angiography. (G) TEE revealed a mobile thrombus (arrow,  $27.5 \times 15.0$  mm) in the LAA on day 4. (H) Resolved thrombus by TEE on day 16 after edoxaban therapy.

**Table 1.** Reported cases with intracardiac thrombus treated by DOACs

Case no.	Age	Sex	Basic disease	DOACs (dosage)	Course of thrombus	Ref.
1	72	F	HF	Dabigatran (300 mg/day)	Resolved	2
2	74	M	CCE	Dabigatran (220 mg/day)	Enlarged	3
3	59	M	HOCM	Dabigatran (300 mg/day)	Resolved	4
4	77	M	Af	Dabigatran (220 mg/day)	Resolved	5
5	64	M	Af	Rivaroxaban (15 mg/day)	Resolved	6
6	81	F	Af	Rivaroxaban (10 mg/day)	Resolved	7
7	75	M	Af	Rivaroxaban (10 mg/day)	Resolved	7
8	75	M	Af	Rivaroxaban (10 mg/day)	Resolved	7
9	71	M	CCE	Rivaroxaban (15 mg/day)	Resolved	8
10	72	M	HF	Apixaban (10 mg/day)	Resolved	9
11	67	M	Af	Apixaban (5 mg/day)	Resolved	10
12	55	M	Af	Apixaban (10 mg/day)	Resolved	11
13	86	F	Af	Edoxaban (30 mg/day)	Resolved	Present case
14	49	M	Af	Edoxaban (60 mg/day)	Resolved	Present case

Abbreviations: Af, atrial fibrillation; CCE, cerebral cardiogenic embolism; HF, heart failure; HOCM, hypertrophic obstructive cardiomyopathy; DOAC, direct oral anticoagulant.

occlusion (Fig 1, B). She received mechanical thrombectomy, and complete reperfusion was obtained (Fig 1, C). National Institutes of Health Stroke Scale score was dramatically improved from 24 to 4. Transesophageal echocardiography (TEE) performed on day 1 showed thrombus (13.3 × 10.6 mm) in the LAA (Fig 1, D) and small plaque but no mural thrombi on the aorta. The value of D-dimer was 3.18 at that time. Diagnosis of cardioembolism associated with NVAF was confirmed, and warfarin was switched to edoxaban (30 mg once daily because of body weight less than 60 kg) immediately after 3 days from onset. The thrombus was resolved on day 13 on TEE (Fig 1, E), and then the D-dimer value was .79. No recurrent embolism was observed thereafter by clinical symptoms and head computed tomography.

Case 2 reports a 49-year-old Japanese man with hypertension and NVAF who was admitted because of the sudden onset of left hemiparesis and aphasia. Brain diffusion-weighted magnetic resonance image revealed hyperintense signal in the left cerebral cortex (Fig 1, F). TEE detected a thrombus on the LAA (27.5 × 15.0 mm) on day 4 (Fig 1, G), and no small plaque and no mural thrombi were detected on the aorta. The value of D-dimer was negative then. He was diagnosed with acute cardioembolic stroke due to NVAF and had not been treated with any anticoagulants before the ictus, and edoxaban therapy (60 mg once daily) was initiated after 7 days from onset. The thrombus disappeared on day 16 on TEE (Fig 1, H). D-dimer value was negative throughout. No repeat embolic event afterward was observed by clinical symptoms and head magnetic resonance imaging.

## Discussion

Warfarin is known to be effective in terms of clot solution in the LAA.<sup>1</sup> However, it is not yet established

whether DOAC is also effective in the same purpose, although some case reports are available (Table 1).<sup>2-11</sup>

This is the first report that described intracardiac thrombus disappearance after administration of edoxaban, DOAC with direct Xa inhibitor, in patients with acute ischemic stroke. The effect of edoxaban in the prevention of cardioembolism due to NVAF, as well as the other DOACs, was equivalent to warfarin in a clinical trial, ENGAGE AF-TIMI 48.<sup>12</sup> However, there was no report showing the relationship between edoxaban and resolution of thrombus in the LAA. In the present report, it was suggested that edoxaban had an effect on thrombus resolution in the LAA.

In our cases, TEE demonstrated resolution of thrombus in the LAA about 2 weeks after edoxaban administration without recurrent cardioembolism. Edoxaban is rapidly absorbed after oral intake,<sup>13</sup> and it inhibited thrombin generation, thrombus, and fibrin formation in a concentration-dependent manner.<sup>14,15</sup> We did not measure the concentration of edoxaban in the present cases, because there is no established assay to know appropriate doses of edoxaban in terms of effectiveness and safety in prevention of cardioembolism. This may be a common factor in DOACs because their serum concentration changes in time called “a peak and a trough” are different from that of warfarin.

It is generally known that formation and resolution of thrombus are based on the kinetic balance between coagulation and fibrinolysis in vascular endothelial cells. Inhibitory effect of edoxaban on thrombin generation, therefore, shifts this balance toward fibrinolysis. Furthermore, edoxaban is effective as a strong inhibitor of tissue factor-induced platelet aggregation and clot-bound factor Xa.<sup>16</sup> This may explain, in part, the effect of edoxaban on thrombus resolution in the LAA.

In conclusion, we report 2 cases with favorable effects of edoxaban on the resolution of thrombi in the LAA.

Further clinical studies with edoxaban are required to prove its favorable effect on thrombus.

## References

1. Yasaka M, Yamaguchi T, Miyashita T, et al. Regression of intracardiac thrombus after embolic stroke. *Stroke* 1990;221:1540-1544.
2. Vidal A, Vanerio G. Dabigatran and left atrial appendage thrombus. *J Thromb Thrombolysis* 2012; 34:545-547.
3. Tabata E, Yasaka M, Wakugawa Y, et al. Increase in the size of an intracardiac thrombus during dabigatran therapy (110 mg b.i.d.) in an acute cardioembolic stroke patient. *Cerebrovasc Dis Extra* 2013;3:78-80.
4. Kaku B. Intra-cardiac thrombus resolution after anticoagulation therapy with dabigatran in a patient with mid-ventricular obstructive hypertrophic cardiomyopathy: a case report. *J Med Case Rep* 2013;7:238.
5. Nagamoto Y, Shiomi T, Matsuura T, et al. Resolution of a left ventricular thrombus by the thrombolytic action of dabigatran. *Heart Vessels* 2014;29:560-562.
6. Hammerstingl C, Pötzsch B, Nickenig G, et al. Resolution of giant left atrial appendage thrombus with rivaroxaban. *Thromb Haemost* 2013;109:583-584.
7. Takasugi J, Yamagami H, Okata T, et al. Dissolution of the left atrial appendage thrombus with rivaroxaban therapy. *Cerebrovasc Dis* 2013;36:322-323.
8. Saito S, Tomita H, Kimura Y, et al. Reduced smoke-like echo and resolved thrombus in the left atrium with rivaroxaban therapy in an acute cardioembolic stroke patient. *J Stroke Cerebrovasc Dis* 2014;23:1747-1749.
9. Kawakami T, Kobayakawa H, Ohno H, et al. Resolution of left atrial appendage thrombus with apixaban. *Thromb J* 2013;11:26.
10. Dobashi S, Fujino T, Ikeda T, et al. Use of apixaban for an elderly patient with left atrial thrombus. *BMJ Case Rep* 2014;doi:10.1136/bcr-2014-203870.
11. Ohyagi M, Nakamura K, Watanabe M, et al. Embolic stroke during apixaban therapy for left atrial appendage thrombus. *J Stroke Cerebrovasc Dis* 2015;24:101-102.
12. Robert PG, Chistian TR, Eugene B, et al. Edoxaban versus warfarin in patients with atrial fibrillation. *N Engl J Med* 2013;369:2093-2104.
13. Morishima Y, Kamisato C, Honda Y. Treatment of venous thrombosis with an oral direct factor Xa inhibitor edoxaban by single and multiple administration in rats. *Eur J Phamacol* 2014;742:15-21.
14. Furugohri T, Isobe K, Honda Y, et al. DU-176b, a potent and orally active factor Xa inhibitor: in vitro and in vivo pharmacological profiles. *J Thromb Haemost* 2008;6:1542-1549.
15. Fukuda T, Tsuji N, Honda Y, et al. Comparison of antithrombotic efficacy between edoxaban, a direct factor Xa inhibitor, and fondaparinux, an indirect factor Xa inhibitor under low and high shear rates. *Thromb Haemost* 2011;106:1062-1068.
16. Morishima Y, Honda Y, Kamisato C. Edoxaban, a direct factor Xa inhibitor, inhibits tissue-factor induced human platelet aggregation and clot-bound factor Xa in vitro. Amsterdam: ISTH, 2013.