


Unilateral SREDA in a Patient With Stroke

Zeke M. Campbell¹, Peter W. Kaplan², and Jonathan C. Edwards¹

Clinical EEG and Neuroscience
2017, Vol. 48(1) 72–74
© EEG and Clinical Neuroscience
Society (ECNS) 2016
Reprints and permissions:
sagepub.com/journalsPermissions.nav
DOI: 10.1177/1550059416667193
eeg.sagepub.com


Abstract

Subclinical rhythmic electrographic discharges in adults (SREDA) is a well-known benign EEG phenomenon. However, the occurrence of SREDA is rare, and atypical forms are even more elusive, with only few cases reported in the literature. Herein, we describe a case of a 77-year-old woman with a left middle cerebral artery stroke and paroxysms of rhythmic, sharply contoured activity over the right central head region, mimicking focal seizures on EEG, that were determined to represent atypical SREDA. To our knowledge, no case of SREDA with a contralateral structural cerebral abnormality has been described, and its occurrence offers some limited insight as to the mechanisms underlying this mysterious entity.

Keywords

EEG, subclinical rhythmic electrographic discharges, adults, stroke, atypical SREDA

Received June 7, 2016; revised August 4, 2016; accepted August 5, 2016.

Introduction

Initially described by Naquet et al,¹ subclinical rhythmic electrographic discharges in adults (SREDA) is considered the rarest and most challenging of all epileptiform variants without pathological significance. Credited with coining the term, Westmoreland and Klass² later characterized typical SREDA as diffuse, sharply contoured theta that is maximal in the temporal and parietal regions and occurs during drowsiness or relaxed wakefulness. Typical SREDA is often seen in prolonged runs lasting several minutes and ending abruptly in half the patients.^{1,2} Unusual features of atypical SREDA were later described, and included largely delta frequencies, frontal predominance, notched waveforms, a prolonged duration, occurrence in sleep, and a focal distribution, which has been reported only over the vertex and temporal regions.³ The pattern is distinct from other nonepileptiform variants in that it may show evolution.³ Despite broad agreement that SREDA is benign, little is known about the mechanism generating the pattern, or other clinical implications.

Case Report

A 77-year-old right-handed woman with a history of atrial fibrillation was transferred to the emergency room after receiving tissue plasminogen activator (tPA) for the sudden onset of right hemiparesis, expressive aphasia, and slurred speech. Computed tomography perfusion revealed areas of matched and mismatched perfusion deficits concerning for infarction and at-risk tissue, respectively. Magnetic resonance imaging (MRI) later confirmed extension of a prior infarct within the distribution of the left middle cerebral artery (Figure 1). Routine electroencephalogram (EEG) (Figures 2 and 3) revealed periods of

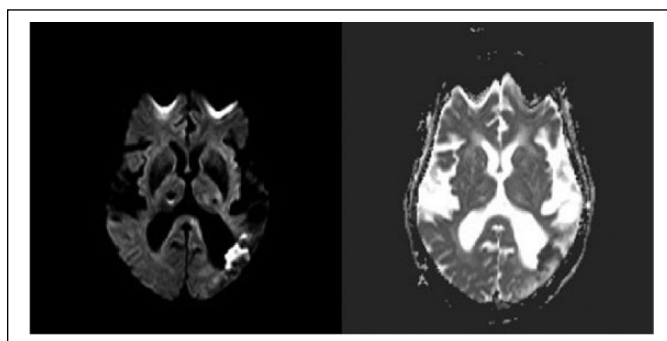


Figure 1. Magnetic resonance imaging revealing left middle cerebral artery infarction. Diffusion-weighted imaging (left) and apparent diffusion coefficient (right).

sharply-contoured theta over the right central head region exceeding a minute, evolving in frequency at times, and starting and ending abruptly, though occasionally in a sputtering fashion. The presence of a posterior dominant rhythm was noted at times during some of the runs. This pattern was observed to be prolonged (>10 seconds) seven times during the course of the 30-minute routine EEG. There was no associated clinical change during these periods, and the rhythm was unaffected by the

¹Department of Neurology, Medical University of South Carolina, Charleston, SC, USA

²Department of Neurology, Johns Hopkins Bayview Medical Center, Baltimore, MD, USA

Corresponding Author:

Zeke M. Campbell, Department of Neurology, Medical University of South Carolina, 96 Jonathan Lucas Street, Charleston, SC 29425, USA.

Email: campbeze@musc.edu

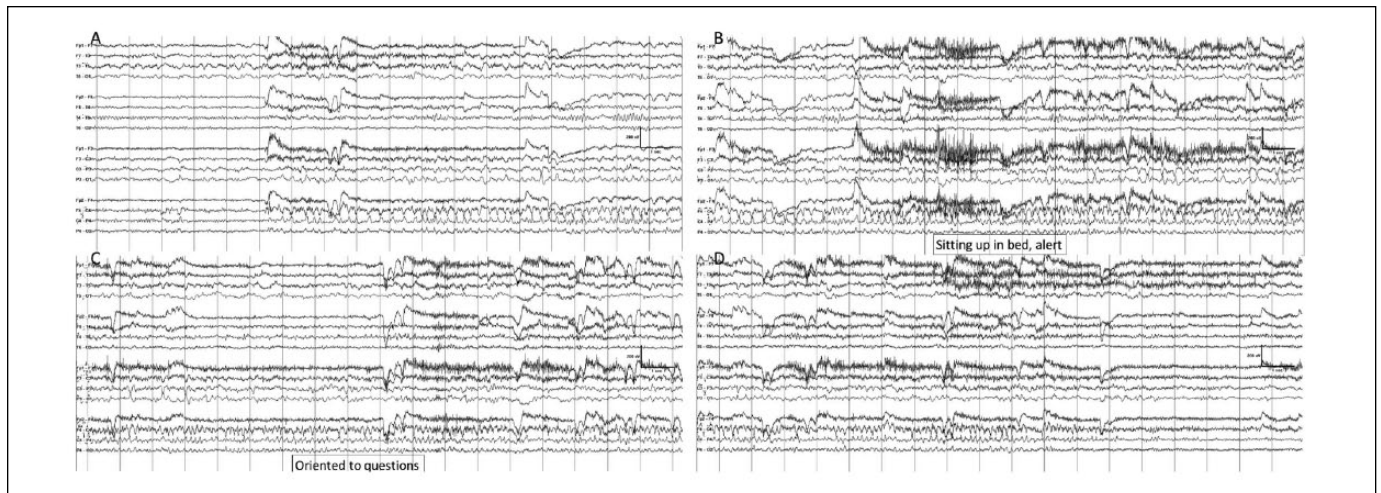


Figure 2. EEG showing atypical SREDA (subclinical rhythmic electrographic discharges in adults) in bipolar montage. EEG recorded in bipolar montage at a sensitivity of 10 μV , high-frequency filter at 50 Hz and low-frequency filter at 1 Hz. (A) The initial portion reveals slowing over the left hemisphere with a normal posterior dominant rhythm present on the right. There is emergence of sharply contoured theta that is maximal over the right central head region, at times with volume conduction to the left posterior parasagittal area. (B) Theta activity persists, during which there are periods where a normal posterior dominant rhythm can be seen on the right. (C) There is evolution of rhythmic theta over the right central head region while patient is sitting in bed alert. Patient answers questions of orientation appropriately. No abnormal movements are noted. (D) There is abrupt termination of rhythmic theta activity and continuation of typical background rhythms.

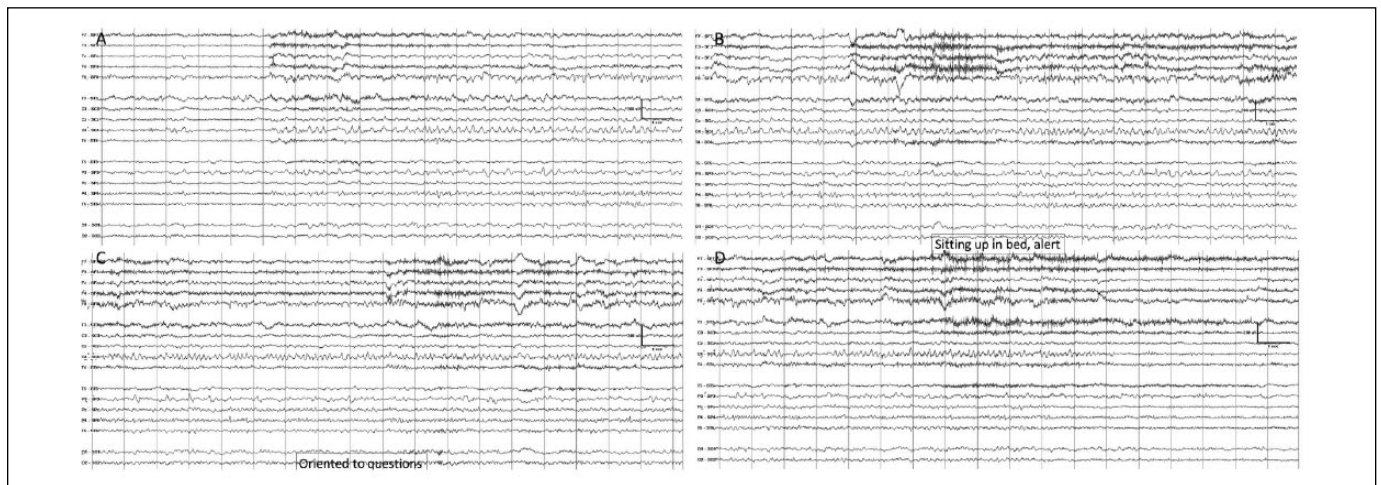


Figure 3. EEG showing atypical SREDA (subclinical rhythmic electrographic discharges in adults) in Laplacian montage. The same EEG segments as Figure 2 in a transverse Laplacian montage at a sensitivity of 10 μV , high-frequency filter at 50 Hz and low-frequency filter at 1 Hz. The EEG demonstrates SREDA activity that is maximal over the right central more than parietal region, although at times there is volume conduction to the left parietal region.

patient opening and closing the contralateral hand. The rhythm was initially interpreted as representing a focal seizure, and the patient was connected to long-term EEG overnight. The runs of electrographic discharges persisted without any associated clinical change and no clinical or electrographic change in response to the administration of levetiracetam. Despite frequent periods of discharges during relaxed wakefulness and drowsiness, the runs abated entirely during sleep. Further inspection of the EEG revealed that, although there was apparent evolution in frequency at times, the rhythmic discharges did not exhibit spatial

evolution. Based on the constellation of finding, the EEG was recategorized accordingly as being an atypical form of SREDA.

Discussion

SREDA is regarded as the most challenging of the benign EEG variants, particularly when cases are atypical, as electrographically it so strongly resembles a seizure, and clinical data may be absent when the EEG is interpreted. SREDA has been previously reported as a monomorphic rhythm,

although digital EEG studies with spectral analyses suggest a mixture of rapidly shifting frequencies with poor spatial and temporal correlation.⁴ Additionally, the use of digital reformatting to Laplacian montages may be useful in distinguishing SREDA from other types of discharges.⁴ Our case confirmed the presence of predominantly unilateral discharges over the central and parietal regions that are predictable of atypical SREDA.

Underlying hypoxia and ischemia have been proposed as having integral roles in the pathophysiology of SREDA,⁵ and cases of SREDA have been described in transient ischemic attack and transient global amnesia.^{6,7} Interestingly, the aforementioned study involving digital EEG analysis consisted of 6 patients, only 1 of whom had a history of cerebrovascular disease, suggesting that ischemia is not requisite, though certainly not exclusionary, for the presence of SREDA.⁴ Our case can neither confirm nor refute the involvement of hypoxia and ischemia as having a role in SREDA, although its absence over the hemisphere with a structural abnormality does seem to indicate that at least some threshold level of cortical function is required for its generation. Some authors have suggested that SREDA relates to transient acute brain dysfunction,⁸ but our patient had SREDA in the hemisphere without acute structural abnormality. Currently, the cerebral genesis of SREDA remains unclear.

This case of unilateral SREDA over the central head region with a contralateral stroke is the first to report a structural abnormality that justifies or explains laterality and underscores the importance of distinguishing benign EEG variants from seizure. It cannot be determined if SREDA would have been bilateral without the infarct, although it seems likely that the structural changes underlay the SREDA. Given that the EEG demonstrated an absence of electrographic discharges over the same area that exhibited a relative paucity of faster frequencies, our findings suggest that the generation of SREDA relies at least in part on cortical connections in the area over which the SREDA is observed. The extent to which SREDA is dependent on, or a function of, an interhemispheric network is not known.

Other similar cases are needed to further clarify our understanding of this rare and confusing epileptiform variant.

Author Contributions

ZMC contributed to conception and design; contributed to acquisition, analysis, and interpretation; drafted manuscript; gave final approval; agrees to be accountable for all aspects of work ensuring integrity and accuracy. PWK contributed to conception; contributed to analysis and interpretation; critically revised manuscript; gave final approval; agrees to be accountable for all aspects of work ensuring integrity and accuracy. JCE contributed to conception and design; contributed to analysis and interpretation; critically revised manuscript; gave final approval; agrees to be accountable for all aspects of work ensuring integrity and accuracy.

Declaration of Conflicting Interests

The author(s) declared no conflicts of interest with respect to the research, authorship, and/or publication of this article.

Funding

The author(s) received no financial support for the research, authorship, and/or publication of this article.

References

1. Naquet R, Louard C, Rhodes J, Vigouroux M. A propos de certaines décharges paroxystiques du carrefour temporo-parieto-occipital. Leur activation par l'hypoxie. *Rev Neurol.* 1961;105:203-207.
2. Westmoreland BF, Klass DW. A distinctive rhythmic EEG discharge of adults. *Electroencephalogr Clin Neurophysiol.* 1981;51:186-191.
3. Westmoreland BF, Klass DW. Unusual variants of subclinical rhythmic electroencephalographic discharge of adults. *Electroencephalogr Clin Neurophysiol.* 1997;102:1-4.
4. O'Brien TJ, Sharbrough FW, Westmoreland BF, Busacker NE. Subclinical rhythmic electrographic discharges of adults (SREDA) revisited: a study using digital EEG analysis. *J Clin Neurophysiol.* 1998;15:493-501.
5. Thomas P, Migneco O, Darcourt J, Chatel M. Single photon emission computed tomography study of subclinical rhythmic electrographic discharge in adults. *Electroencephalogr Clin Neurophysiol.* 1992;83:223-227.
6. Silva DF, Zanoteli E, Lima MM, Anghinah R, Lima JG. Subclinical rhythmic electrographic discharge in adults: an atypical evolution. *Arq Neuropsiquiatr.* 1995;53:266-269.
7. Brigo F, Bongiovanni LG, Fiaschi A. Subclinical rhythmic electrographic discharges of adults and transient global amnesia: a causal or casual association? *Epileptic Disord.* 2010;12:321-324.
8. Begum T, Ikeda A, Takahashi J, et al. Clinical outcome of patients with SREDA (subclinical rhythmic EEG discharge of adults). *Intern Med.* 2006;45:141-144.