

rTMS reduces cortical imbalance associated with visual hallucinations after occipital stroke



Sara A. Rafique, MA, MSc
John R. Richards, MD
Jennifer K.E. Steeves,
PhD

Correspondence to
Dr. Steeves:
steeves@yorku.ca

ABSTRACT

Objective: To investigate the efficacy of multiday repetitive transcranial magnetic stimulation (rTMS) to the occipital cortex in a patient with continuous visual phosphene hallucinations for more than 2 years following occipital stroke.

Methods: Low-frequency rTMS (1 Hz) was applied to the lesion site for 30 minutes daily over 5 consecutive days. Functional MRI (fMRI) was performed before and after rTMS treatment.

Results: Increased application of rTMS corresponded with a reduction in intensity of visual phosphene hallucinations and was reflected in altered blood oxygen level-dependent signal. fMRI revealed focal excitatory discharges at the border of the lesion, highlighting the origin of phosphenes. Post-rTMS, rTMS did not simply suppress activity in the patient but rather redistributed the previously imbalanced cortical activity not only at the stimulation site but in remote cortical regions so that it more closely resembled that of controls.

Conclusions: This case is rare in its presentation of chronic continuous visual phosphene hallucinations following occipital stroke. We present a case of multiday application of rTMS to visual cortex and demonstrate that rTMS provides a valuable therapeutic intervention in modulating visual hallucinations following occipital damage.

Classification of evidence: This study provides Class IV evidence in a single-case report that multiday rTMS reduces intrahemispheric and interhemispheric imbalance and associated visual phosphene hallucinations following occipital stroke. *Neurology*® 2016;87:1-8

GLOSSARY

BOLD = blood oxygen level-dependent; **FDR** = false discovery rate; **FFA** = fusiform face area; **fMRI** = functional MRI; **FoV** = field of view; **FPO** = face-place-object; **LG** = lingual gyrus; **LO** = lateral occipital area; **OFA** = occipital face area; **PPA** = parahippocampal place area; **rTMS** = repetitive transcranial magnetic stimulation; **TE** = echo time; **TOS** = transverse occipital sulcus; **TR** = repetition time.

Visual hallucinations can be an adverse effect of damage to the occipital cortex (e.g., injury from stroke) in otherwise cognitively healthy individuals.^{1,2} Visual hallucinations can be either simple (phosphenes or unformed) or complex (formed images); however, simple phosphenes are more commonly associated with mesial occipital lobe damage.

The experience of chronic visual hallucinations following visual pathway damage is both mentally and physically exhausting for patients, leading to added psychological consequences that interfere with quality of life.^{2,3} They are frequently poorly managed due to poor understanding of pathogenesis. At present, there are no standard pharmacologic treatment protocols to alleviate visual hallucinations subsequent to visual pathway damage.

A single application of low-frequency repetitive transcranial magnetic stimulation (rTMS) has been reported to temporarily cease intermittent visual hallucinations in a patient following bilateral ischemic damage to occipital cortex.⁴ The aim of the present study was to investigate the efficacy of multiday low-frequency rTMS in modulating continuous phosphene hallucinations in a patient following right occipital stroke. We performed functional MRI (fMRI) pre- and post-rTMS and predicted changes in blood oxygen level-dependent (BOLD) signal post-rTMS. Following stroke,

Supplemental data
at Neurology.org

From the Centre for Vision Research and Department of Psychology (S.A.R., J.K.E.S.), York University, Toronto, Canada; and Department of Emergency Medicine (J.R.R.), University of California, Davis, Medical Center, Sacramento.

Go to Neurology.org for full disclosures. Funding information and disclosures deemed relevant by the authors, if any, are provided at the end of the article.

the interhemispheric cortical balance becomes modified between the ipsilesional and contralesional hemispheres,^{5,6} resulting in abnormal neuronal activity, and can be targeted with rTMS.⁶ rTMS disinhibits interhemispheric transcallosal interactions, a process essential for stroke rehabilitation.⁶ We also perform fMRI on an age-matched control sample to enable statistical comparison to a neurologically intact group.

METHODS Standard protocol approvals, registrations, and participant consents. The study was approved by York University's Office of Research Ethics. All individuals gave informed written consent.

Participants. Patient. We evaluated a 31-year-old woman experiencing continuous phosphene hallucinations within an incomplete congruous left homonymous hemianopia (figure 1A) 2.5 years after the onset of right subacute occipital lobe stroke (figure 1B). The phosphene hallucinations began at stroke onset and were described as moving white/gray vibrating images of shattered glass and small-medium circular lights within the scotoma. Occasional high-frequency lightning bolts and irregular zigzags were perceived migrating inferolateral within the scotoma into the normal visual field. Phosphenes were more intense at the relative (incomplete damage) defect, accompanied by macropsia and general distortion. The patient found the constant need to differentiate real percepts and phosphene hallucinations confusing and exhausting despite full awareness the hallucinations were not real. The phosphene hallucinations were perceived at all times; however, intensity increased

with stress, lack of sleep, or increasing light intensity, and intensity decreased in the dark or with eyes closed. The phosphene hallucinations were debilitating, interfering with sleep, vision, and quality of life. The e-Methods at Neurology.org contain a detailed patient case history.

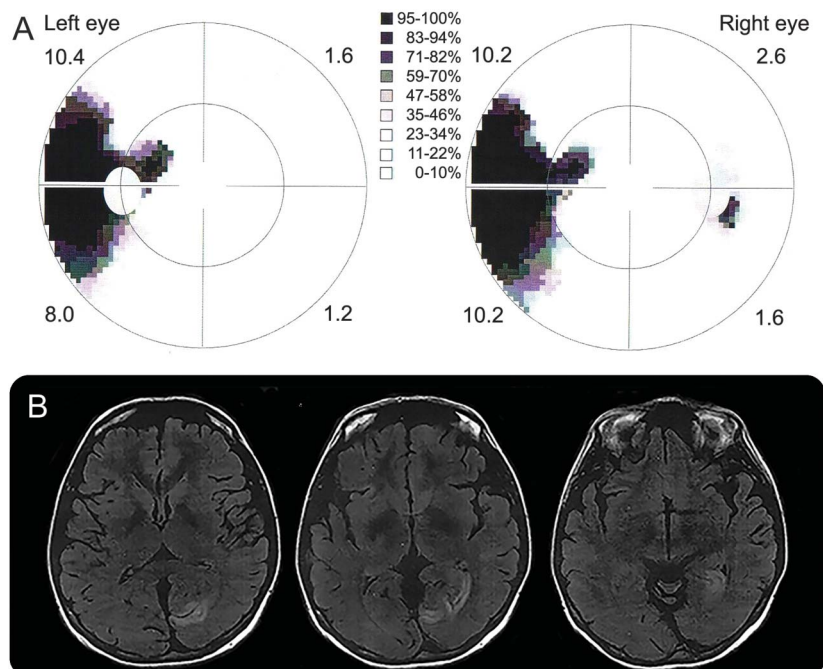
The patient had normal foveal vision (>0.2 logMAR) and all other ophthalmic findings were unremarkable. There were no known contraindications to MRI and TMS.

Healthy controls. Eight healthy women (mean age 29 years) with no history of neurologic disorders and no known contraindications to MRI were recruited. All controls had normal or corrected-to-normal vision (>0.2 logMAR) and otherwise normal ophthalmic findings.

Experimental design overview. The patient underwent the following: (1) perimetry and other clinical vision tests, (2) pre-rTMS MRI, (3) sham and vertex rTMS, (4) 5 consecutive days of rTMS, and (5) post-rTMS MRI. Healthy controls underwent (1) and (2) only.

MRI. Stimuli and procedure. We performed 2 fMRI experiments. The patient self-reported increases in phosphene hallucinations with increasing brightness of visual input and a corresponding decrease in phosphene hallucinations under reduced or dark visual environments. A phosphene localizer was used to delineate cortical origins of the hallucinations. It consisted of 5 full-screen 30-second blocks of white stimulus interleaved with 5 full-screen 30-second blocks of black stimulus, with a continuous central fixation (figure e-1A). A gray screen with central fixation appeared for 30 seconds at the start and finish of the run. Each run lasted 6 minutes and was repeated twice. During the phosphene localizer, the patient indicated change in intensity of perceived phosphene hallucinations using an MRI-compatible response button box. The phosphene localizer was performed first in the patient to prevent any confounds in phosphene hallucinations resulting from viewing previous experimental visual stimuli.

Figure 1 The patient's visual field plot and occipital stroke lesion



(A) The patient's visual field plots show an incomplete contralateral congruous homonymous hemianopia. (B) T2-weighted MRI taken at the time of stroke shows the location of occipital lesion at different slices. MRI are displayed in neurologic convention.

A face-place-object (FPO) localizer was performed because the lesion was located in primary visual cortex, which could result in changes in remote visual processing networks connected to both the lesion site and peri-infarct regions. Much of this network contributes to the processing of specialized visual stimuli, mainly faces, places, and objects, which are also implicated in complex visual hallucinations.⁷ The purpose of the FPO localizer was to delineate these regions and measure remote activity associated with the lesion and/or changes with rTMS. The FPO localizer consisted of 3 different blocks, each with 16 images: (1) faces (male and female), (2) places (natural and non-natural scenes), (3) objects (natural and manmade) (figure e-1B). Epochs containing 3 blocks of the 3 categories of stimuli were repeated 6 times in a counterbalanced order to minimize first-order carryover effects. Each image was presented for 900 milliseconds with 100 milliseconds interstimulus interval, and images were presented without repetition. A central fixation cross appeared for 16 seconds at the start and finish of the run and between epochs. Each run lasted 6 minutes 52 seconds and was repeated twice.

Localizers were performed immediately prior to and after rTMS treatment ceased. Control participants underwent both localizers to enable comparison. All imaging was acquired in a dark room.

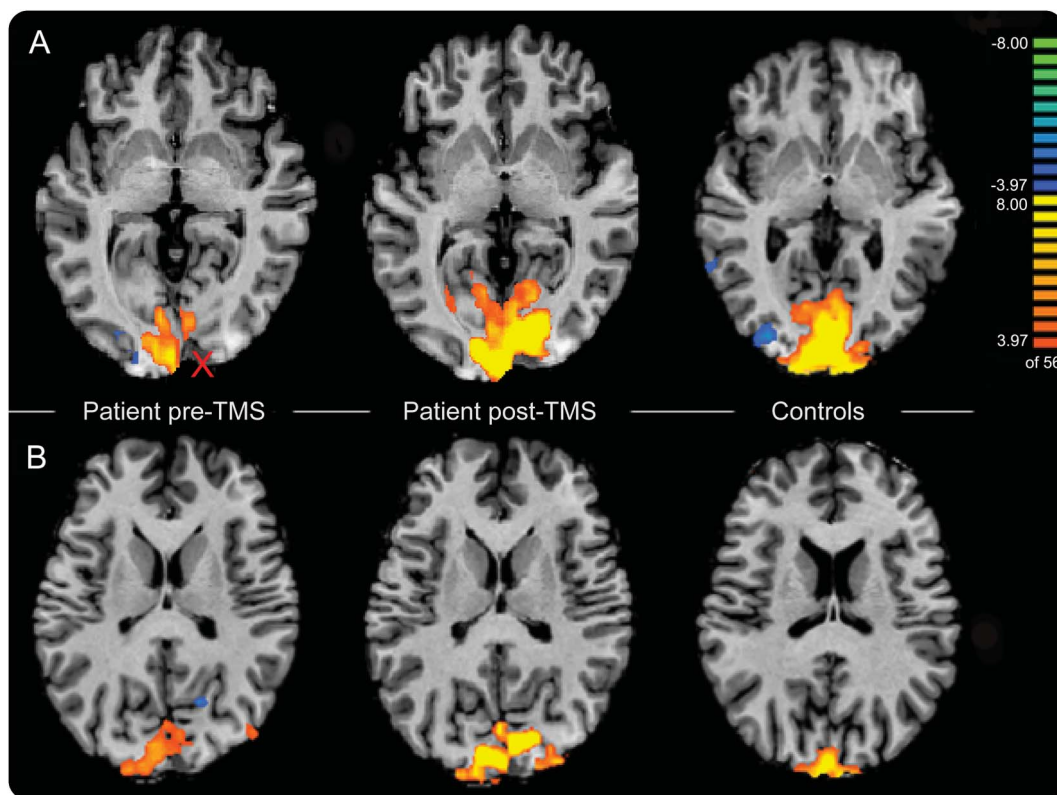
Image acquisition. Functional and anatomical images were acquired with a 3T Siemens Magnetom Tim Trio magnetic resonance scanner (Siemens, Erlangen, Germany), using BOLD fMRI imaging. Functional volumes were acquired using a Siemens 32-channel high-resolution brain array coil and echoplanar

imaging with a T1-weighted sequence (32 contiguous axial slices, in-plane resolution 2.5×2.5 mm, slice thickness 3.0 mm, imaging matrix 96×96 , repetition time [TR] 2,000 milliseconds, echo time [TE] 30 milliseconds, flip angle 90° , field of view [FoV] 240 mm). Structural images were acquired after functional scans with a T1 magnetization-prepared rapid gradient echo imaging sequence (number of slices 192, in-plane resolution 1×1 mm, slice thickness 1.0 mm, imaging matrix 256×256 , TR 1,900 milliseconds, TE 2.5 milliseconds, inversion time 900 milliseconds, flip angle 9° , FoV 256 mm).

rTMS procedure. Low-frequency rTMS. Only the patient underwent rTMS treatment. The demarcation between the absolute and relative visual field defect is a functional representation of intact or partially intact neurons with residual recovery of function (figure 1A). This suggested disorganized activity from surviving or partially damaged neurons within or around the lesion was confirmed from the restricted disorganization of activity at the lesion border evident from fMRI analysis compared to controls (figure 2). Therefore, we chose the lesion as the target site for rTMS in order to reach the partially damaged neurons.

The lesion was mapped on the patient's anatomical scan and 3D reconstructed cortical surface usingBrainsight software (Rogue Research, Montréal, Canada). The spatial relationship between the reference points from the MRI and those on the patient's head were coregistered using a Polaris infrared tracking system (Northern Digital Instruments, Kitchener, Canada) to enable targeted rTMS to the disorganized activity at the border

Figure 2 Phosphene localizer (white > black) for the patient pre-repetitive transcranial magnetic stimulation (rTMS), the patient post-rTMS, and control average



(A) Cortical activity at the lingual gyrus. X marks the approximate location of the rTMS target site. A benign subarachnoid cyst is visible under the X, and is not to be confused with the lesion. (B) Cortical activity at the cuneus. Activation to white stimuli is indicated in orange/yellow and activation to black stimuli is indicated in blue/green; $q < 0.05$. Images are displayed in neurologic convention.

of the lesion. The image-guided stereotaxic system enables accurate coil position over target sites and tracking of the coil with respect to the patient's head during stimulation that can be continuously monitored and corrected in real time. A Magstim Rapid² Stimulator and a 70-mm diameter figure-of-eight coil (Magstim, Whitland, Wales, UK), which provides focal stimulation, were used to deliver the stimulation pulses to the targeted stimulation site.

A low-frequency pulse (1 Hz) was delivered at 85% of maximum stimulator output (110% visible twitch motor threshold⁸) for 30 minutes (1,800 pulses). Due to the continuous and variable perception of phosphene hallucinations, motor instead of phosphene threshold measurements were chosen. Low-frequency rTMS is typically suppressive and was chosen to reduce disorganized activity. Prior to stimulation of the target site, 2 separate control conditions were performed, rTMS to vertex and sham rTMS (coil held orthogonal to the skull and no pulses enter the brain), during which the patient reported no effect. rTMS treatment was then performed daily over 5 days to the

target site at the posterior tip of the lesion (Talairach coordinates, $x = 14$, $y = -75$, $z = 9$; ~14 mm deep), which was within penetration limits (10–20 mm).⁹

A daily subjective log of rTMS effects on phosphene hallucinations was recorded during and after vertex, sham, and each rTMS session. We recorded the length of time the effects persisted and any changes in perception throughout the day. Subjective changes were reported as a percentage decrease in the self-reported average baseline intensity of phosphene hallucinations that were perceived prior to beginning rTMS treatment. The patient reported the daily average baseline intensity to be 70% (relative to worst intensity previously experienced).

Data analyses. Analyses of fMRI were performed using Brain Voyager QX (2.8) (Brain Innovation, Maastricht, the Netherlands). Preprocessing steps are described in the e-Methods.

Phosphene localizer. A whole-brain fixed-effects analysis was performed using a linear balanced contrast (white > black), false discovery rate (FDR)-corrected single-voxel threshold of $q <$

Table 1 Phosphene localizer results for the patient

Region	Brodmann area	White > black stimuli			Black > white stimuli		
		x	y	z	x	y	z
Patient pre-rTMS							
R lingual gyrus	17				23	-82	3
R lingual gyrus	18	12	-76	4			
L lingual gyrus	17	-7	-89	4			
L lingual gyrus	18	-21	-71	-9			
R cuneus	18	1	-80	16			
L cuneus	18	-6	-87	12			
L middle occipital gyrus	18				-27	-82	-8
R middle temporal gyrus	19	35	-80	22			
L fusiform gyrus	19				-25	-84	-13
R anterior vermis (Culmen)		16	-55	-10			
L anterior vermis (Culmen)					35	-51	-15
Patient post-rTMS							
R lingual gyrus	18	13	-68	1			
L lingual gyrus		-17	-76	3			
R middle occipital gyrus	19	27	-83	14			
R cuneus	19	10	-83	26			
L cuneus	18	-8	-86	14			
R subgyral	37	49	-48	-5			
R superior parietal lobule	7	19	-66	52			
L superior parietal lobule	7	19	-66	54			
L inferior parietal lobule	40	-37	-43	45			
R precentral gyrus	6	51	-12	28			
L precentral gyrus	6	-55	-4	34			
L postcentral gyrus	3	-49	-15	50			
R posterior lobe		28	-52	-13			

Abbreviation: rTMS = repetitive transcranial magnetic stimulation.

Clusters show significant differences in cortical activation between white and black stimuli for the patient. The columns list (from left to right) the anatomical regions showing clusters of activity ($q < 0.05$), the Brodmann area, and (mean) Talairach coordinates of the cluster.

0.05, to compare (1) patient (pre- and post-rTMS separately) and control activation for white and black event predictors. Subtraction analysis [β -difference maps] was performed for the following comparisons: (2) patient's pre- vs post-rTMS phosphene localiser activity; and (3) patient (pre- and post-rTMS separately) vs control phosphene localiser activity. Subtraction of maps was performed for white and black event predictors separately, for voxels above selected β thresholds of >0.5 , where β values quantify the level of cortical activity. The e-Methods provide information on the patient's subjective button responses that were not included for further analyses.

FPO localizer. Regions known to be involved in processing of faces, places, and objects (a priori regions) were defined in all individuals independently. The a priori face preferential regions included the fusiform face area (FFA) and occipital face area (OFA). The scene preferential regions included the transverse occipital sulcus (TOS), parahippocampal place area (PPA), and lingual gyrus (LG). The object preferential region involved the

lateral occipital area (LO). A priori regions were defined using a linear balanced contrast and were identified individually for each participant by determining the peak selective activation for the region in question, FDR-corrected single-voxel threshold of $q < 0.05$. Activity within a priori regions was quantified from the event-related time course as β weights. We used the modified t test (2-tailed tests) developed for single-case studies to compare patient to controls.^{10,11} The e-Methods provide a detailed description of identifying the a priori regions.

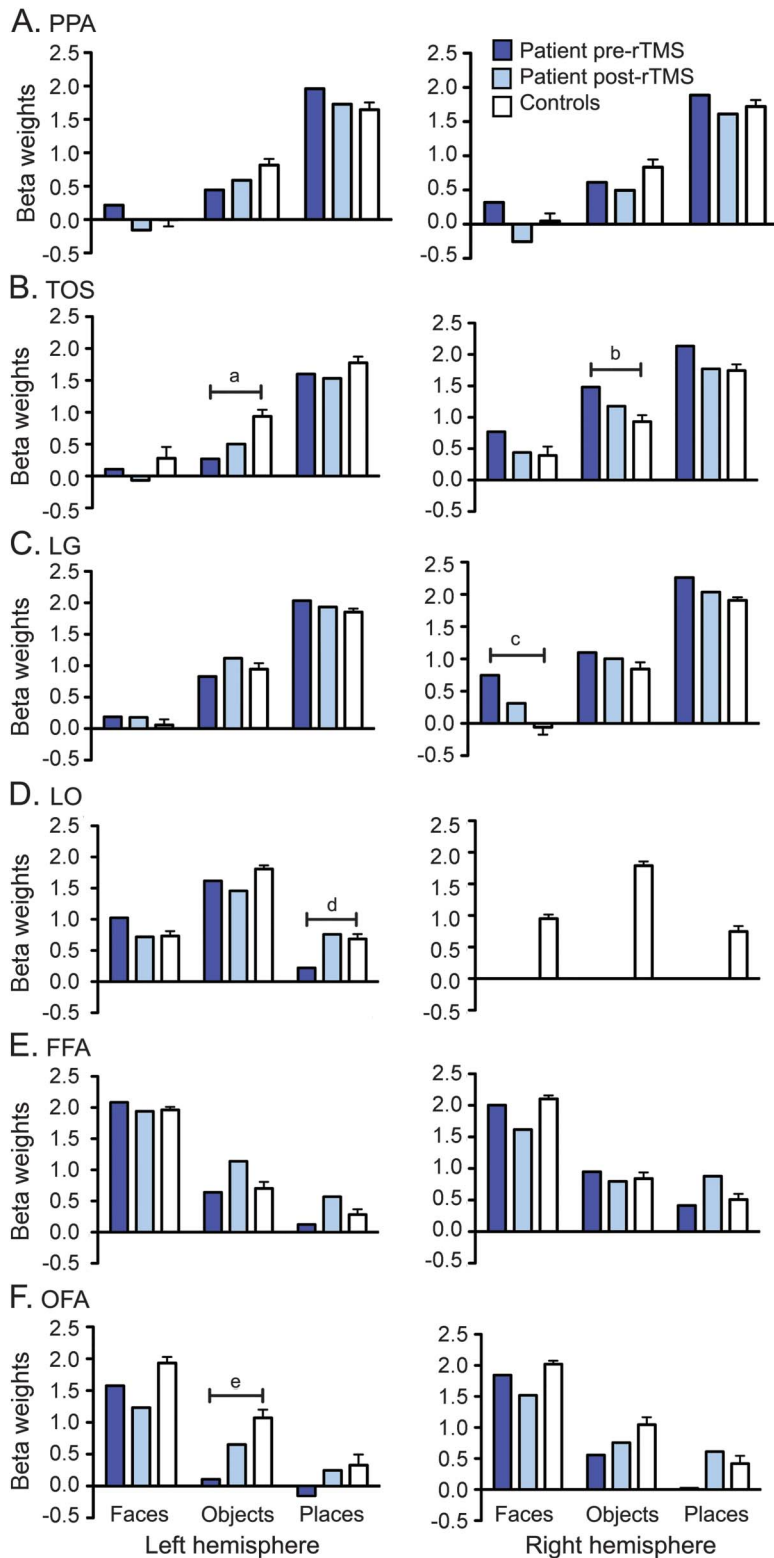
RESULTS Subjective perception of phosphene hallucinations. The patient reported a gradual reduction in phosphene hallucinations with increased application of rTMS. Effects summated with increased time of rTMS application during each session. With each new day of rTMS treatment, hallucinations were modulated faster and effects continued to summate

Table 2 Phosphene localizer results for controls

Region	Brodmann area	White > black stimuli			Black > white stimuli		
		x	y	z	x	y	z
R lingual gyrus	17	14	-92	-2			
R lingual gyrus	18	13	-71	-3			
L lingual gyrus	17	-7	-87	-2			
L lingual gyrus	18	-3	-68	-2			
R cuneus	18	4	-85	22			
L cuneus	19	-4	-87	26			
R middle occipital gyrus	18				32	-79	2
L middle occipital gyrus	19				-44	-71	4
R inferior occipital gyrus	18				34	-80	-1
L inferior occipital gyrus	18				-28	-88	-12
R middle temporal gyrus	22				60	-45	5
R fusiform gyrus	19				34	-78	-12
R fusiform gyrus	37				42	-59	-7
L superior parietal lobule	7	-33	-70	43			
R inferior parietal lobule	7	40	-60	44			
R inferior parietal lobule	39	40	-64	42			
R precentral gyrus	6	43	-8	52			
L precentral gyrus	6	-40	-12	36			
L precentral gyrus	4	-43	-11	45			
L postcentral gyrus	3	-51	-15	45			
R superior frontal gyrus	10	26	55	18			
R middle frontal gyrus	8	41	26	46			
R middle frontal gyrus	9	47	34	32			
L middle frontal gyrus	10	-37	54	9			
R inferior frontal gyrus	44	50	13	19			
R posterior lobe		15	-79	-17	28	-79	-20
L posterior lobe		-12	-75	-20			

Clusters show significant differences in cortical activation between white and black stimuli for age-matched controls. The columns list (from left to right) the anatomical regions showing clusters of activity ($q < 0.05$), the Brodmann area, and (mean) Talairach coordinates of the cluster.

Figure 3 A priori analysis of the face-place-object localizer



Differences in cortical activation for preferential and nonpreferential processing are observed between the patient and controls. Right lateral occipital area (LO) activation was not observed for the patient. Data are presented as mean \pm SEM for controls. Preferential coding of scene images is performed in the following regions: (A) parahippocampal place area (PPA) located in parahippocampal gyrus, (B) transverse occipital sulcus (TOS) (also known as occipital place area), and (C) lingual gyrus (LG) located in visual cortex. (D) LO located in lateral occipital cortex preferentially codes object images. (E) Fusiform face area (FFA) located in fusiform gyrus and (F) occipital face area (OFA) located in inferior occipital gyrus preferentially code faces.

and last longer. As a result, with each new day, the patient also reported an overall improvement in well-being, described as being less mentally and physically exhausted (figure e-2). Effects of rTMS were maintained after discontinuation of stimulation with a gradual linear return to baseline intensity. The perception of phosphene hallucinations did not completely cease during the treatment; however, they were reduced to less than 15% intensity (figure e-2). In addition, the patient reported minimal distortion and macropsia after rTMS treatment; however, this reduction was not quantified.

MRI. Phosphene localizer. The anatomical regions with significant differences in activation between white and black stimuli (white > black) for the patient (pre- and post-rTMS) and controls are detailed in tables 1 and 2, respectively.

Figure 2 highlights the most notable difference in patterns of cortical activity, not only between the patient and controls, but a remarkable difference is seen between the patient pre- and post-rTMS. Pre-rTMS, a greater concentration of diffuse activity is observed in the contralesional hemisphere at the lingual gyrus and cuneus, while ipsilesional activity was focal to the calcarine sulcus and anterior to the lesion in the patient. Unlike the patient, controls did not show activation at the lingual gyrus in dark (black stimuli) viewing conditions.

Subtraction analysis of the phosphene localizer providing β difference maps for the patient pre- and post-rTMS, the patient pre-rTMS and controls, and for the patient post-rTMS and controls are shown in tables e-1, e-2, and e-3, respectively.

FPO localizer. The a priori analysis and the modified *t* test results are shown in figure 3. Differences are observed in processing requirements allocated within the regions for preferential and nonpreferential task-specific processing between the patient and controls. Compared to controls, pre-rTMS the patient displayed greater selectivity to places in the scene preferential region left TOS, but reduced place selectivity (greater nonpreferential processing) in the right TOS and right lingual gyrus. Within the left LO, typically an object preferential region, pre-rTMS the patient showed greater nonpreferential processing of faces and reduced nonpreferential processing of places compared to controls. Greater face selectivity was observed in the bilateral face preferential region OFA. Post-rTMS, in some

^at = -2.654, *p* = 0.033, effect size ($Z_{\text{case-controls}} [cc]$) = -2.815. ^bt = 2.095, *p* = 0.074, effect size (Z_{CC}) = 2.222. ^ct = 2.386, *p* = 0.048, effect size (Z_{CC}) = 2.531. ^dt = -2.183, *p* = 0.065, effect size (Z_{CC}) = -2.315. ^et = -2.525, *p* = 0.039, effect size (Z_{CC}) = -2.678. rTMS = repetitive transcranial magnetic stimulation.

cases, there was redistribution of activity in preferential and nonpreferential processing towards a similar level of activation to that of controls.

DISCUSSION Using rTMS, we greatly reduced the perception of phosphenes in our patient with chronic continuous phosphene hallucinations following occipital stroke. These effects summated daily and outlasted stimulation. rTMS did not simply reduce activity in the previously disorganized regions of activity contributing to the perception of phosphene hallucinations, but redistributed imbalanced activity throughout the brain to a level similar to that of controls, presumably through disinhibition of intrahemispheric and interhemispheric interactions.

Several differences in cortical activity were observed between the patient pre-rTMS and controls (tables 1, 2, and e-2) that implicate these regions in the origins of the patient's phosphene hallucinations. Electrical stimulation to V1, the calcarine sulcus, and the visual association area Brodmann area 18 induces the perception of phosphenes,^{12,13} supporting our results and the involvement of these regions (figure 2) in the genesis of phosphene hallucinations in this patient.

Activation in the anterior vermis of the cerebellum in the patient pre-rTMS when viewing bright and dark stimuli (tables 1 and 2) is consistent with its role in mental imagery.¹⁴ The cerebellum also shows connectivity to the dorsal visual stream and visual cortices, as well as involvement in visual attention to moving stimuli.¹⁵

Another explanation for visual hallucinations is that areas involved in memory retrieval including category-specific visual areas may release percepts from memory when sensory impulses that are excluded from consciousness are no longer inhibited following damage.¹³ The middle temporal gyrus is implicated in object recognition memory¹⁶ and is consistent with differences of activation observed in the middle temporal gyrus between the patient pre-rTMS and controls (tables 1 and 2).

The claustrum regulates communication across the brain via cholinergic mechanisms. Cholinergic input inhibits GABAergic inhibitory input from the reticular nucleus.¹⁷ Release of visual association cortex with loss of cortico-cortical inputs after stroke¹⁸ alters cortical activity via reticular activating system by decreasing cholinergic input that is linked to hallucinations.¹⁹ The involvement of the claustrum in the patient pre-rTMS (table e-2) is consistent with evidence of its involvement in visual hallucinations.

These regions may be directly involved in the origin of hallucinations (the cause) or may be indirectly activated as a function-specific response to the continuous perception of the recurrent phosphene hallucinations (the effect). Ultimately, aberrant processes result in pathologic feedback between cortical regions.^{1,19}

Following 5 days of consecutive application of rTMS to the visual cortex in the patient, a balance of activation was observed across the brain post-rTMS, both interhemispherically and intrahemispherically (figure 2). This included deactivation of regions in the patient pre-rTMS that were not observed in controls, or conversely activation of regions that were observed in controls but not in the patient pre-rTMS (tables 1, 2, e-2, and e-3). Thus, post-rTMS activation in the patient was similar to neural processes in controls within these regions.

A priori analysis of the FPO localizer following rTMS revealed neural resources were transferred between preferential and nonpreferential selectivity of regions. Although controls did not undergo rTMS in this study, our previous research shows no changes in stimulus category selectivity in these regions following rTMS to the visual cortex in healthy controls.^{20,21}

The redistribution of activation across the brain with rTMS demonstrates rTMS was not restricted in its effects to the targeted region in the occipital lobe but rather led to a more global redistribution of activity in remotely connected regions.

Nonetheless, the patient continued to demonstrate some differences post-rTMS compared with controls (table e-3). The residual activity, particularly at the border of the lesion, demonstrates persistent neuronal firing, which corresponds to the continued yet greatly reduced perception of phosphene hallucinations after rTMS treatment.

The pattern of cortical activity following rTMS is not perfectly equivalent to that of controls. Similarly, we do not see the typical inhibition of activity at the stimulation site following rTMS that we observe in healthy controls.^{21,22} In the deafferented cortex, there is an increase of membrane resistance that may cause an excitability of the involved regions,²³ therefore reducing the susceptibility to inhibition. It is likely that remote stimulation effects and restoration to normal function were limited due to impaired inhibitory mechanisms in the patient.

In order to overcome limitations of a single-case study, our future work will test a larger sample and include more objective fMRI testing. To maximize functional recovery and prevent the development of abnormal perceptual processing, it is likely that rTMS treatment needs to be applied as soon as possible poststroke within the plasticity window for recovery.^{24,25} Due to our limited time with this patient, we were unable to further refine stimulation intensity and duration in order to achieve maximal phosphene suppression. Our future work will refine these stimulation parameters.

A number of conditions present with secondary visual hallucinations (e.g., Parkinson disease, schizophrenia, Charles Bonnet syndrome) that share analogous mechanisms of dysfunction of mutually

implicated neurotransmitters, interhemispheric imbalance, and involvement of common brain regions. Neuromodulation with rTMS could provide a valuable tool for effective treatment of visual hallucinations in these populations.

AUTHOR CONTRIBUTIONS

Sara Rafique: study concept and design, acquisition of data, analysis and interpretation of data, writing of manuscript. John Richards: study concept, critical revision of manuscript for intellectual content. Jennifer Steeves: study concept and design, study supervision, critical revision of manuscript for intellectual content.

ACKNOWLEDGMENT

The authors thank all the participants for their contributions and Dr. Frances Wilkinson for the use of her perimeter.

STUDY FUNDING

Study funded by the Natural Sciences and Engineering Research Council of Canada (grant 327588) and the Canada Foundation for Innovation (grant 12807).

DISCLOSURE

S. Rafique and J. Richards report no disclosures relevant to the manuscript. J. Steeves receives royalties from the publication of the book *Plasticity in Sensory Systems*. Go to Neurology.org for full disclosures.

Received February 25, 2016. Accepted in final form June 21, 2016.

REFERENCES

1. Anderson SW, Rizzo M. Hallucinations following occipital lobe damage: the pathological activation of visual representations. *J Clin Exp Neuropsychol* 1994;16:651–663.
2. De Haan EH, Nys GM, van Zandvoort MJ, Ramsey NF. The physiological basis of visual hallucinations after damage to the primary visual cortex. *Neuroreport* 2007;18:1177–1180.
3. Cox TM, ffytche DH. Negative outcome Charles Bonnet syndrome. *Br J Ophthalmol* 2014;98:1–4.
4. Merabet LB, Kobayashi M, Barton J, Pascual-Leone A. Suppression of complex visual hallucinatory experiences by occipital transcranial magnetic stimulation: a case report. *Neurocase* 2003;9:436–440.
5. Liepert J, Hamzei F, Weiller C. Motor cortex disinhibition of the unaffected hemisphere after acute stroke. *Muscle Nerve* 2000;23:1761–1763.
6. Traversa R, Cicinelli P, Bassi A, Rossini PM, Bernardi G. Mapping of motor cortical reorganization after stroke: a brain stimulation study with focal magnetic pulses. *Stroke* 1997;28:110–117.
7. ffytche DH, Howard RJ, Brammer MJ, David A, Woodruff P, Williams S. The anatomy of conscious vision: an fMRI study of visual hallucinations. *Nat Neurosci* 1998;1:738–742.
8. Pridmore S, Fernandes Filho JA, Nahas Z, Liberato C, George MS. Motor threshold in transcranial magnetic stimulation: a comparison of a neurophysiological method and a visualization of movement method. *J ECT* 1998;14:25–27.
9. Zangen A, Roth Y, Voller B, Hallett M. Transcranial magnetic stimulation of deep brain regions: evidence for efficacy of the H-coil. *Clin Neurophysiol* 2005;116:775–779.
10. Crawford JR, Garthwaite PH. Investigation of the single case in neuropsychology: confidence limits on the abnormality of test scores and test score differences. *Neuropsychologia* 2002;40:1196–1208.
11. Crawford JR, Garthwaite PH, Azzalini A, Howell DC, Laws KR. Testing for a deficit in single-case studies: effects of departures from normality. *Neuropsychologia* 2006;44:666–677.
12. Foerster O. The cerebral cortex in man. *Lancet* 1931;2:309.
13. Lance JW. Simple formed hallucinations confined to the area of a specific visual field defect. *Brain* 1976;99:719–734.
14. Grealy MA, Lee DN. An automatic-voluntary dissociation and mental imagery disturbance following a cerebellar lesion. *Neuropsychologia* 2011;49:271–275.
15. Kellermann T, Regenbogen C, De Vos M, Mößnang C, Finkelmeyer A, Habel U. Effective connectivity of the human cerebellum during visual attention. *J Neurosci* 2012;32:11453–11460.
16. Yonelinas AP, Hopfinger JB, Buonocore MH, Kroll NEA, Baynes K. Hippocampal, parahippocampal and occipital-temporal contributions to associative and item recognition memory: an fMRI study. *Neuroreport* 2001;12:359–363.
17. Wilson JR. Circuitry of the dorsal lateral geniculate nucleus in the cat and monkey. *Acta Anat* 1993;147:1–13.
18. Jones EG, Powell TPS. An anatomical study of converging sensory pathways within the cerebral cortex of the monkey. *Brain* 1970;93:793–820.
19. Manfred M, Andermann F. Complex visual hallucinations: clinical and neurobiological insights. *Brain* 1998;121:1819–1840.
20. Mullin CR, Steeves JK. Consecutive TMS-fMRI reveals an inverse relationship in BOLD signal between object and scene processing. *J Neurosci* 2013;33:19243–19249.
21. Rafique SA, Solomon-Harris LM, Steeves JK. TMS to object cortex affects both object and scene remote networks while TMS to scene cortex only affects scene networks. *Neuropsychologia* 2015;79:86–96.
22. Caparelli EC, Backus W, Telang F, et al. Simultaneous TMS-fMRI of the visual cortex reveals functional network, even in absence of phosphene sensation. *Open Neuroimaging J* 2010;4:100–110.
23. Prince DA, Tseng GF. Epileptogenesis in chronically injured cortex: in vitro studies. *J Neurophysiol* 1993;69:1276–1291.
24. Kasten E, Wüst S, Behrens-Baumann W, Sabel BA. Computer-based training for the treatment of partial blindness. *Nat Med* 1998;4:1083–1087.
25. Pinter MM, Brainin M. Role of repetitive transcranial magnetic stimulation in stroke rehabilitation. *Front Neurol Neurosci* 2013;32:112–121.

Neurology®

rTMS reduces cortical imbalance associated with visual hallucinations after occipital stroke

Sara A. Rafique, John R. Richards and Jennifer K.E. Steeves

Neurology published online September 2, 2016

DOI 10.1212/WNL.0000000000003180

This information is current as of September 2, 2016

Updated Information & Services	including high resolution figures, can be found at: http://www.neurology.org/content/early/2016/09/02/WNL.0000000000003180.full.html
Supplementary Material	Supplementary material can be found at: http://www.neurology.org/content/suppl/2016/09/02/WNL.0000000000003180.DC1.html
Subspecialty Collections	This article, along with others on similar topics, appears in the following collection(s): fMRI http://www.neurology.org/cgi/collection/fmri Hallucinations http://www.neurology.org/cgi/collection/hallucinations TMS http://www.neurology.org/cgi/collection/tms Visual loss http://www.neurology.org/cgi/collection/visual_loss
Permissions & Licensing	Information about reproducing this article in parts (figures, tables) or in its entirety can be found online at: http://www.neurology.org/misc/about.xhtml#permissions
Reprints	Information about ordering reprints can be found online: http://www.neurology.org/misc/addir.xhtml#reprintsus

Neurology® is the official journal of the American Academy of Neurology. Published continuously since 1951, it is now a weekly with 48 issues per year. Copyright © 2016 American Academy of Neurology. All rights reserved. Print ISSN: 0028-3878. Online ISSN: 1526-632X.

