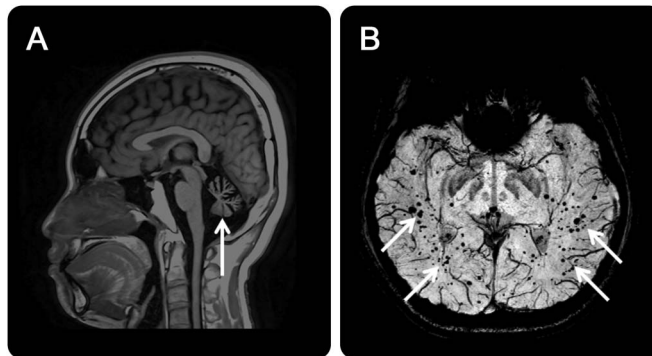


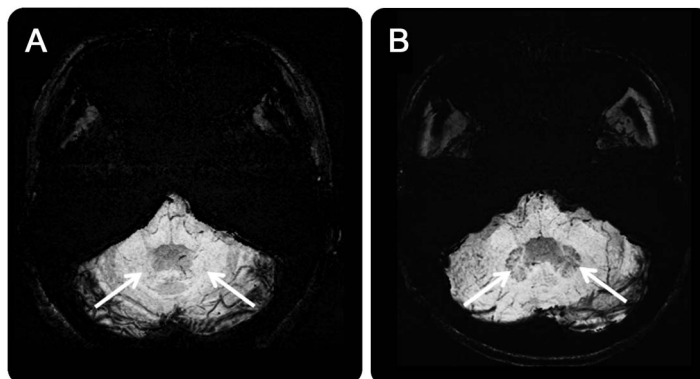
Cerebral microbleeds and iron depletion of dentate nuclei in ataxia-telangiectasia

Figure 1 Cerebellar atrophy and cerebral microbleeds in ataxia-telangiectasia



(A) T1-weighted MRI shows cerebellar atrophy (arrow). (B) Susceptibility-weighted images (SWI) show punctate signal voids scattering throughout the normal-sized cerebrum (arrows), suggesting microbleeds with hemosiderin deposits, which are related to telangiectatic vessels present in the patient with ataxia-telangiectasia.

Figure 2 Iron depletion of dentate nuclei in ataxia-telangiectasia



(A) Susceptibility-weighted images (SWI) reveal an absence of hypointensity of the iron signal in the dentate nuclei of the patient with ataxia-telangiectasia (arrows) compared to an age- and sex-matched normal control participant (B), whereas the dentate nuclei with a typical dark signal related to iron deposits are remarkably visible in SWI (arrows).

A 27-year-old man had been diagnosed with ataxia-telangiectasia at age 13 years. He had ocular telangiectasia and motor ataxia, with incoordination of head and eyes in lateral gaze. Laboratory data revealed deficiency of immunoglobulin and elevated α -fetoprotein. MRI demonstrated cerebellar atrophy and cerebral microbleeds¹ (figure 1); the dentate nuclei had deficient iron signals, which otherwise should be visible as hypointensities in susceptibility-weighted imaging (figure 2). Iron depletion in dentate nuclei is a novel finding and could be explained by the blockage of axonal iron transport in the olivocerebello-olivary loop.²

Hua-Shan Liu, PhD, Yung-Chieh Chen, MD, Cheng-Yu Chen, MD

From the School of Biomedical Engineering, College of Biomedical Engineering, Taipei Medical University (H.-S.L., C.-Y.C.); Department of Medical Imaging, Taipei Medical University Hospital (H.-S.L., C.-Y.C.); Department of Radiology, School of Medicine, College of Medicine, Taipei Medical University (C.-Y.C.); Graduate Institute of Clinical Medicine, College of Medicine, Taipei Medical

University (H.-S.L., C.-Y.C.); Translational Imaging Research Center, College of Medicine, Taipei Medical University (H.-S.L., C.-Y.C.); Department of Biomedical Imaging and Radiological Sciences, National Yang-Ming University (Y.-C.C.), Taipei, Taiwan.

Author contributions: Hua-Shan Liu: study concept and design, drafting manuscript, acquisition and analysis of data, designing figures. Yung-Chieh Chen: clinical data collection and analysis of data. Cheng-Yu Chen: study concept and design, critically reviewing and revising manuscript for intellectual content, study supervision.

Study funding: Hua-Shan Liu was supported by Taipei Medical University (grants TMU103-AE1-B29 and 104TMU-TMUH-03) and Ministry of Science and Technology, ROC (grant MOST105-2218-E-038-003-MY2). Cheng-Yu Chen was supported by Ministry of Science and Technology, ROC (grants MOST104-2314-B-038-051-MY3 and MOST104-2923-B-038-003-MY3) and Health and Welfare Surcharge of Tobacco Products (grant MOHW105-TDU-B-212-134001).

Disclosure: The authors report no disclosures relevant to the manuscript. Go to Neurology.org for full disclosures.

Correspondence to Dr. C.-Y. Chen: sandy0928@seed.net.tw

1. Lin DD, Barker PB, Lederman HM, Crawford TO. Cerebral abnormalities in adults with ataxia-telangiectasia. *AJNR Am J Neuroradiol* 2014;35:119–123.
2. Kim SJ, Lee JH, Suh DC. Cerebellar MR changes in patients with olivary hypertrophic degeneration. *AJNR Am J Neuroradiol* 1994;15:1715–1719.

WriteClick® rapid online correspondence

Have a comment on a recent *Neurology*® article you would like to share? Now it is easier and more convenient. *Neurology.org* has launched WriteClick on the home page and sidebars of each article to encourage remarks and debate among users.

WriteClick is restricted to comments about studies published in *Neurology* within the last eight weeks.

Learn more at Neurology.org/letters

AAN is Committed to Making a Difference: 2017 AAN Research Program

The AAN's ambitious 2017 AAN Research Program offers 20 opportunities, including two new AAN-funded awards: \$450,000 for junior investigators interested in clinical, translational, or basic research; and \$130,000 for basic science research training.

Two additional non disease-specific scholarships are available in clinical and practice-based research; additional targeted funding opportunities include support for research in ALS, Alzheimer disease, ataxia, epilepsy, multiple sclerosis, muscular dystrophy, Parkinson disease, stroke, and Tourette syndrome.

Visit AAN.com/view/ResearchProgram to learn more and apply by the October 1, 2016, deadline!

The AAN is committed to making a profound difference in the lives of researchers by promoting neurology and neuroscience research and training, which in turn will make a difference in the lives of patients with brain disease.

Neurology[®]

Cerebral microbleeds and iron depletion of dentate nuclei in ataxia-telangiectasia

Hua-Shan Liu, Yung-Chieh Chen and Cheng-Yu Chen

Neurology 2016;87;1062-1063

DOI 10.1212/WNL.0000000000003066

This information is current as of September 5, 2016

Updated Information & Services	including high resolution figures, can be found at: http://www.neurology.org/content/87/10/1062.full.html
References	This article cites 2 articles, 2 of which you can access for free at: http://www.neurology.org/content/87/10/1062.full.html##ref-list-1
Subspecialty Collections	This article, along with others on similar topics, appears in the following collection(s): All Education http://www.neurology.org/cgi/collection/all_education MRI http://www.neurology.org/cgi/collection/mri
Permissions & Licensing	Information about reproducing this article in parts (figures, tables) or in its entirety can be found online at: http://www.neurology.org/misc/about.xhtml#permissions
Reprints	Information about ordering reprints can be found online: http://www.neurology.org/misc/addir.xhtml#reprintsus

Neurology® is the official journal of the American Academy of Neurology. Published continuously since 1951, it is now a weekly with 48 issues per year. Copyright © 2016 American Academy of Neurology. All rights reserved. Print ISSN: 0028-3878. Online ISSN: 1526-632X.

