

[⁶⁸Ga]Pentixafor–Positron Emission Tomography/Computed Tomography Detects Chemokine Receptor CXCR4 Expression After Ischemic Stroke

Jan Stefan Schmid, MD; Andreas Schirbel, PhD; Andreas K. Buck, MD; Saskia Kropf, MSc; Hans-Jürgen Wester, PhD; Constantin Lapa, MD

A 64-year-old female with primarily diagnosed small cell lung cancer was referred to our department for positron emission tomography (PET)/computed tomography work-up with [¹⁸F]FDG and [⁶⁸Ga]Pentixafor, a radiotracer for CXC-motif chemokine receptor 4, with the latter being performed on a compassionate use basis in compliance with Section 37 of the Declaration of Helsinki, the German Medicinal Products Act, AMG Section 13 2b, and in accordance with the responsible regulatory body (Regierung von Oberfranken) to check for a potential therapeutic option in this patient. Diagnosis had been established 4 weeks earlier when the patient presented to the emergency room with new-onset aphasia (word retrieval). Cerebral magnetic resonance imaging revealed a contrast-enhancing mass in the left temporal region, which was histopathologically confirmed as small cell lung cancer metastasis.

The day after brain surgery, the patient experienced acute ischemic stroke in the right posterior cerebral artery territory. At the day of presentation to our nuclear medicine department, she reported on recovering hemianopia, and no other neurological symptoms could be recorded.

Concerning the suspected lung carcinoma, both PET modalities visualized a solitary lesion in the upper lobe of the right lung, highly consistent with the suspected primary (Figure 1). In the central nervous system, however, imaging with [¹⁸F]FDG-PET demonstrated markedly reduced glucose metabolism in the infarction area, whereas CXC-motif chemokine receptor 4–directed PET visualized concordantly increased receptor expression (Figure 2).

Recently, proof-of-concept for visualization of CXC-motif chemokine receptor 4 expression by [⁶⁸Ga]Pentixafor, a radiolabeled, highly human-specific receptor ligand for PET imaging, has been demonstrated in patients with small cell lung cancer and

other (hematologic) diseases.¹ Although the feasibility of [⁶⁸Ga]Pentixafor PET imaging has not been studied in experimental models of ischemic stroke yet, the stromal cell–derived factor 1 α /CXC-motif chemokine receptor 4 axis has been shown to play an important role in the recruitment of inflammatory and stem and progenitor cells to the areas of ischemic injury after both myocardial infarction² and ischemic stroke.^{3,4} Its noninvasive, in vivo visualization might lead to novel insights into the course and prognostic implications of postischemic inflammatory response.

Disclosures

Dr Wester is the founder and shareholder of Scintomics. S. Kropf is CEO of Scintomics. The other authors report no conflicts.

References

1. Lapa C, Lücknerath K, Rudelius M, Schmid JS, Schoene A, Schirbel A, Samnick S, Pelzer T, Buck AK, Kropf S, Wester HJ, Herrmann K. [⁶⁸Ga]Pentixafor-PET/CT for imaging of chemokine receptor 4 expression in small cell lung cancer—initial experience. *Oncotarget*. 2016;7:9288–9295. doi: 10.18632/oncotarget.7063.
2. Lapa C, Reiter T, Werner RA, Ertl G, Wester HJ, Buck AK, Bauer WR, Herrmann K. [(68)Ga]Pentixafor-PET/CT for imaging of chemokine receptor 4 expression after myocardial infarction. *JACC Cardiovasc Imaging*. 2015;8:1466–1468. doi: 10.1016/j.jcmg.2015.09.007.
3. Hill WD, Hess DC, Martin-Studdard A, Carothers JJ, Zheng J, Hale D, Maeda M, Fagan SC, Carroll JE, Conway SJ. SDF-1 (CXCL12) is upregulated in the ischemic penumbra following stroke: association with bone marrow cell homing to injury. *J Neuropathol Exp Neurol*. 2004;63:84–96.
4. Schönemeier B, Schulz S, Hoell V, Stumm R. Enhanced expression of the CXCL12/SDF-1 chemokine receptor CXCR7 after cerebral ischemia in the rat brain. *J Neuroimmunol*. 2008;198:39–45. doi: 10.1016/j.jneuroim.2008.04.010.

KEY WORDS: aphasia ■ CXCR4 ■ positron emission tomography ■ small cell lung carcinoma ■ stroke

From the Department of Nuclear Medicine, University Hospital Würzburg, Germany (J.S.S., A.S., A.K.B., C.L.); Scintomics GmbH, Fürstenfeldbruck, Germany (S.K.); and Pharmaceutical Radiochemistry, Technische Universität München, Munich, Germany (H.-J.W.).

Correspondence to Constantin Lapa, MD, Department of Nuclear Medicine, University Hospital Würzburg, Oberdürrbacher Str 6, 97080 Würzburg, Germany. E-mail Lapa_c@ukw.de

(*Circ Cardiovasc Imaging*. 2016;9:e005217. DOI: 10.1161/CIRCIMAGING.116.005217.)

© 2016 American Heart Association, Inc.

Circ Cardiovasc Imaging is available at <http://circimaging.ahajournals.org>

DOI: 10.1161/CIRCIMAGING.116.005217

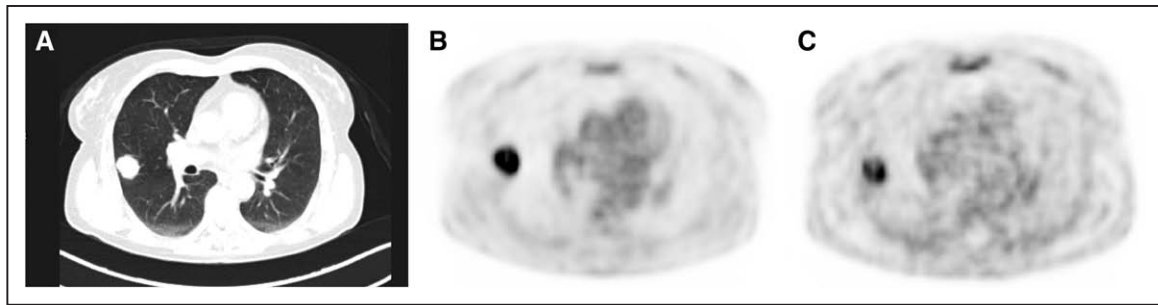


Figure 1. Display of representative axial slices of computed tomography ([CT], **A**) and [^{18}F]FDG- (**B**) and CXCR4 (**C**)-directed positron emission tomography (PET). All modalities present a pulmonary lesion in the right upper lobe, highly consistent with lung cancer. CXCR indicates CXC-motif chemokine receptor.

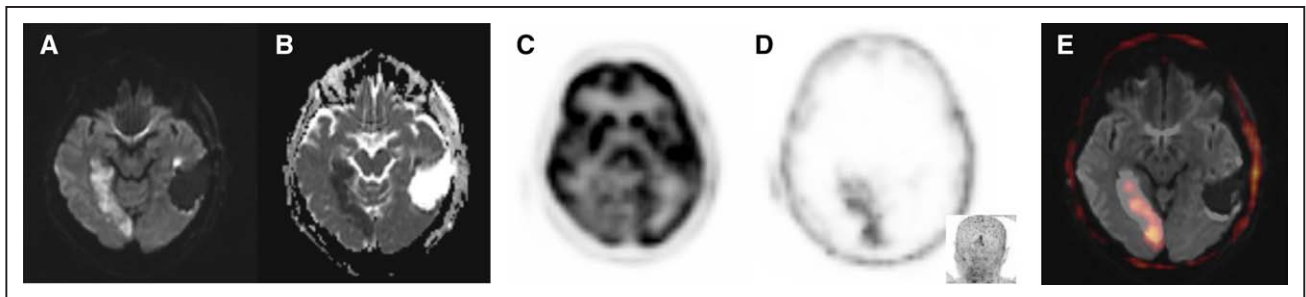


Figure 2. Cerebral magnetic resonance imaging (cMRI) at day 2 after brain surgery shows demarcation of right posterior ischemia with corresponding changes in diffusion-weighted images (**A**; b value = 1000 s/mm^2) and apparent diffusion coefficient values (**B**). [^{18}F]FDG-PET demonstrates significantly reduced tracer uptake in the infarction area (**C**). In contrast, [^{68}Ga]Pentixafor-PET (one day later) visualizes upregulation of CXCR4 (**D**, Inset; maximum intensity projection; standardized uptake value $_{\text{max}}$ = 4.08 versus standardized uptake value $_{\text{mediastinal bloodpool}}$ = 1.62), which correlates with cMRI changes (**E**, DWI/PET fusion). CXCR indicates CXC-motif chemokine receptor; DWI, diffusion-weighted image; and PET, positron emission tomography.