

Cranial Computerized Tomography in Children with Lymphoid Malignancy and Seizures

H. U. Schwenk¹, G. Neuhäuser¹, and W. Huk²

¹University Children's Hospital, Erlangen-Nürnberg (Director: Prof. Dr. K. Stehr), Loschgestr. 15, D-8520 Erlangen

²Department of Neurological Surgery, University Erlangen-Nürnberg (Director: Prof. Dr. W. Schiefer), D-8520 Erlangen, Federal Republic of Germany

Abstract. Focal and generalized seizures occurred in 4 patients with acute lymphoblastic leukemia and non-Hodgkin-lymphoma. The etiology of the neurological complications could be established by cranial computerized tomography (CT): i.e., 1. localized metastasis with calcification and 2. acute intracerebral hemorrhage during induction therapy in two patients with malignant lymphomas; 3. diffuse cerebral infiltration with blast cells and 4. cerebral atrophy in two children with acute lymphoblastic leukemia who were in relapse.

Accurate diagnosis of cerebral complications in hemoblastoses is essential for appropriate therapy and CT may lead to more effective treatment in patients with lymphoid malignancy and seizures.

Key words: Lymphoid malignancy - Seizures - Cranial computerized tomography.

Introduction

The increasing survival of children with leukemia and related diseases is accompanied by a higher frequency of neurological complications [8]. Seizures may be induced in these patients by different causes: i.e., side effects of anti-neoplastic drugs; infiltration of the CNS by blast cells; encephalitis due to various agents; intracranial bleeding or chronic subdural hematoma [1, 7, 10, 11].

Whatever the cause, specific therapeutic measures according to the etiology are necessary in each patient, in addition to symptomatic anticonvulsant treatment. An accurate diagnosis is therefore required and this is usually based on historical data, a detailed neurological examination, fundoscopy, lumbar puncture with cytocentrifuge preparation of CSF-cells, electroencephalogram, echoencephalogram or brain scan. After more than two years experience, we believe that cranial computerized tomography (CT) represents another reliable, non-invasive method for evaluating patients with neurological disorders caused by

haemoblastoses. Compared to other non-invasive methods, CT has the advantage that it can localize and determine the extent of a cerebral lesion precisely. In some cases this is essential for effective therapy.

Method

The CT examinations were done with a prototype of the Siemens head scanner (Siretom), which has a matrix of 80×80 picture points and a slice thickness of 10 millimeters, the volume element measuring $3 \times 3 \times 10$ millimeters. To reveal small areas of pathological density, overlapping horizontal sections parallel to the 25° standard plane were performed. When areas of abnormal density were found, identical cuts were repeated after contrast enhancement with 1 ml/kg Urografin 60%.

Case Reports

Patient 1. M. F. was a $9\frac{7}{12}$ year old girl, who presented with a mass in the left side of the neck above the clavicle. There was no evidence of other enlarged lymph nodes. Her liver and spleen were normal. No blasts could be detected in peripheral blood (Hb 13.6 mg/dt, RBC $4.10 \times 10^6/\text{mm}^3$, WBC $6000/\text{mm}^3$ and thrombocytes $160\,000/\text{mm}^3$) and bone marrow. The cerebrospinal fluid contained 3 cells/ mm^3 ; their morphology was not documented.

Radiology of the chest showed symmetrical enlargement of the upper mediastinum. Histological examination of the cervical mass revealed a T-lymphoblastic malignant non-Hodgkin-lymphoma (convoluted type). Because of the frequent leukemic transformation of this type of lymphoid malignancy—as demonstrated during the course of the disease—cytostatic therapy was initiated during irradiation of the tumour, using $6 \times 2.0 \text{ mg}/\text{m}^2$ vincristine, $2 \times 20 \text{ mg}/\text{m}^2$ adriamycin, and $60 \text{ mg}/\text{m}^2$ prednisolone. After induction therapy over six weeks, additional prophylactic irradiation of the CNS and $50 \text{ mg}/\text{m}^2$ mercaptopurine was started. During this irradiation (2200 rads) $5 \times 12 \text{ mg}/\text{m}^2$ methotrexate was administered intrathecally.

During maintenance therapy with mercaptopurine, cyclophosphamide and methotrexate, bone marrow punctures were done at intervals of 3–4 months and at the same time cerebrospinal fluid was examined for blasts. Eight months after diagnosis, incipient generalisation of the disease was suspected from bone marrow studies, since 3% temperature-resistant E₃₇-rosettes could be detected [12]. Eleven months after diagnosis, the girl suddenly complained of dizziness, double vision, and stomach ache. She was immediately admitted to the hospital when a possible seizure was observed. During the following physical examination, she developed a tonic-clonic attack, spreading from the right forearm and involving the entire body. The seizure was controlled by diazepam (8 mg i.v.). Over the next few days, several brief, focal seizures affecting the right arm and face were observed, despite treatment with hydantoin. No blasts were detectable in the cerebrospinal fluid by cytocentrifuge preparation, and there was no increase in the lumbar pressure. The electroencephalogram showed some focal slowing over the left hemisphere and the echoencephalogram was normal. However, slight displacement to the right of the midline structures was detected by CT which also showed compression of the left lateral ventricle and an area of low density in the left parietal white matter (Fig. 1a).

In addition to anticonvulsant treatment, chemotherapy with L-asparaginase, vincristine and prednisolone was commenced. At the same time, the solid metastasis shown by CT was given further irradiation (4400 R over an area of $6 \times 6 \text{ cm}$). Seven weeks after the initial examination, a second scan confirmed the effectiveness of these measures. There was no displacement of midline structures, and the area of low density was hardly seen (Fig. 1b). Since then, no seizures have occurred with continuing anticonvulsant therapy and the neurological findings are normal. Another CT scan 7 months after the initial observation showed a small area of calcification around the presumed metastasis which had not increased in size (Fig. 1c).

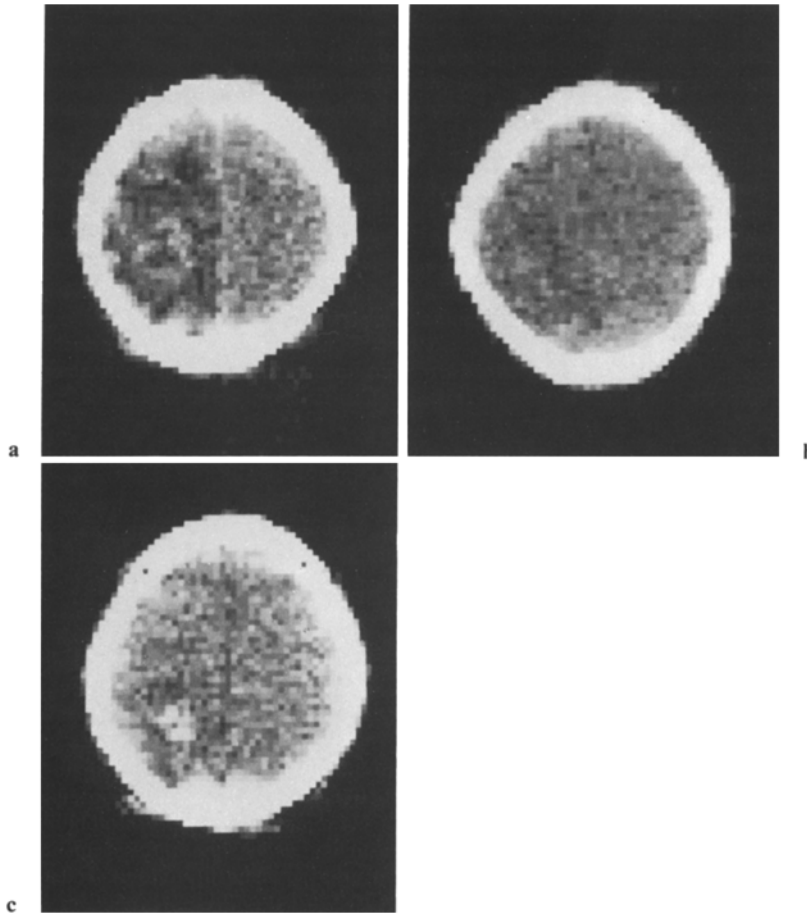


Fig. 1. a Patient F.M., CT-No. 1965. Irregular, ring-shaped mass in the supraventricular sections of the left parietal white matter after contrast enhancement. Clearly diminished density extending over the entire left hemisphere at this level indicating wide-spread secondary edema. Shift of the medial brain structures to the right. b Patient F.M., CT-No. 2342. Control scan after 6 weeks of therapy: Only a poorly defined, comparatively small area of slightly diminished density in place of the previous tumor. The midline shift has returned to normal. c Patient F. M., CT-No. 1060. Control CT about 8 months later: Irregular, comparatively dense (+95 Hounsfield units) structure measuring about $2.5 \times 2.5 \times 2.5$ cm in the left parietal, supraventricular white matter in the place of the previous ring-shaped tumor. Small, poorly defined surrounding area of edema. The shape of the structure strongly suggests a calcifying process

Patient 2. E. U., a $15\frac{3}{12}$ year old girl admitted to hospital with the diagnosis of delayed puberty. However, she was jaundiced, extremely emaciated, and had bean-sized lymph nodes in the inguinal and cervical region. A large tumour could be felt in the middle of the abdomen, close to the liver. The differential blood count and bone marrow cytology were normal. The bilirubin was 8.5 mg%, lactate dehydrogenase 970 U/L, and alkaline phosphatase 1089 U/L with other biochemical signs of liver damage and reduced liver-dependent clotting factors.

Histological examination of a cervical lymph node revealed an immunoblastic non-Hodgkin-lymphoma (Stage III). Since the abdominal tumour was already interfering with

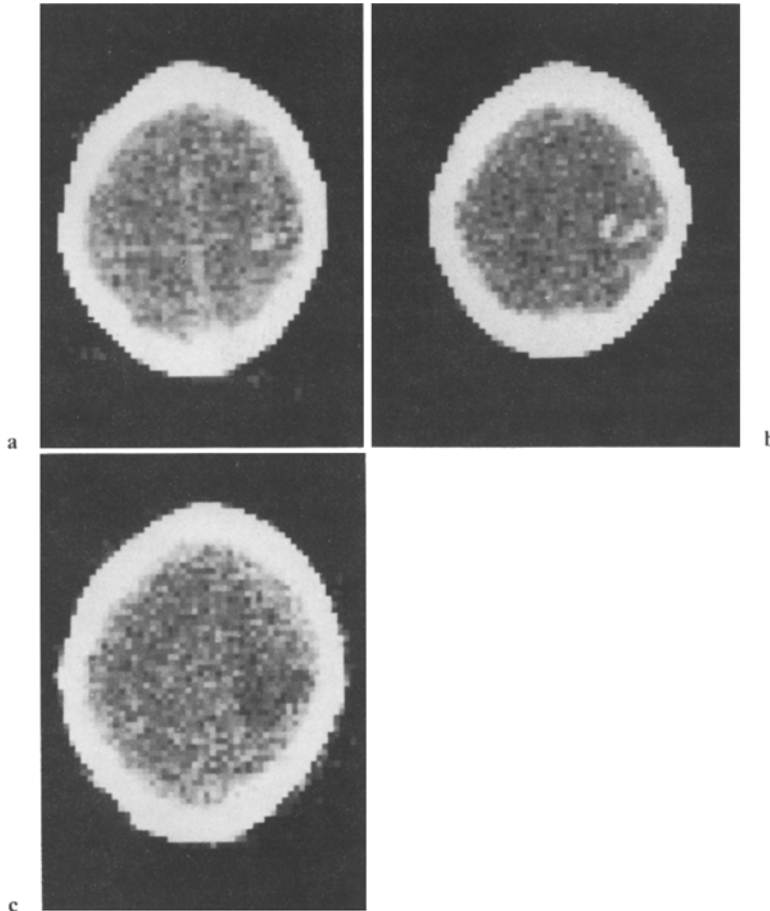


Fig. 2. **a** Patient E. U., CT-No. 622. Normal ventricular system. In the right supraventricular parietal white matter small (1.5×2 cm) dense area (+80 Hounsfield units) without surrounding edema. The lesion is very suggestive of a small hemorrhage. **b** Patient E. U., CT-No. 659. Control scan three days later: The structure in the right parietal white matter has enlarged and changed into a horseshoe-shaped lesion with a marrow margin. Density again +80 Hounsfield units. **c** Patient E. U., CT-No. 729. Control scan 10 days after the initial examination: Poorly defined area of low density occupying the right parietal white matter and compressing the trigone and posterior horn of the right lateral ventricle. The small hematoma has changed its density and induced a moderate swelling of the surrounding brain tissue

intestinal transit and the girl was vomiting frequently, cytostatic treatment in accordance with LSA₂L₂ protocol of the Sloan Kettering Cancer Center was commenced as quickly as possible [16]. On the 9th day of treatment—4 days after intrathecal injection of 6.25 mg/m^2 methotrexate and 6 days after administration of 1.5 mg/m^2 vincristine—left sided seizures occurred and were followed by a flaccid left hemiplegia with central paresis of the facial nerve.

Using CT, there was evidence of a 1.5×2 cm area of increased density in the right parietal supraventricular area (Fig. 2a). Follow-up CT studies within the next 10 days demonstrated that the findings were probably caused by slight hemorrhage (Figs. 2b and c). Seizures recurred 3 days later, despite anticonvulsant therapy. Cytostatic treatment was discontinued and the

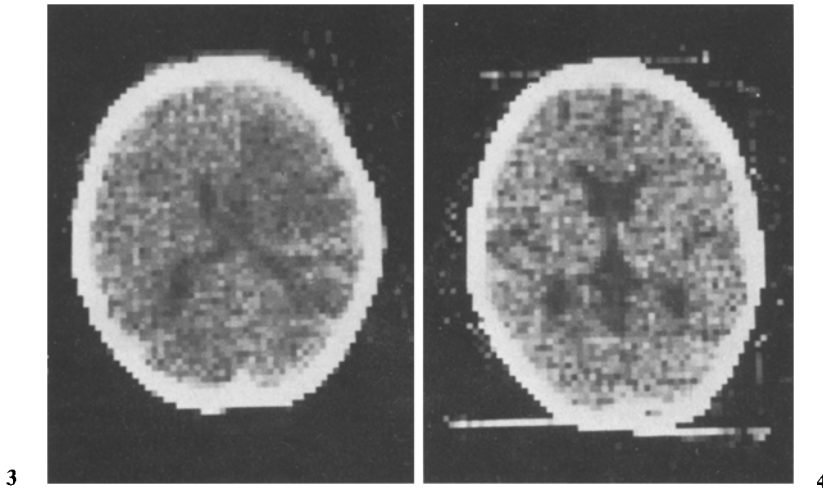


Fig. 3. Patient E. U., CT-No. 296. Large, poorly defined area of low density covering the white matter of almost the entire right hemisphere, including the putamen and extending from the Sylvian fissure to the apex. Compression of the right lateral ventricle; small midline shift to the left

Fig. 4. Patient O. T., CT-No. 1052. Slightly enlarged ventricular system; dilatation of Sylvian fissures and of the callosal cistern, suggestive of cerebral atrophy

hemiplegia quickly resolved after physiotherapy. Since hemorrhage was supposedly the cause of the fits, injections of vincristine and methotrexate were continued after correction of deficient clotting factors. No further seizures were observed although the anticonvulsant treatment was terminated after 4 weeks. Eight weeks later the abdominal tumor recurred, despite previous abdominal radiation. During maintenance chemotherapy with cyclical oral thioguanine 300 mg/m² for 4 consecutive days, the patient lost vision within two days. No blasts were demonstrable in the spinal fluid. The girl died from heart failure caused by a left sided pleural effusion secondary to trans-diaphragmatic spread of the tumour. Postmortem findings (brain): Both optic nerves were enlarged from lymphoblastic infiltrations. There was a slit like cavity 3 cm long within the right cerebral white matter as a result of an old hemorrhage. Histological examination showed cyst formation and glial-mesenchymal organization in this area, but also showed sequelae of circulatory disturbance in the corresponding cortical regions where lymphoblastic infiltration of the arachnoid was found.

Patient 3. E. U., a 9 $\frac{1}{2}$ year old boy, presented with acute lymphoblastic leukemia. He had been in complete remission for 2 $\frac{1}{2}$ years and combination chemotherapy was therefore discontinued. However, 3 months later a relapse in bone marrow, testis and cerebrospinal fluid was diagnosed. Following elimination of the meningeal involvement by high-dose induction therapy, a second course of CNS radiation was performed in an attempt to induce a second long remission. However, 9 months later meningeal involvement recurred. This again responded to steroids, L-asparaginase, intrathecal cytosine-arabioside and methotrexate therapy and blasts could no longer be detected any more in the cerebrospinal fluid. About 6 months later, the boy complained of deteriorating vision and weakness of the left arm. Soon he could not elevate his arm, he became very clumsy with his left hand and was unable to stretch the fingers. At his next admission, there was a facial paralysis and spasticity of the left arm with paresis of arm and shoulder elevation. The deep tendon reflexes were exaggerated, compared to the right. His gait was unsteady, the left arm showing uncoordinated associated movements. Speech was impaired

and mental reactions markedly slow. The blood count showed thrombocytopenia and the cerebrospinal fluid was again free of blast cells. The EEG revealed generalised slowing. Papilledema was not present. CT showed that the midline structures were displaced to the left (Fig. 3). An area of lower density was seen between trigonum and anterior horn. This extended to the ventricular roof and was interpreted as being due to diffuse infiltration of brain tissue with blast cells. Following rapid mental deterioration and generalized seizure, therapy was stopped and the patient died after a 3-week period of unconsciousness. Even after death, there was no indication of blasts in the cerebrospinal fluid. An autopsy was not permitted.

Patient 4. O. T., a boy who was 5 years old when ALL was diagnosed. Although still on therapy two years later, meningeal relapse occurred with 300 blasts/mm³ in the cerebrospinal fluid. Despite vigorous systemic and intrathecal chemotherapy, the meningeal disease recurred. Four weeks after an intrathecal cytosine-arabioside injection, he suddenly had a seizure at home, which lasted for more than 6 minutes. Generalized brain atrophy was diagnosed by CT on the same day (Fig. 4). The patient had received a cumulative intrathecal dose of 174 mg methotrexate and 65 mg cytosine-arabioside.

Discussion

The neurotoxic effects of anti-neoplastic agents, such as vinca alkaloids, L-asparaginase, procarbazine, nitrogen mustard and methotrexate etc., are frequently thought to be responsible for seizures in children with leukemia [15]. Moreover, if these substances are administered intrathecally, their ionic content, osmolarity, unphysiological pH or the preservatives may be responsible for neurotoxicity. Although reliable determination of methotrexate in cerebrospinal fluid is possible [2] and neurotoxicity is supposedly correlated to concentration [13], the pathogenetic effects of intrathecal methotrexate remain unclear. There are no clinical, biochemical or histological methods available which permit an unambiguous diagnosis of cerebral damage induced by methotrexate. The frequency of methotrexate neurotoxicity is unusually variable, and has been reported in 4% to over 60% of cases by different authors [3, 9]. This discrepancy may be caused by different neurological documentation. On the other hand, neurological disturbances may be falsely ascribed to methotrexate therapy. CT examination is of little help in proving the neurotoxic effects of anti-neoplastic agents. However, it may show other causes of seizures which occur during intrathecal methotrexate or vincristine therapy. Thus, it should be performed even if the side effects of therapy are suspected to be the cause of seizures. During the initial phase of treatment in patient 2 who had a coagulation disorder, slight intracerebral bleeding was demonstrable by CT. This occurred 6 days after methotrexate and vincristine was administered. Since a definite diagnosis of hemorrhage was possible, intrathecal methotrexate therapy and weekly vincristine could be continued without further complications, as soon as improvement of neurological signs was observed. Therefore, effective medication was possible and interruption of therapy and treatment with folic acid were avoided.

While the frequency of intracerebral bleeding is probably decreasing as a result of to improved chemotherapy in acute leukemia, there is evidence that chronic subdural hematomas are being diagnosed more frequently. Pitner and Johnson [11] found subdural hematomas in 13 out of 126 autopsies on children

with acute lymphocytic leukemia. Five of these thirteen patients had focal or generalized seizures. Diagnosis by echoencephalogram or electroencephalogram is only possible in cases with large hematomas. Cerebral angiography is often dangerous, especially in patients with hemorrhagic disorders. Therefore, in children with leukemia, chronic subdural hematomas will be diagnosed more frequently by routine CT examinations as we have already observed in non-malignant subdural effusion in infants [5].

Routine CT could also establish an early and objective diagnosis of cerebral atrophy induced by anti-leukemic treatment and radiotherapy (Fig. 4). Follow-up studies, using cranial CT annually in all patients with a high risk of cerebral involvement, would be necessary to get more information about these sequels of therapy.

In patient 1, CT showed an isolated area of low density in the left parietal white matter fourteen months after diagnosis of a mediastinal T-cell lymphoma and following several predominantly right sided seizures. Since this type of lymphoma often causes metastatic tumours (abdomen, CNS), a solid metastasis was suspected. Because it could be localized precisely, repeat CNS irradiation was given over a small area even though prophylactic CNS irradiation had been discontinued only 12 months before. The success of this therapy was obvious from the following CT examinations and no further seizures occurred.

In the same patient, blast cells were never demonstrated by cytocentrifuge preparation. This is not surprising since the metastasis was located deep in the cerebral white matter, without contact with the cerebral or ventricular surfaces. Again, in patient 3 no definite blasts could be detected in the CSF, although diffuse infiltration of the right hemisphere had penetrated to the ventricular wall. The value of the highly-recommended and widely-used spinal fluid cell concentration method [6] should not be over-estimated with regard to its use in excluding CNS infiltration. In our experience, morphological examination of the cytocentrifuge preparation is not effective if the cell count is less than one cell per mm^3 , which may yet indicate up to 1000 blasts per ml cerebrospinal fluid.

CT examination can also demonstrate cerebral changes in encephalitis [14]. This may occur in children with leukemia during the course of immunosuppressive therapy [1]. Therefore, CT may be important in planning the treatment of children with seizures: If neurotoxic effects are the cause, withdrawal of the drug is necessary, together with administration of folic acid. Infiltration with blasts requires intrathecal and systematic cytostatic drugs followed by further irradiation. In encephalitis, adenosine-arabinoside and improvement of the body's natural immunity is indicated, in addition to relief of increased intracranial pressure. Surgery may be necessary in subdural hematomas. Because there are many different therapeutic possibilities, reliable diagnosis is of great importance. For example, radiation for a presumed metastasis in a patient with encephalitis may be fatal.

Improvement in the resolution of CT in the future will probably permit analysis of the fine tissue structures in the brain. Even extensive fibrillary gliosis [4], a probable consequence of antileukemic treatment which is frequently seen, will be diagnosed by CT. The CT examination will therefore help to ensure that children with lymphoid malignancy, who have overcome their serious disease as a

result of highly effective chemotherapy, are not left with permanent neurological abnormalities.

Acknowledgement. The examination of the brain in patient 2 was done by Prof. Dr. H. Schmidt. We appreciate his permission to publish the findings.

References

1. Aicardi, J., Goutieres, F., Arsenio-Nunes, M. L., Lebon, R.: Acute measles encephalitis in children with immunosuppression. *Pediatrics* **59**, 232—239 (1977)
2. Bleyer, W. A., Drake, J. C., Chabner, B. C.: Neurotoxicity and elevated cerebrospinal fluid methotrexate concentration in meningeal leukemia. *N. Engl. J. Med.* **289**, 770—773 (1973)
3. Gagliano, R. G., Costanzi, J. J.: Paraplegia following intrathecal methotrexate. *Cancer* **37**, 1663—1668 (1976)
4. Hendin, B., Devivo, D. C., Torack, R., Lell, M.-E., Ragab, A. H., Vietti, T. J.: Parenchymatous degeneration of the central nervous system in childhood leukemia. *Cancer* **33**, 486—492 (1974)
5. Huk, W.: Unpublished
6. Komp, D. M.: Cytocentrifugation in the management of central nervous system leukemia. *J. Pediat.* **81**, 992—993 (1972)
7. Law, J. P., Dick, F. R., Blom, J., Bergevin, P. R.: Involvement of the central nervous system in Non-Hodgkin's lymphoma. *Cancer* **36**, 225—231 (1975)
8. McIntosh, S., Klatskin, E., O'Brien, R., Aspnes, G., Kammerer, B., Snead, C., Kalavsky, S., Pearson, M.: Chronic neurologic disturbance in childhood leukemia. *Cancer* **37**, 853—857 (1976)
9. Meadows, A. T., Evans, A. E.: Effects of chemotherapy on the central nervous system. *Cancer* **37**, 1079—1085 (1976)
10. Phair, J. P., Anderson, R. E., Namiki, H.: The central nervous system in leukemia. *Annales Int. Med.* **61**, 863—875 (1964)
11. Pitner, S. E., Johnson, W. W.: Chronic subdural hematoma in childhood acute leukemia. *Cancer* **32**, 185—190 (1973)
12. Schwenk, H. U., Willital, G.: Früherkennung der leukämischen Transformation maligner Nicht-Hodgkin-Lymphome im Kindesalter. *Dtsch. med. Wschr.* **101**, 450—454 (1976)
13. Tatersall, M. H. N., Pitman, S. W., Parker, L. M.: Clinical pharmacology of high dose methotrexate (HDMTX) with citrovorin (CF) rescue. *Proc. Am. Assoc. Cancer Res.* **16**, 161 (1975)
14. Thomson, J. L. G.: The computed axial tomograph in acute herpes simplex encephalitis. *Br. J. Radiol.* **49**, 86—93 (1976)
15. Weiss, H. D., Walker, M. P., Wiernik, P. H.: Neurotoxicity of commonly used antineoplastic agents. *N. Engl. J. Med.* **291**, 75—81 (1974)
16. Wollner, N., Burchenal, J. H., Liebermann, P. H., Exelby, P., D'Angio, G., Murphy, M. L.: Non-Hodgkin's lymphoma in children. *Cancer* **37**, 123—134 (1976)

Received August 23, 1977