



Clinical Reasoning: A 73-year-old man with sarcoidosis and multifocal ischemic strokes

Michael Pichler, MD
James Klaas, MD
Zelalem Temesgen, MD
Orhun Kantarci, MD

Correspondence to
Dr. Pichler:
Pichler.Michael@mayo.edu

SECTION 1: CLINICAL PRESENTATION

A 73-year-old man was admitted for evaluation of acute ischemic strokes. His medical history was notable for pulmonary sarcoidosis treated with oral prednisone 40 mg daily, type 2 diabetes mellitus, hypertension, and hyperlipidemia. Approximately 1 month prior to admission, he underwent elective right total knee arthroplasty at an outside institution and 1 week postoperatively developed acute delirium and fluctuating fevers. No infectious cause was identified. His mental status continued to decline and head MRI was obtained (figure, A), showing small acute infarcts in multiple vascular territories.

He began having episodes of forced eye deviation and behavioral arrest lasting less than 30 seconds each. He was urgently admitted to our hospital and

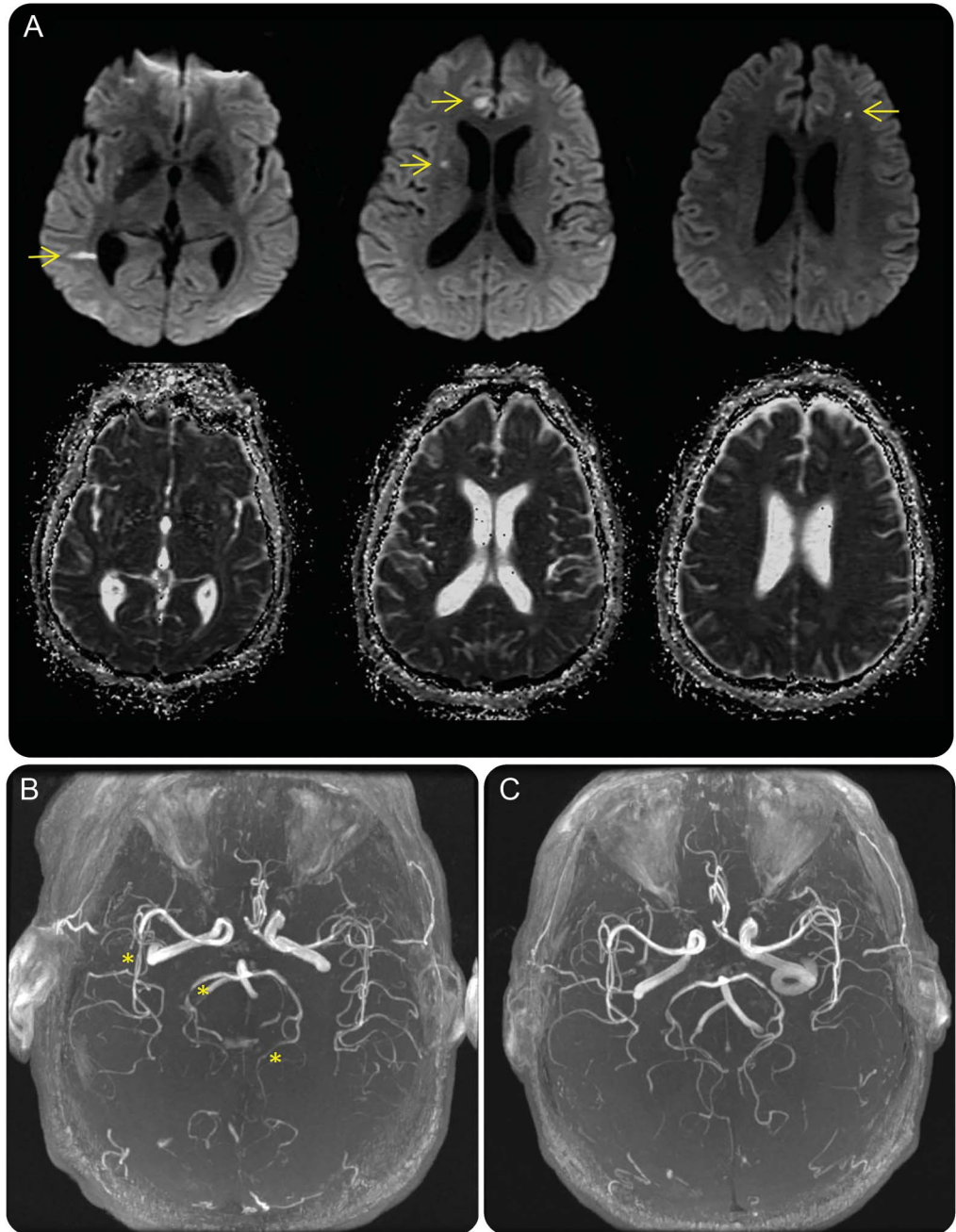
levetiracetam was started empirically, without recurrence of presumed seizures. He complained only of mild headache and right knee pain. On examination, he was hemodynamically stable and afebrile. He was encephalopathic and had mild right leg weakness, but the rest of the neurologic examination was nonfocal. There was no meningismus. EEG showed mild diffuse slowing but no epileptogenic activity. Complete blood counts, electrolytes, lactate, and sedimentation rate were within normal limits. Chest CT showed stable findings consistent with his diagnosis of pulmonary sarcoidosis, but no acute pathology or evidence of active infection.

Questions for consideration:

1. What are the potential causes of the infarcts?
2. What additional workup is necessary?

[GO TO SECTION 2](#)

Figure Axial head MRI shows multifocal acute infarcts and magnetic resonance angiogram (MRA) shows cerebral vasculature changes before and after treatment with antifungal therapy



(A) Axial diffusion-weighted (top row) head MRI shows restricted diffusion in multiple vascular territories (arrows), including the distribution of bilateral anterior cerebral arteries, right middle cerebral artery, and right posterior cerebral artery. The areas of restricted diffusion show corresponding hypointensity on apparent diffusion coefficient imaging (bottom row), consistent with acute ischemic infarcts. (B) Head MRA shows luminal irregularity of the bilateral posterior cerebral arteries and branches of the right middle cerebral artery (asterisks), consistent with vasculitis. (C) Repeat head MRA after 10 days of antifungal treatment shows interval resolution of the previously visualized irregularities of the intracranial vessels.

SECTION 2: DIFFERENTIAL DIAGNOSIS

Acute strokes involving multiple vascular territories can result from numerous etiologies, but are most suggestive of a proximal source of emboli or a diffuse vasculitic process. This distribution of infarcts would not be seen with single artery-to-artery emboli, large vessel stenosis, or chronic small vessel disease. Cardioembolic sources must be ruled out in such cases. Paroxysmal atrial fibrillation could be a contributing factor for emboli, and the presence of a patent foramen ovale could be relevant in a postoperative knee patient at risk for deep vein thrombosis. The presence of fever and encephalopathy is very atypical for most ischemic strokes. Infectious sources such as meningitis must be considered, even in the absence of meningismus. In the setting of immunosuppression, infective endocarditis producing septic emboli is also a possibility. Vasculitis could present with multiple areas of infarct, and the patient was predisposed to autoimmune disease given the history of sarcoidosis. Venous infarcts due to cerebral venous sinus thrombosis

warrant consideration, especially in a patient with headache and new-onset seizures.

Repeat head MRI on admission showed multiple new small areas of acute infarction, again in multiple vascular territories. Transesophageal echocardiogram was obtained to evaluate for cardioembolic cause of strokes. There was no intracardiac thrombus, valvular vegetations, or right-to-left shunt. Head and neck magnetic resonance angiography (MRA) showed multifocal, asymmetric stenoses involving the bilateral posterior cerebral arteries and branches of the right middle cerebral artery, consistent with vasculitis (figure, B). There was no evidence of venous sinus thrombosis.

Questions for consideration:

1. What is the differential diagnosis of this patient's vasculitis?
2. What further tests are indicated to narrow this differential diagnosis?

[GO TO SECTION 3](#)

SECTION 3: INVESTIGATIONS

The multifocal infarcts were believed to be due to vasculitis, which is a generic term referring to blood vessel inflammation. The appropriate treatment depends on the underlying cause of vasculitis. CNS vasculitis frequently occurs in the setting of a systemic inflammatory process or connective tissue disease (polyarteritis nodosa, Behçet disease, systemic lupus erythematosus) but may also be due to various infectious causes, medications, or illicit drug use.

In our patient, serum inflammatory markers were not elevated to suggest a systemic inflammatory process and there was no evidence of other end-organ damage. He was not on any medications known to be associated with vasculitis, and there was no history of illicit drug use. There were no signs of systemic infection and no recent travel history.

The possibility of cerebral involvement of sarcoidosis was entertained. Vascular involvement has been demonstrated in numerous neuropathologic studies of sarcoidosis.¹⁻³ Granulomatous invasion of the vessel walls has been shown to cause vasculitic disruption of the media and internal elastic lamina, leading to infarct in many cases. The granulomatous vasculitis preferentially involves small penetrating arteries, though involvement of larger vessels has also been reported.³ The treatment for vasculitis differs drastically depending on the underlying cause. Sarcoidosis

and other inflammatory conditions are treated with immunosuppression, but this could have potentially devastating consequences in the setting of infectious vasculitis.

To further evaluate the cause of vasculitis in our patient, a lumbar puncture was performed and showed elevated protein of 194 mg/dL, 75 leukocytes/ μ L (50% neutrophils, 17% lymphocytes, and 33% monocytes/macrophages), and glucose less than 20 mg/dL. CSF Gram stain was negative. PCR testing was negative for herpes simplex, varicella zoster, and Epstein-Barr viruses. Fungal smear, which uses calcofluor white to stain chitin in cell wall of fungi, returned positive. Cryptococcal antigen testing using a lateral flow assay was also positive. Blood and CSF cultures ultimately grew *Cryptococcus neoformans var neoformans*.

The patient was started immediately on induction therapy with amphotericin and flucytosine for treatment of cryptococcal meningitis (CM). Head MRA repeated 10 days after starting antifungal therapy showed resolution of the previously visualized vascular irregularity (figure, C). Mental status returned to prior baseline and he was discharged to a rehabilitation facility because of persistent right leg weakness. Fluconazole was started for ongoing treatment of CM.

Question for consideration:

1. What is the unifying diagnosis?

GO TO SECTION 4

SECTION 4: DISCUSSION

It was believed that steroid-related immunosuppression as treatment for pulmonary sarcoidosis made this patient susceptible to CM. The meningitis then caused diffuse vasculitis and presented with multifocal ischemic strokes, encephalopathy, and seizures.

Cryptococcus neoformans is the most common systemic fungal infection in immunocompromised patients. These patients often present with insidious onset of nonspecific symptoms and sometimes with isolated neurologic complaints. The majority of patients develop fever, headache, and altered mental status over several weeks, though typical meningismus is reported in fewer than 25% of patients. Seizures have been reported in up to 10% of cases.⁴ Because of the nonspecific symptoms and insidious onset, diagnosis may be delayed.⁵

Cerebral ischemia is a relatively rare but well-described complication seen in CM and several mechanisms may be involved. It has been proposed that meningitis can lead to irritation of traversing subarachnoid blood vessels, which in turn causes vasospasm and ischemia.⁶ This theory is supported by the fact that our patient had evidence of vasospasm in multiple infarcted areas, which resolved with treatment of the underlying meningitis. Inflammation may also lead to endarteritis and small vessel ischemic stroke. Exudates in the setting of chronic meningitis are typically found in the basal cisterns, which may explain why the majority of infarcts in patients with CM are observed in the basal ganglia, internal capsule, or thalamus.⁷ Although hydrocephalus is a common complication of CM and may contribute to cerebral ischemia by stretching vessels or increasing intracranial pressure,⁷ this did not seem to be a major factor in the pathology of our patient.

Infectious causes of stroke are important to consider in all patients, especially those who are immunosuppressed. Identifying the underlying cause is essential to help dictate the appropriate therapy. If diagnosis is made early enough, excellent patient outcomes are possible.

AUTHOR CONTRIBUTIONS

Dr. Pichler was involved in drafting and revising the manuscript for content. Dr. Klaas was involved in drafting and revising the manuscript for content. Dr. Temesgen was involved in drafting and revising the manuscript for content. Dr. Kantarci was involved in drafting and revising the manuscript for content.

STUDY FUNDING

No targeted funding reported.

DISCLOSURE

The authors report no disclosures relevant to the manuscript. Go to Neurology.org for full disclosures.

REFERENCES

1. Brown MM, Thompson AJ, Wedzicha JA, Swash M. Sarcoidosis presenting with stroke. *Stroke* 1989;20:400–405.
2. Degardin A, Devos P, Vermersch P, de Seze J. Cerebrovascular symptomatic involvement in sarcoidosis. *Acta Neurol Belg* 2010;110:349–352.
3. Reske-Nielsen E, Harmsen A. Periangiitis and panangiitis as a manifestation of sarcoidosis of the brain: report of a case. *J Nerv Ment Dis* 1962;135:399–412.
4. Zunt JR, Baldwin KJ. Chronic and subacute meningitis. *Continuum* 2012;18:1290–1318.
5. Rosario M, Song SX, McCullough LD. An unusual case of stroke. *Neurologist* 2012;18:229–232.
6. Tjia TL, Yeow YK, Tan CB. Cryptococcal meningitis. *J Neurol Neurosurg Psychiatry* 1985;48:853–858.
7. Lan SH, Chang WN, Lu CH, Lui CC, Chang HW. Cerebral infarction in chronic meningitis: a comparison of tuberculous meningitis and cryptococcal meningitis. *QJM* 2001;94:247–253.