

# Carotid Artery Dissection With Associated Territory Stroke After a Minor Head Trauma in a Healthy 4-Month-Old Child

Robert Zant, MD,\* Michael Melter, MD, PhD,\* Christian Doerfler, MD,\* Felix Schlachetzki, MD, PhD,† Ernst-Michael Jung, MD, PhD,‡ Stefan Schilling, MD,\* and Juergen Kunkel, MD\*

**Abstract:** Internal carotid artery (ICA) dissections with associated stroke are rare events in infants. The usual pathomechanisms include direct trauma to the artery, blunt intraoral trauma, or child abuse. We describe the case of a 4-month-old male patient with ICA dissection and associated middle cerebral artery territory infarction associated with hyperextension/hyperrotation after a minor head injury. Upon treatment with anticoagulants, the patient showed significant improvement of the left-sided hemiparesis. Hemorrhagic transformation that presented shortly after middle cerebral artery infarction did not further increase under heparin treatment and prevented further embolism. In conclusion, hyperextension and/or hyperrotation in minor head trauma is a possible pathomechanism for ICA dissection in infants. However, the scenario is extremely rare, and to our best knowledge, this is the first report describing it. In our patient, anticoagulation did not worsen hemorrhagic transformation.

**Key Words:** infant, minor head trauma, internal carotid artery dissection, stroke

(*Pediatr Emer Care* 2017;33: e177–e179)

A previously healthy and age-appropriately developed 4-month-old male patient presented to our emergency department. He suffered minor head trauma after his grandmother fell down a stairway while carrying the patient. There was no loss of consciousness, signs of raised intracerebral pressure, or focal neurological deficits at any time. Clinical examination revealed bruising to the right parieto-occipital and retroauricular region of the head but no evidence of neck trauma. At this time, a bedside-performed cranial ultrasound did not show any signs of an intracranial bleed. Because of his young age and the severity of the fall, the patient was admitted to our hospital for further neurological observation. On day 3 postadmission, an increasing subgaleal hematoma was noticed prompting a cranial ultrasound. Although the neurological status was still unremarkable, the scan revealed a nondisplaced skull fracture and suspicion of bilateral subdural fluid hygroma, confirmed by cranial magnetic resonance imaging (MRI), with minor amounts of blood. The maximum width of the hygromas was 1 cm on both sides, and there was no evidence of ischemia. Internal carotid artery (ICA) stenosis due to dissection at the petrous segment was present in that stage but only diagnosed in retrospect (Figs. 1A–C). On day 4, the patient deteriorated with reduced activity, encephalopathy with intermittent eye deviation, and a bulging fontanel. Raised intracranial pressure due to progression of the bilateral subdural

hygroma, diagnosed by cranial ultrasound, led to neurosurgical evacuation with insertion of 2 subdural drains the same day. Preoperatively, a central venous line was inserted into the right internal jugular vein in a hyperextended position. After surgery, a left-sided hemiplegia was noticed in the operating theater. Subsequent computed tomography ruled out progressive intracerebral hemorrhage and drain displacement. However, the child's left hemiparesis persisted, and on day 7, transcranial ultrasound showed an extended right-sided intracranial hyperechogenicity including the basal ganglia and the contiguous cortex. This was identified as hemorrhagic transformation (HT II°) with cortical petechial hemorrhages by MRI, which additionally showed middle cerebral artery (MCA) and ICA occlusion with subsequent territory infarction (Figs. 2A–C). Transcranial color-coded sonography with ultrasound contrast agent (0.5 mL of Sonovue, Bracco, Italy) was additionally able to demonstrate minimal residual flow in the MCA and retrograde leptomeningeal collateralization of the infarcted area (Fig. 3). Based on these findings, anticoagulation therapy with intravenous heparin, 50 U/kg per day, was initiated. Two days after initiation, the heparin dose was increased to 100 U/kg per day after serial transcranial ultrasound findings did not show further increase of the HT area. The anticoagulation management was subsequently changed to subcutaneous enoxaparin (1.5 mg/kg/d) with a target peak anti-Xa level of 0.6 to 0.8 U/mL 10 days after the stroke occurred. In further diagnostic testing, there was no evidence for infection, coagulopathy, metabolic disorders, or cardiovascular disease. Despite no initial suspicion, the unusual diagnosis of an ICA dissection with associated stroke in an infant led to further investigations to rule out nonaccidental injury. However, the child abuse pediatric consultation, retinal examination, and skeletal survey revealed no further abnormalities. Because the grandmother was also injured in this event, physical child abuse was assessed as highly unlikely. The patient was discharged home 29 days after admission. On the day of discharge, the patient moved both legs equally, but a moderate paresis of the left arm was still present.

## DISCUSSION

Pediatric stroke is a relevant cause for mortality and long-term morbidity in pediatric patients. Risk factors include systemic hypertension, vasculopathy, cardiac disease, metabolic disorder, infection, and coagulopathy.<sup>1</sup> Internal carotid artery dissection as a cause for pediatric ischemic stroke is well-known, and the described pathomechanisms are direct trauma to the neck, blunt trauma to the soft palate, and traumatic hyperextension and/or hyperrotation in physical child abuse from shaking.<sup>2–6</sup> Stretching of the arteries in a minor head trauma has already been reported in a 7-year-old patient but, to the best of our knowledge, has not been described in infants so far.<sup>7</sup> The 4-month-old child described in this report suffered an ICA dissection with consecutive territorial stroke after a fall onto a stairway. Without a history of unconsciousness or vomiting and a Glasgow Coma Scale score of 15

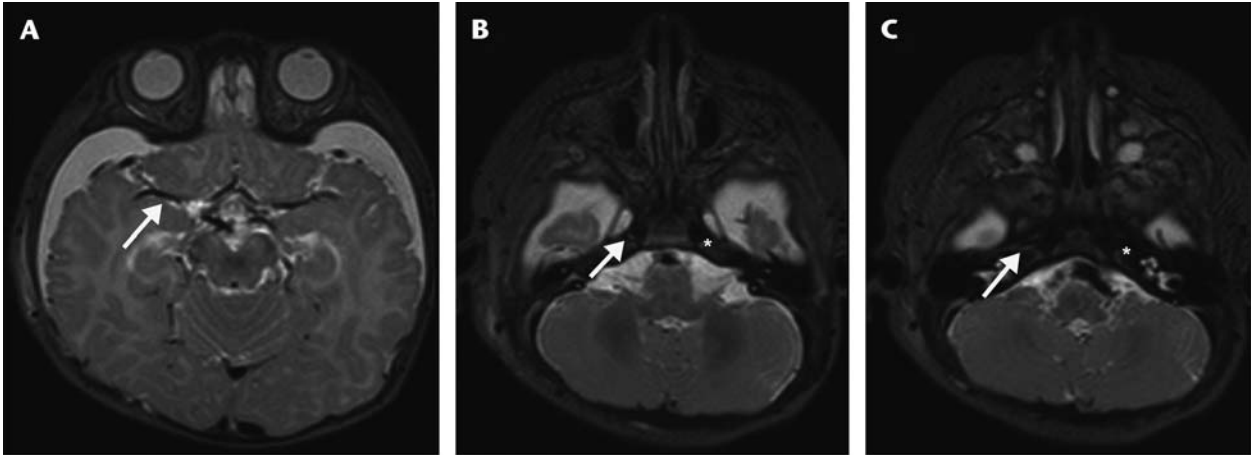
From the \*KUNO University Children's Hospital; †Department of Neurology, University of Regensburg; and ‡Department of Radiology, University Hospital Regensburg, Regensburg, Germany.

Disclosures: The authors declare no conflict of interest.

Reprints: Robert Zant, MD, KUNO University Children's Hospital, Franz-Josef-Strauß-Allee 11, 93053 Regensburg, Germany (e-mail: robert.zant@ukr.de).

Copyright © 2016 Wolters Kluwer Health, Inc. All rights reserved.

ISSN: 0749-5161



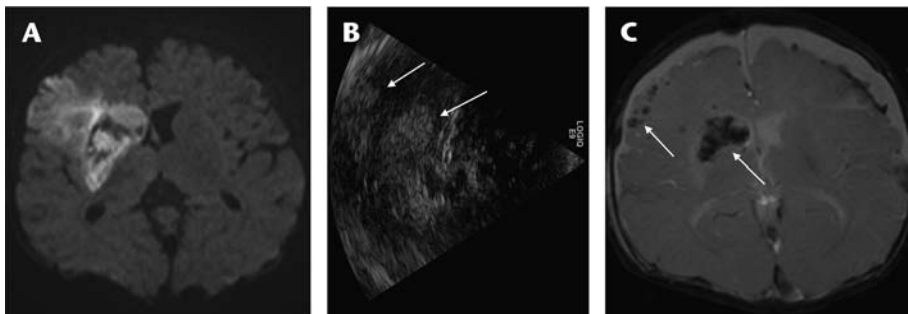
**FIGURE 1.** T2-Weighted magnetic resonance imaging performed on day 3 postadmission showing dissection of the right ICA (arrows) in comparison to the healthy left side (stars) and bilateral subdural hygroma.

on presentation to the emergency department, the head trauma has to be classified as “minor.”<sup>8</sup> Minor head injury as cause and cofactor for stroke has already been described in children. In those patients, prothrombotic risk factors such as factor V Leiden mutation and lesions in the basal ganglia due to traumatic rupture or endothelial damage of small end arteries were responsible for stroke.<sup>9,10</sup> However, in our case, further examination and laboratory testing did not reveal typical pediatric risk factors for ischemic stroke or carotid artery dissection as described previously. Hence, considering the insufficient head control of a 4-month-old child, the most likely pathomechanism for dissection of the carotid artery was hyperextension and/or hyperrotation of the head. The patient's stroke symptoms occurred after surgery, most likely associated with thromboembolism due to hyperextension of the neck during positioning for central venous line placement into the right internal jugular vein. His clinical symptoms, including left-sided weakness and focal seizures, were consistent with an MCA stroke. The intracranial hyperdensity diagnosed by MRI on the third day after occurrence of stroke symptoms is best defined as HT. Early presentation of HT is common in children and associated with an infarct volume more than 5% of the total supratentorial brain volume.<sup>11</sup> In adults, the risk of systemic anticoagulation and HT is discussed controversially.<sup>12,13</sup> However, in pediatric patients, the pathomechanisms of stroke and coagulation pathways are different than those in adults. Therefore,

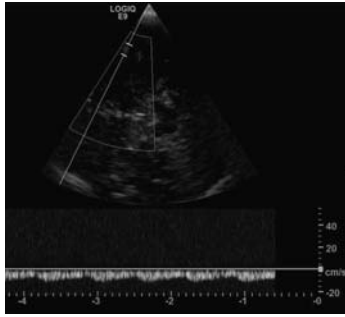
findings from clinical trials in adult patients cannot be transferred to pediatric patients.<sup>14</sup> So far, no clinical trial has assessed the risks and benefits of anticoagulation therapy in childhood acute stroke; current recommendations are based on the consensus opinions of experts.<sup>15</sup> Assuming thromboembolism as cause for the territorial stroke secondary to traumatic carotid artery dissection, we started low-dose anticoagulation with heparin under close neuromonitoring in our patient. After serial cranial ultrasounds showed a stable intracranial finding, we increased the heparin dose after 48 hours and finally changed to therapeutic anticoagulation with enoxaparin on day 10 poststroke occurrence. Under this regimen, we did not observe any adverse effects of anticoagulation in terms of increase of the HT area. Under treatment, the patient's stroke symptoms were constantly improving.

## CONCLUSIONS

Internal carotid artery dissection followed by consecutive thromboembolic territorial stroke is rare in infants. Causes include direct trauma to the neck, blunt trauma to the soft palate, and traumatic hyperextension and/or hyperrotation in physical child abuse from shaking. As described previously, minor head trauma associated with hyperextension/hyperrotation of the neck is an additional pathomechanism in this age group. However, because this is the first reported case, this mechanism is rare. In our



**FIGURE 2.** A, Diffusion-weighted MRI demonstrates ischemic infarction with signal irregularities in the basal ganglia due to hemorrhage susceptibility artifacts. B, Pulse inversion transcranial ultrasound presented as 90-degree clockwise rotation with depiction of the basal ganglia hemorrhagic transformation, as well as small petechial hemorrhages in the cortex (arrows). C, T2\*FLASH sequence demonstrating HT in the basal ganglia, frontoparietal ischemic cortex (arrows), and contralateral subdural space.



**FIGURE 3.** Transcranial color-coded ultrasound showing retrograde leptomeningeal collateralization of the infarcted area determined by pulsed wave Doppler.

case, treatment with anticoagulants was successful and not associated with adverse effects despite extended HT.

### REFERENCES

1. Lee EH, Yum MS, Ko TS. Risk factors and clinical outcomes of childhood ischemic stroke in a single Korean tertiary care center. *J Child Neurol.* 2012;27:485–491.
2. Payton TF, Siddiqui KM, Sole DP, et al. Traumatic dissection of the internal carotid artery. *Pediatr Emerg Care.* 2004;20:27–29.
3. Moriarty JM, Lukas C, Rossler L, et al. Carotid artery dissection following a minor household accident in a 10-month-old child. *Ir J Med Sci.* 2009;178:535–539.
4. Agner C, Weig SG. Arterial dissection and stroke following child abuse: case report and review of the literature. *Childs Nerv Syst.* 2005;21:416–420.
5. Mann CI, Dietrich RB, Schrader MT, et al. Posttraumatic carotid artery dissection in children: evaluation with MR angiography. *AJR Am J Roentgenol.* 1993;160:134–136.
6. Duke BJ, Partington MD. Blunt carotid injury in children. *Pediatr Neurosurg.* 1996;25:188–193.
7. Plunkett J. Fatal pediatric head injuries caused by short-distance falls. *Am J Forensic Med Pathol.* 2001;22:1–12.
8. Jennett B. Epidemiology of head injury. *Arch Dis Child.* 1998;78:403–406.
9. Kieslich M, Fiedler A, Heller C, et al. Minor head injury as cause and co-factor in the aetiology of stroke in childhood: a report of eight cases. *J Neurol Neurosurg Psychiatry.* 2002;73:13–16.
10. Shaffer L, Rich PM, Pohl KR, et al. Can mild head injury cause ischaemic stroke? *Arch Dis Child.* 2003;88:267–269.
11. Beslow LA, Smith SE, Vossough A, et al. Hemorrhagic transformation of childhood arterial ischemic stroke. *Stroke.* 2011;42:941–946.
12. Zetterling M, Carlström C, Konrad P. Internal carotid artery dissection. *Acta Neurol Scand.* 2000;101:1–7.
13. Kim JT, Heo SH, Park MS, et al. Use of antithrombotics after hemorrhagic transformation in acute ischemic stroke. *PLoS One.* 2014;9:e89798.
14. Monagle P, Chan AK, Goldenberg NA, et al. Antithrombotic therapy in neonates and children: Antithrombotic Therapy and Prevention of Thrombosis, 9th ed: American College of Chest Physicians Evidence-Based Clinical Practice Guidelines. *Chest.* 2012;141:e737S–e801S.
15. Roach ES, Golomb MR, Adams R, et al. Management of stroke in infants and children: a scientific statement from a Special Writing Group of the American Heart Association Stroke Council and the Council on Cardiovascular Disease in the Young. *Stroke.* 2008;39:2644–2691.