

Cerebral Embolism and Hyperthyroidism

YOSHIHIRO SATO, YOUSUKE SATO, SHINICHI KAKISAKO, YOSHIAKI HONDA
AND MASARO KAJI

*Department of Internal Medicine, Kurume University School of Medicine,
Kurume, 830 Japan*

Received for publication January 17, 1989

Summary: Three different cases of cerebral embolism occurring in combination with hyperthyroidism are reported. Case 1; a healthy 37-year-old woman presented with sudden onset of left hemiparesis and left sided hypoesthesia of all modalities. Embolism in area of the right middle cerebral artery was confirmed by angiography and CT scan. Laboratory examination revealed hyperthyroidism and anemia. Antithyroid treatment brought about euthyroid function while slight hemiparesis remained present. Case 2; a 79-year-old woman who suffered from hypertension for one year had sudden onset of disorientation and left hemiparesis. Electrocardiogram showed atrial fibrillation. The CT scan indicated infarction in the right anterior and middle cerebral artery. The patient was diagnosed as having masked hyperthyroidism. Although antithyroid medication reduced it to euthyroid condition, the patient is now bedridden with hemiparesis. Case 3; a 45-year-old man who had partial thyroidectomy for Basedow's disease and had been treated with antithyroid and antiarrhythmic therapy for 10 years. Suddenly, he was in coma with dilated right pupil and left hemiplegia. Atrial fibrillation and hypothyroid function were observed. CT scan indicated hemorrhagic infarction in the territory of the middle cerebral artery with transtentorial herniation. He died on the 59th day of hospitalization following an episode of bronchopneumonia. On the basis of the cases presented here as well as on the basis of those described in the literature it appears that thyrotoxic patients with atrial fibrillation exhibit high incidence of cerebral embolism, and prophylactic anticoagulant therapy may be recommended.

Key words: cerebral embolism—hyperthyroidism—Basedow's disease—atrial fibrillation—anticoagulant therapy

Introduction

The major cardiac causes of cerebral embolism today are nonvalvular atrial fibrillation and mural thrombus from myocardial infarction, as recently the general decline in rheumatic fever and rheumatic heart disease have reduced the incidence and pathologic basis for valvular heart disease (Scheinberg, 1988). Sherman et al. (1984, 1986) concluded that about 35% of

patients of nonvalvular atrial fibrillation would have a stroke during their life time and about 20% would face another cerebral infarction within a year from the initial ictus.

Atrial fibrillation develops in 10% to 15% of patients suffering from overt hyperthyroidism (Sandler and Wilson, 1959). High frequency of cerebral embolism was recorded recently in patients suffering from a combination of hyperthyroidism

and atrial fibrillation in the U.S.A., Australia or England (Staffurth et al. 1977; Yuen et al. 1979; Hurley et al. 1981; Bar-Sela et al. 1981). We report here three cases of cerebral embolism accompanied by hyperthyroidism.

Case Reports

Case 1;

a 37-year-old woman was admitted on May 11, 1986 due to a sudden onset of left-sided weakness. She had no history of tremor, hyperhidrosis, palpitation, or irritability.

Her blood pressure was 140/80mmHg, and her pulse rate, 120 per minute, was regular. Slight bilateral exophthalmus and anemic conjunctiva were noted. The thyroid gland was not felt. Carotid bruits

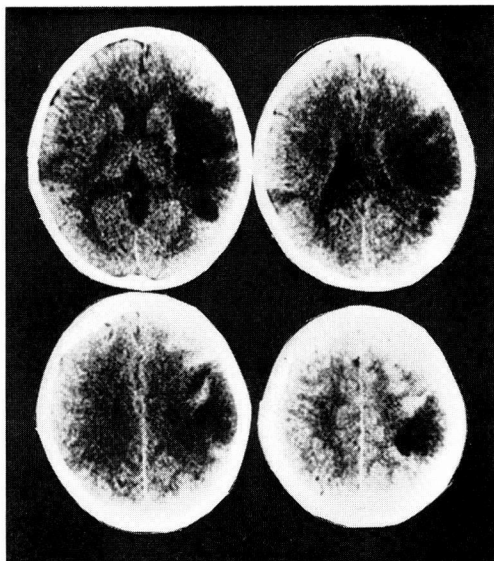


Fig. 1. A CT scan of Case 1, demonstrating cerebral infarction in the right temporo-parietal regions.

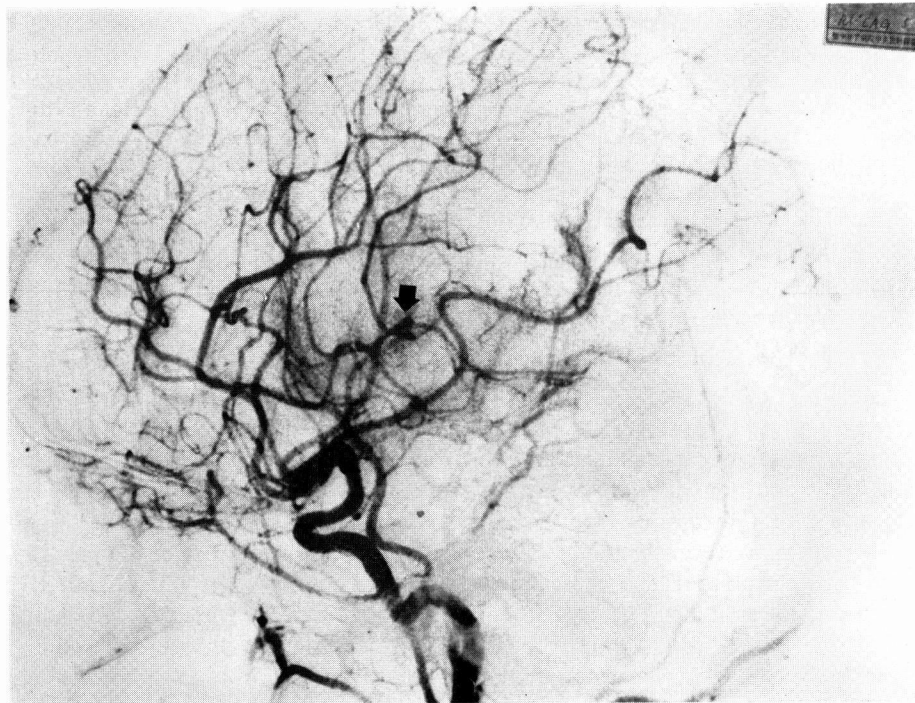

Fig. 2. Right carotid angiography of Case 1, showing obstruction of the parietal and temporooccipital arteries.

and apical systolic murmur were auscultated. Neurologic examination demonstrated alertness, left hemiparesis including face and tongue, left sided hypoesthesia of all modalities, and fine finger tremor.

Laboratory tests revealed microcytic, hypochromic anemia and hyperthyroidism. Pertinent results included red-blood cell count of $421 \times 10^4/\text{mm}^3$; hematocrit 24%; hemoglobin, 6.6 g/dl; serum thyroxine (T_3) 16.5 $\mu\text{g}/\text{dl}$; total triiodothyronine (T_4) 4.1 ng/ml and thyrotropine, 0.1 $\mu\text{U}/\text{ml}$. Titers of antimicrosomal and antithyroglobulin antibody were 1:25,600 and 1:400, respectively.

Electrocardiogram (ECG) revealed the presence of sinus tachycardia; two-dimensional echocardiography revealed no thrombi, chamber enlargement, or other abnormality. Holter ECG did not show any arrhythmia in a 24-hour recording.

The plain CT scan with 360 by 360 matrix showed a decreased radiodensity in an area of the right middle cerebral artery (Fig. 1). Examination of the patient by Seldinger's method with injection of 10 ml Metrizamide into the internal carotid artery revealed obstruction of the right parietal and temporo-occipital arteries (Fig. 2). Thus, she was diagnosed embolic cerebral infarction because the site of arterial obstruction was distal compared with extension of infarct size on CT scan.

After three weeks of Thiamazole treatment 15 mg daily, the thyroid function returned to normal (T_3 8.8 $\mu\text{g}/\text{dl}$, T_4 2.9 ng/ml). Six weeks later, she was discharged with slight left hemiparesis and euthyroid function.

Case 2; a 79-year-old woman was admitted on May 15, 1987 due to a sudden onset of left-sided weakness. She developed hypertension one year earlier and anti-hypertensive medication was prescribed at another hospital.

Her blood pressure was 144/66 mmHg. Pulse rate was 120 beats per minutes and irregular. The thyroid gland was felt slightly. The chest and abdomen were normal. The patient was disoriented and hemispatial agnosia was suspected. Moderate left hemiparesis which included tongue was present. Sensory impairment was uncertain because of the disorder of consciousness.

The pertinent laboratory test results were as follows: hematocrit, 38.9%; white-blood cell count, 11,600; alkaline phosphatase (Kind-King method), high at 11.5 unit; other liver function tests revealed no abnormalities. Serum electrolyte and renal function were within normal limit. Serum T_3 was 13.7 $\mu\text{g}/\text{dl}$; T_4 was 0.9 ng/ml. Serum thyrotropine was less than 0.02 $\mu\text{U}/\text{ml}$. Titers of antimicrosomal and antithyroglobulin antibody were both 1:400.

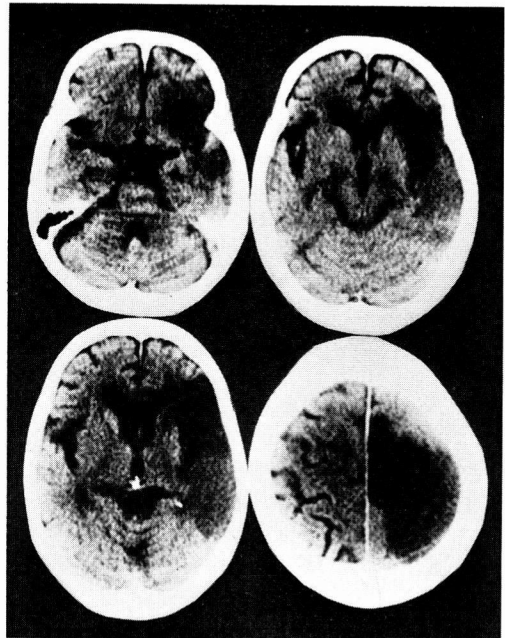


Fig. 3. A CT scan of Case 2, demonstrating infarction in the distribution of the right anterior and middle cerebral arteries.

Atrial fibrillation at a rate of 180 was revealed in the ECG. Areas of the right anterior and middle cerebral artery were attenuated in a CT scan (Fig. 3). It was concluded that the patient suffered from masked hyperthyroidism, atrial fibrillation and cerebral embolism of cardiac origin.

Following Glycerol and Thiamazole 15 mg daily, the thyroid function recovered (T_3 8.5 $\mu\text{g}/\text{dl}$, T_4 0.7 ng/ml) and the patient regained her consciousness. The left hemiparesis and atrial fibrillation persisted, however, and the patient was bedridden ever since.

Case 3; a 45 year-old-man who had a sudden onset of left-sided weakness was admitted on September 15, 1988. He had been suffering from Basedow's disease, hypertension and arrhythmia for ten years. Partial thyroidectomy was performed and antithyroid and antiarrhythmic therapy was instituted.

Blood pressure was 148/98 mmHg. Pulse rate was 84 per minute and irregular. The thyroid gland was not palpable. The chest and abdomen were normal. The patient exhibited slight drowsiness and left hemiplegia which included the face. On the next day he was comatous and his right pupil was dilated.

The laboratory test results were as follows: hematocrit, 46.2%; white-blood cell count, 13,700; liver and renal function were normal. Serum T_3 was 2.3 $\mu\text{g}/\text{dl}$, T_4 0.2 ng/ml and thyrotropine 3.2 $\mu\text{U}/\text{ml}$ indicated hypothyroidism.

The ECG revealed presence of atrial fibrillation at a rate of 90 per minute. A plain CT scan performed on the second day following the admission showed hemorrhagic infarction in the distribution of the right middle cerebral artery (Fig. 4). The patient was diagnosed as suffering from hemorrhagic cerebral embolism with transtentorial herniation caused by the atrial fibrillation.

Although the patient received external

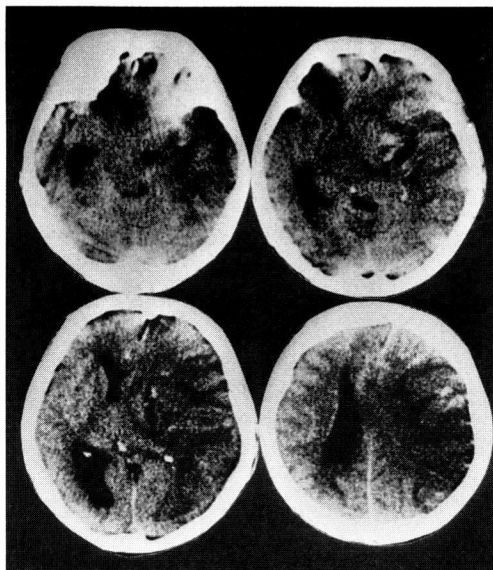


Fig. 4. A CT scan of Case 3, showing hemorrhagic infarction in the distribution of the right middle cerebral artery with transtentorial herniation.

decompression for increased intracranial pressure and artificial respiration and total parenteral nutrition were initiated on the second day following admission, the patient died on the 59th day of hospitalization of complications which included bronchopneumonia; he never regained consciousness.

Discussion

These three cases had different pathologic basis. In case 1, hypertyroidism was recognized only after the onset of cerebral embolism. Staffurth et al. (1977) reported three cases in which hyperthyroidism preceded the embolus. There are no literature reports available at this time, as to the absence of arrhythmias in hyperthyroidism associated with cerebral embolism. Bar-Sela et al. (1981) reported that 12 embolic complications were found in 30 patients presenting with thyrotoxic

atrial fibrillation, while other 112 patients had no episodes in sinus rhythm.

With respect to case 2, cerebral embolism occurred in an elder patient who had masked hyperthyroidism and presented with atrial fibrillation. Several authors emphasized the presence of masked hyperthyroidism in elderly patients with atrial fibrillation (Forfar and Toft, 1982; Tajiri et al. 1986; Bruce et al. 1987). There is no such case as masked hyperthyroidism was recognized only after the onset of cerebral embolism. Petersen and Hansen (1988) found a tendency toward stroke in hyperthyroidism with atrial fibrillation but statistical evidence indicated that atrial fibrillation is an independent risk factor during the first year after the diagnosis of hyperthyroidism. They concluded that age was the only significant risk factor for stroke. Since they did not use the CT scan for their study, their diagnosis of cerebral embolism is not certain.

With respect to case 3, cerebral embolism seemed to have been caused by continuous atrial fibrillation in the presence of hypothyroidism function. Staffurth et al. (1977) reported that 10 patients who had persistent atrial fibrillation in euthyroid state presented with emboli. The patient represented in case 3, died in the condition of transtentorial herniation after neurosurgical treatment. Parker and Lawson (1973) analyzed the death causes of 33 thyrotoxic patients and found that cerebrovascular accident was the cause of death in two of these patients.

On the basis of the cases presented here as well as on the basis of those described in the literature (Staffurth et al. 1977; Yuen et al. 1979; Hurley et al. 1981), it appears that thyrotoxic patients with atrial fibrillation exhibit high incidence of cerebral embolism, and prophylactic anticoagulant therapy may be recommended.

References

- BAR-SELA, S., EHRENFELD, M. and ELIAKIM, M. (1981). Arterial embolism in thyrotoxicosis with atrial fibrillation. *Arch. Intern. Med.* **141**, 1191-1192.
- BRUCE, S.A., RANGEDARA, D.C., LEWIS, R.R. and CORLESS, D. (1987). Hyperthyroidism in elderly patients with atrial fibrillation and normal thyroid hormone measurements. *J. Royal Soc. Med.* **80**, 74-76.
- FORFAR, J.C. and TOFT, A.D. (1982). Thyrotoxic atrial fibrillation: an underdiagnosed condition? *Br. Med. J.* **2**, 909-910.
- HURLEY, D.M., HUNTER, A.N., HEWETT, M.J. and STOCKIGT, J.R. (1981). Atrial fibrillation and arterial embolism in hyperthyroidism. *Aust. N.Z.J. Med.* **11**, 391-393.
- PARKER, J.L.W. and LAWSON, D.H. (1973). Death from thyrotoxicosis. *Lancet* **2**, 894-895.
- PETERSEN, P. and HANSEN, J.M. (1988). Stroke in thyrotoxicosis with atrial fibrillation. *Stroke* **19**, 15-18.
- SANDLER, G. and WILSON, G.M. (1959). The nature and prognosis of heart disease in thyrotoxicosis. A review of 150 patients treated with I. Q. *J. Med.* **28**, 347-369.
- SCHNEIBERG, P. (1988). Controversies in the management of cerebral vascular disease. *Neurology* **38**, 1609-1616.
- SHERMAN, D.G., GOLDMAN, L., WHITING, R.B., JURGENSEN, K., KASTE, M. and EASTON, J.D. (1984). Thromboembolism in patients with atrial fibrillation. *Arch. Neurol.* **41**, 708-710.
- SHERMAN, D.G., HART, R.G. and EASTON, J.D. (1986). The secondary prevention of stroke in patients with atrial fibrillation. *Arch. Neurol.* **43**, 68-70.
- STAFFURTH, J.S., GIBBERT, M.C. and TANGFUI, S.N.G. (1977). Arterial embolism in thyrotoxicosis with atrial fibrillation. *Br. Med. J.* **2**, 668-690.
- TAJIRI, J., HAMASAKI, S., SHIMADA, T., MORITA, M., HIGASHI, K., OHISHI, S. and SATO, T. (1986). Masked thyroid dysfunction among elderly patients with atrial fibrillation. *Jpn. Heart J.* **27**, 183-190.
- YUEN, R.W.M., GUTTERIDGE, D.H., THOMPSON, P.L. and ROBINSON, J.S. (1979). Embolism in thyrotoxic atrial fibrillation. *Med. J. Aust.* **1**, 630-631, 1979.