



Contents lists available at ScienceDirect

Journal of Clinical Neuroscience

journal homepage: www.elsevier.com/locate/jocn

Case report

Neurological deficit following stereotactic radiosurgery for trigeminal neuralgia

S. Kemp^a, R.S. Allan^a, N. Patanjali^a, M.H. Barnett^{a,b}, B.P. Jonker^{a,b,*}^aRPA Institute of Academic Surgery and Department of Neurosurgery, Royal Prince Alfred Hospital, Missenden Road, Camperdown, NSW 2050, Australia^bBrain and Mind Centre, University of Sydney, Camperdown, NSW 2050, Australia

ARTICLE INFO

Article history:

Received 21 November 2015

Accepted 6 September 2016

Available online xxxx

Keywords:

MS

Multiple sclerosis

SRS

Stereotactic radiosurgery

TN

Trigeminal neuralgia

ABSTRACT

We report a unique case of neurological deficit from late onset multiple sclerosis (MS), in a 65-year-old woman, after stereotactic radiosurgery (SRS) for trigeminal neuralgia (TN). At 3.5 months post-SRS for TN, the patient developed ataxia and left leg paraesthesiae and brain MRI showed altered signal and enhancement in the vicinity of the right trigeminal root entry zone (REZ). The symptoms remitted following treatment with intravenous methylprednisolone, however, 10 months post-SRS, the patient developed gait ataxia and left lower limb weakness. MRI showed persistent T2 changes at the REZ and multiple new non-enhancing white matter lesions in the cerebrum and spinal cord; and oligoclonal bands were present in the cerebrospinal fluid but not serum. A diagnosis of multiple sclerosis (MS) was made. This report raises the issue of whether the risk of radiation-induced toxicity is increased in patients with MS treated with SRS. We hypothesise that breakdown in the blood brain barrier secondary to the radiosurgery may have triggered a vigorous local inflammatory response.

© 2016 Elsevier Ltd. All rights reserved.

1. Introduction

Trigeminal neuralgia (TN) is a severe and potentially debilitating facial pain syndrome that can be treated medically or with surgery or stereotactic radiosurgery (SRS). The pathophysiology of TN pain is thought to relate to ephaptic transmission in the trigeminal pathways secondary to focal demyelination and axonal injury [1]. Treatment of idiopathic TN with microvascular decompression (MVD) yields the longest lasting pain control [2], but unlike idiopathic TN, MVD in multiple sclerosis (MS)-related patients does not reliably result in a long duration of pain freedom. This is presumably because the root entry zone (REZ) abnormality is caused by an MS related inflammatory response rather than vascular compression [3]. Neuroablative procedures including percutaneous rhizotomy and SRS may be preferable in patients with MS, although even these approaches tend to result in a shorter duration of pain freedom [3].

SRS, both as primary and secondary therapy, represents a minimally invasive alternative in medically refractory TN in MS that has produced good results with pain resolution [3,4]. Facial numbness is the most common side effect and occurs to some extent in

up to 66% of patients treated with SRS in some studies, though these symptoms are seldom severe or debilitating [5]. Radiosurgery for TN in patients with MS is an accepted therapy [4], although there has been anecdotal suggestion that patients with demyelinating diseases who receive radiosurgery or radiotherapy are at an increased risk of treatment-related neurotoxicity [6]. Here we report a patient treated with SRS for recurrent TN following MVD, who developed neurological deficits following treatment, potentially due to an exaggerated inflammatory response triggered by SRS.

2. Case report

A 65-year-old woman with right-sided typical TN, underwent a trigeminal MVD procedure. A vein was found at surgery and coagulated and divided. Despite the absence of arterial compression, complete remission of pain was achieved. However, 14 months later, the symptoms recurred and the patient was referred for SRS. The radiosurgical treatment was given using a Novalis Tx LINAC device (BrainLAB AG, Feldkirchen, Germany) and followed a standard protocol with a 90 Gray point dose delivered to the REZ and the 50% isodose line tangential to the pons. The treatment utilised seven non-coplanar arcs delivered with the 4 mm collimator using a frameless radiosurgery setup (ExacTrac). The SRS was uneventful and the patient was discharged the same day.

* Corresponding author at: RPA Institute of Academic Surgery and Department of Neurosurgery, Royal Prince Alfred Hospital, Missenden Road, Camperdown, NSW 2050, Australia. Fax: +61 2 8580 4867.

E-mail address: drjonker@centralneurosurgery.com.au (B.P. Jonker).

At 21 days post-SRS the patient was pain free and gabapentin was weaned. Three months post-SRS the patient experienced right-sided facial numbness and remained pain free. At this point she was reassured that facial numbness in this context is common and not unexpected and has been shown to have a positive correlation with good pain outcome [7]. However, 2 weeks after the onset of facial numbness the patient experienced left-sided upper and lower limb paraesthesia and ataxic gait. Repeat MRI showed irregular enhancement of the brainstem at the level of the right trigeminal REZ (Fig. 1). In contrast, no changes in the root entry zone had been seen on three separate MRIs performed within 2 years leading up to surgery, nor on two MRIs performed between surgery and radiosurgery. The newly visualised enhancement extended posteriorly from the REZ towards the ventricle incorporating areas that had received only very low dose (<4 Gy). Nonetheless, a presumptive diagnosis of radiation-induced neurotoxicity was made and pulsed intravenous methylprednisolone was administered. Over the next few months the patient's gait normalised and she remained pain free.

At 10 months post-SRS, following a viral upper respiratory tract infection, the patient developed left lower limb weakness and recurrent gait ataxia. Repeat MRI disclosed persistent T2 signal change at the right trigeminal REZ, multiple non-enhancing cerebral white matter lesions and a lesion in the cervical spinal cord consistent with demyelination (Fig. 2). The cerebrospinal fluid was acellular with oligoclonal bands that were not present in the serum. A diagnosis of relapsing MS was made, and methylprednisolone and disease-modifying therapy (fingolimod) commenced. Six months later the patient had largely returned to baseline but continued to have a mild persistent gait disturbance. On most recent review, 3 years post-SRS, the patient had recurrence of her right-sided TN in V3 for which she manages with pregabalin BD.

3. Discussion

Previous anecdotal reports of radiation neurotoxicity in patients with MS include nerve palsies and hydrocephalus, as well as death due to progressive demyelination [8–10].

Oligodendrocytes and oligodendrocyte progenitor cell injury, alteration of cytokines, changes in vascular permeability and disruption of the blood brain barrier induced by SRS are potential mechanisms [9,10]. Whether patients with demyelinating diseases are more susceptible to the neurotoxic effects of radiotherapy is still uncertain.

Our patient, without a prior diagnosis of MS, had the onset of neurological deficit, now believed due to an inflammatory lesion, at 3.5 months after radiation exposure. This is consistent with the timeframe for previous reports on radiation-associated demyelination [8]. Our hypothesis is that breakdown of the blood brain barrier at the site of the radiosurgery facilitated a vigorous inflammatory response at the REZ. In retrospect, it is likely that occult MS pathology at this site, not visualised on prior imaging, predated SRS and was responsible for the patient's initial presentation of TN.

It is unclear whether, in the absence of SRS, our patient would have gone on to develop clinical MS, particularly given MS rarely presents after the age of 59 [11]. Reports of MS flare following irradiation remain anecdotal and the majority follow conventional radiotherapy, which utilises larger field sizes but smaller doses. Notably, the report from Zorro et al. dealing specifically with SRS for MS induced TN did not report MS flares [4]. Whilst we continue to treat patients who have MS with SRS we now specifically warn that there is an undefined risk of exacerbation of MS with this treatment.

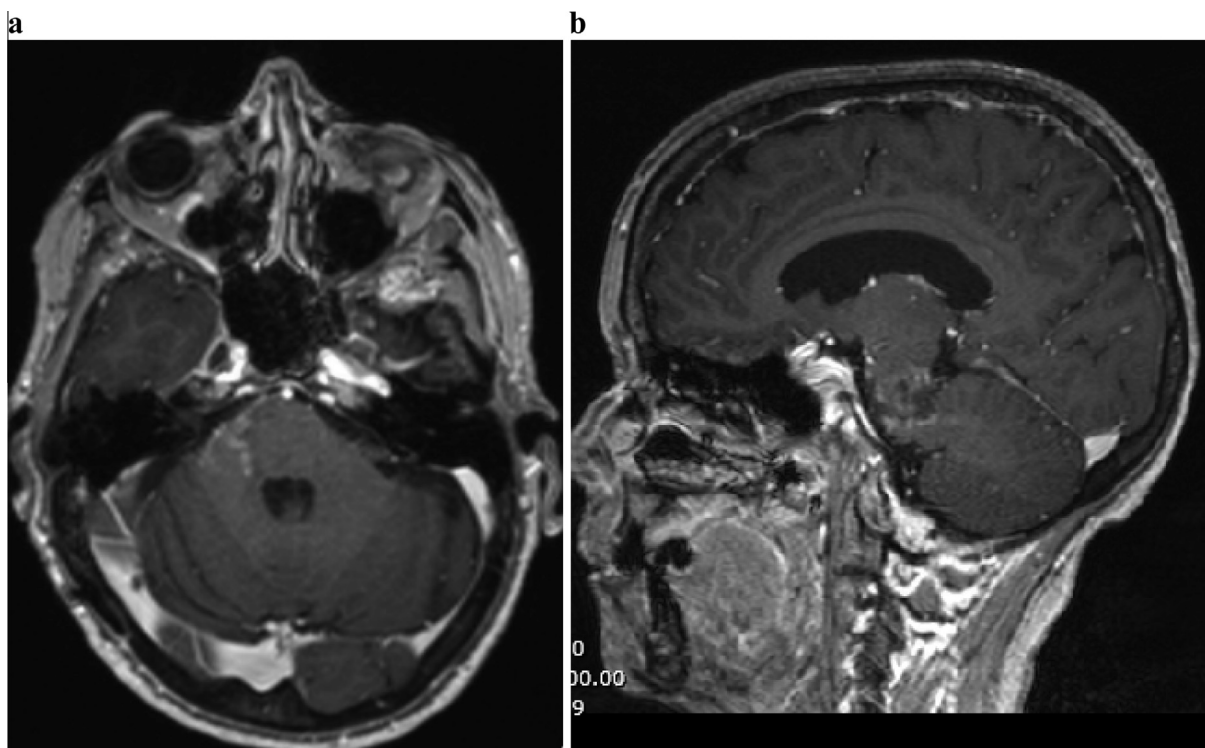


Fig. 1. (a) Axial T1- and (b) sagittal T1-weighted post gadolinium MRI acquired 3 months post-stereotactic radiosurgery: nodular enhancement at the level of the right trigeminal root entry zone.

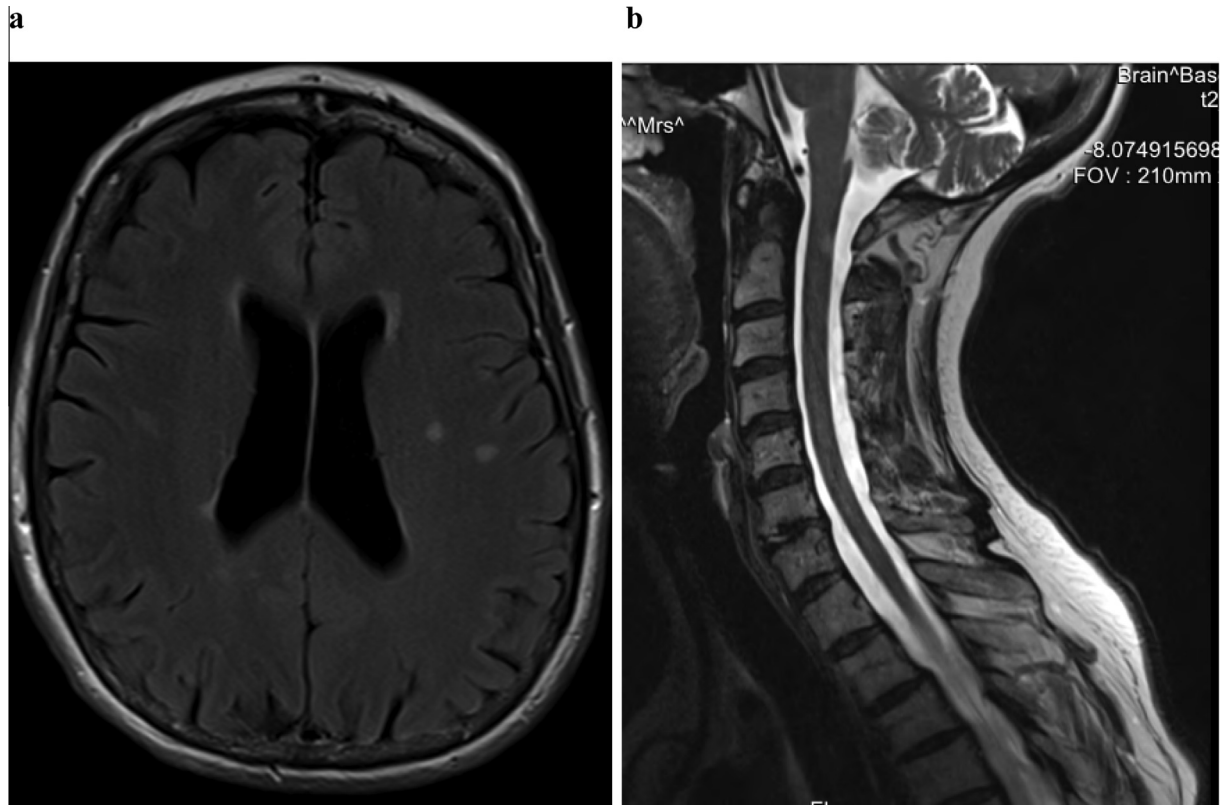


Fig. 2. (a) Axial fluid attenuated inversion recovery MRI, 10 months post-stereotactic radiosurgery for trigeminal neuralgia showing multiple deep white matter and periventricular lesions and (b) sagittal T2-weighted MRI showing a cervical cord lesion consistent with inflammatory demyelination.

Conflicts of interest/disclosures

The authors declare that they have no financial or other conflicts of interest in relation to this research and its publication.

References

- [1] Cruccu G, Biasiotta A, Di Rezze S, et al. Trigeminal neuralgia and pain related to multiple sclerosis. *Pain* 2009;143:186–91.
- [2] Tatli M, Satici O, Kanpolat Y, et al. Various surgical modalities for trigeminal neuralgia: literature study of respective long-term outcomes. *Acta Neurochir* 2008;150:243–55.
- [3] Montano N, Papacci F, Cioni B, et al. What is the best treatment of drug-resistant trigeminal neuralgia in patients affected by multiple sclerosis? A literature analysis of surgical procedures. *Clin Neurol Neurosurg* 2013;115:567–72.
- [4] Zorro O, Lobato-Polo J, Kano H, et al. Gamma knife radiosurgery for multiple sclerosis-related trigeminal neuralgia. *Neurology* 2009;73:1149–54.
- [5] Gorgulho A, De Salles AA, McArthur D, et al. Brainstem and trigeminal nerve changes after radiosurgery for trigeminal pain. *Surg Neurol* 2006;66:127–35 [discussion 35].
- [6] Lowell D, Tatter SB, Bourland JD, et al. Toxicity of gamma knife radiosurgery in the treatment of intracranial tumors in patients with collagen vascular diseases or multiple sclerosis. *Int J Radiat Oncol Biol Phys* 2011;81:e519–24.
- [7] Pollock BE. Radiosurgery for trigeminal neuralgia: is sensory disturbance required for pain relief? *J Neurosurg* 2006;105:103–6.
- [8] Miller RC, Lachance DH, Lucchinetti CF, et al. Multiple sclerosis, brain radiotherapy, and risk of neurotoxicity: the Mayo Clinic experience. *Int J Radiat Oncol Biol Phys* 2006;66:1178–86.
- [9] Belka C, Budach W, Kortmann RD, et al. Radiation induced CNS toxicity—molecular and cellular mechanisms. *Br J Cancer* 2001;85:1233–9.
- [10] Behin A, Delattre JY. Complications of radiation therapy on the brain and spinal cord. *Semin Neurol* 2004;24:405–17.
- [11] Hooge JP, Redekop WK. Multiple sclerosis with very late onset. *Neurology* 1992;42:1907–10.