

## Letter to the Editor

### Isolated intermittent bilateral hearing loss revealing a brain hemorrhage


**Keywords:**

Intermittent hearing loss  
Dural arteriovenous fistula  
Intracranial hemorrhage  
Aphasia  
Seizure

Dear Editor,

Hearing loss fluctuation is a rare condition. A central nervous system affection or an auto-immune disorders are the most frequent associated causes [1]. In auto-immune disorders, hearing loss fluctuation usually lasts for several hours or days. Brief acute bilateral intermittent sudden hearing loss, lasting less than 1 min, has not been reported so far. Additionally, no case of brief intermittent hearing loss revealing a central nervous system lesion has been described. We report the case of a dural arteriovenous fistula (DAVF)-related brain hemorrhage in a patient presenting with an isolated brief bilateral intermittent hearing loss.

A right handed 61 year-old male patient was referred to our ENT department for “sudden hearing loss”. Patient complained about a bilateral hearing loss upon awakening. Relevant past medical history included sigmoid sinus DAVF on the left side, which has been followed-up for several years. DAVF was asymptomatic and never treated. The patient didn't report any headache, vertigo or tinnitus. Despite his complaint, it seemed that he understood the speaker during the examination. The speaker needed to raise his voice from time to time in order for the patient to understand. Clinical examination was normal without any neurological sign, no nystagmus nor any oculomotor deficit. Otoscopy was normal. The day after, during the audiometry test, the patient still complained about his hearing loss lasting longer and longer (but still less than 5 min). Pure tone audiometry was normal, however the patient had bilateral vocal audiometry impairment (Fig. 1).

Tonal and vocal audiometry dissociation on both sides led us to suspect a central nervous system disorder. Based on these findings and his medical history of DAVF, he was admitted for further investigation. During the following hours, confusion appeared with spatial disorientation and speech disturbances, associated with a right homonymous hemianopia. MRI was performed in emergency, which showed a left temporal hemorrhage (Fig. 2A, B). Electroencephalogram was normal. A diagnostic angiography confirmed a type IV DAVF responsible for the hemorrhage (Fig. 2C). Endovascular therapy was conducted with a transarterial embolization using Onyx through the meningeal artery. Afterwards, the hematoma was treated surgically. The main post-operative deficit was a Wernicke aphasia, which improved gradually during the follow-up, with a cognitive rehabilitation.

Bilateral hearing loss is often related to central auditory pathways dysfunction, especially when vocal and tonal audiometry dissociation

is observed [2,3]. In this context, brain imaging (e.g. MRI) should be performed in emergency to rule out a central nervous lesion, even without any other neurological sign. Cases of bulbopontine junction infarctions revealed by sudden bilateral hearing loss and vertigo without any other neurological symptom have been reported [4].

In the present case, the hemorrhagic lesion was consecutive to a DAVF rupture. DAVFs are commonly diagnosed in the work-up of headaches, but other manifestations may also be associated such as cognitive impairment or seizures [5]. The risk of hemorrhage depends on the DAVF type according to the Cognard classification: affection of the main sinuses with anterograde (type I) or retrograde (type II) flow, direct cortical venous drainage without (type III) or with venous ectasia (type IV) [6]. Type V is similar to type IV associated with spinal drainage. Our patient was affected by a type IV DAVF in the presence of cortical venous drainage with venous ectasia (Fig. 2C), known to be associated with a high hemorrhage risk (65%) [7].

Brief and intermittent bilateral hearing loss was the unique symptom initially reported by the patient. This clinical presentation has never been described as a clinical presentation for ruptured DAVF. The audiometry is therefore a simple test to perform when the central auditory pathways involvement is suspected, confirming the diagnosis by a tonal and vocal dissociation.

Two main hypotheses should be considered to explain the clinical presentation in our patient. First, the mass effect exerted by the hematoma on the thalamus and, as a consequence, the auditory radiations. Indeed, the central auditory pathway involves several structures including the cochlear nucleus, superior olivary complex, inferior colliculus, medial geniculate body, and the auditory cortex. The medial geniculate body located in the thalamus transmits tone auditory information to the auditory cortex. Therefore, a lesion in this pathway leads to a retrocochlear hearing loss, as reported by Park et al. with a case of unilateral thalamic lesion responsible for subnormal PTA score contrasting with a decreased score of bilateral vocal audiometry, due to the deterioration of synchronous neural responses [8]. In our case, the isolated decreased vocal audiometry scores may be explained by an edema compression with unilateral thalamic lesion, consistent with the fact that the patient conversation remained possible at the onset, contrary to only one parietal lobe affection. However, this hypothesis may not explain the intermittent feature of the clinical presentation. Brain imaging was not performed at admission, therefore it is challenging to conclude that bilateral intermittent hearing loss is consecutive to the hemorrhage. Secondly, seizures of the temporal lobe may be responsible for intermittent aphasia. Although EEG was normal, this exam was not performed during the ictus. This hypothesis was suggested by the delayed confusion, explaining the fluctuating symptoms.

Both mechanisms may probably be involved: auditory radiations compression by the hematoma responsible for the isolated vocal audiometry alteration and seizures occurrence afterwards.

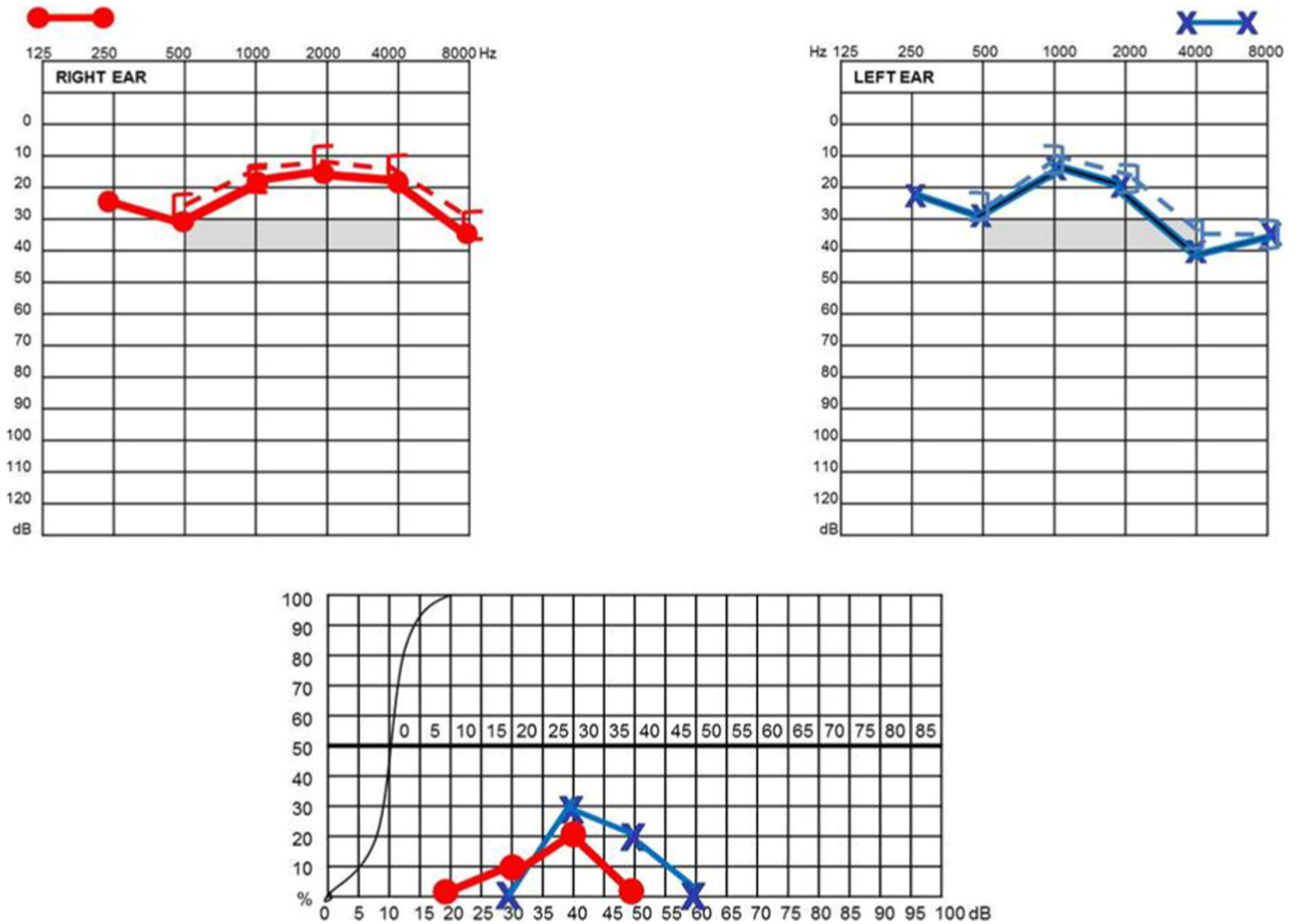


Fig. 1. Pure tone average (PTA) and vocal audiometry. PTA audiometry threshold was normal on both sides whereas vocal audiometry scores were poor.

**Conclusion**

Intermittent bilateral hearing loss is a condition which may reveal a central nervous system lesion, not only in the brainstem but also in the cortico-thalamic pathways. Vocal audiometry is mandatory to explore sudden hearing loss. A normal tonal audiometry associated with a

severe affection of vocal test, in the setting of sudden bilateral hearing loss, strongly suggests a central auditory pathways lesion.

**References**

[1] J. Veldman, Immune-mediated sensorineural hearing loss, *Auris Nasus Larynx* 25 (3) (Sep. 1998) 309-317.

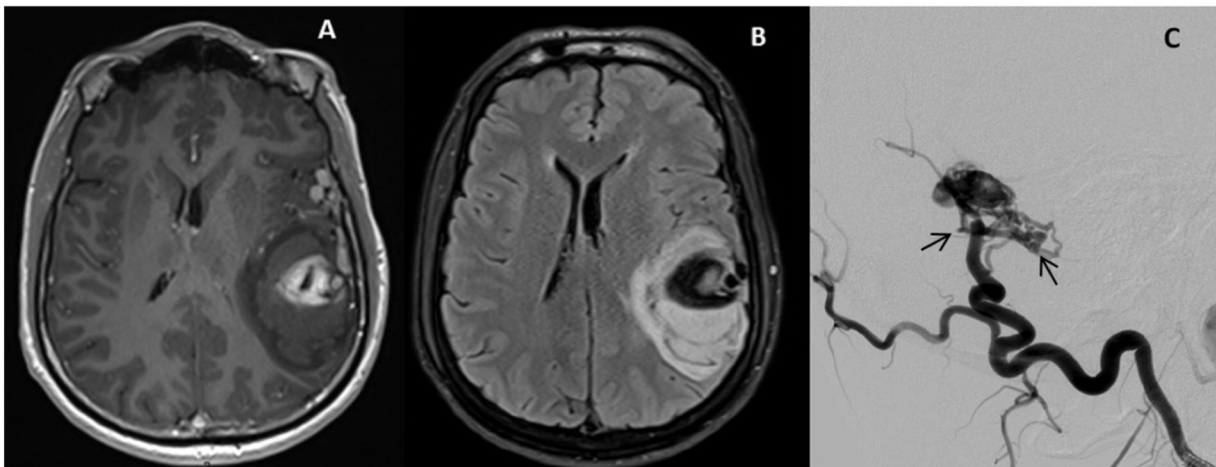


Fig. 2. (A), T1-weighted with gadolinium enhanced and (B) FLAIR weighted MRI images showing a left temporal hemorrhage associated with a mass effect with compression of the left lateral ventricle. (C), Arteriography showing a type IV DAVF with venous ectasias (arrows).

- [2] S.-K. Mun, Y.-H. Hong, S.-H. Kang, S.-N. Hwang, A case of temporal intracerebral hemorrhage that presented with sudden bilateral hearing loss as the initial symptom, *J. Korean Neurosurg. Soc.* 48 (5) (Nov. 2010) 438–440.
- [3] M.-J. Park, S.-W. Yoon, K.-H. Kim, Y.-J. Kim, A case of acute bilateral retrocochlear hearing loss as an initial symptom of unilateral thalamic hemorrhage, *Korean J. Audiol.* 18 (2) (Sep. 2014) 80–84.
- [4] R. Bovo, R. Ortore, A. Ciorba, A. Berto, A. Martini, Bilateral sudden profound hearing loss and vertigo as a unique manifestation of bilateral symmetric inferior pontine infarctions, *Ann. Otol. Rhinol. Laryngol.* 116 (6) (Jun. 2007) 407–410.
- [5] J.M.C. van Dijk, K.G. terBrugge, R.A. Willinsky, M.C. Wallace, Clinical course of cranial dural arteriovenous fistulas with long-term persistent cortical venous reflux, *Stroke J. Cereb. Circ.* 33 (5) (May 2002) 1233–1236.
- [6] D.J. Daniels, A.K. Vellimana, G.J. Zipfel, G. Lanzino, Intracranial hemorrhage from dural arteriovenous fistulas: clinical features and outcome, *Neurosurg. Focus.* 34 (5) (May 2013) E15.
- [7] C. Cognard, Y.P. Gobin, L. Pierot, A.L. Bailly, E. Houdart, A. Casasco, J. Chiras, J.J. Merland, Cerebral dural arteriovenous fistulas: clinical and angiographic correlation with a revised classification of venous drainage, *Radiology* 194 (3) (Mar. 1995) 671–680.
- [8] M.-J. Park, S.-W. Yoon, K.-H. Kim, Y.-J. Kim, A case of acute bilateral retrocochlear hearing loss as an initial symptom of unilateral thalamic hemorrhage, *Korean J. Audiol.* 18 (2) (Sep. 2014) 80–84.

A. Paul

*Otolaryngology - Head and Neck Surgery Department, Hôpital Lariboisière,  
Université Paris VII, Paris, France*

M. Mazighi

*Neurology Department, Hôpital Lariboisière, Département Hospitalo-  
Universitaire NeuroVasculaire, Université Paris VII, INSERM 1148,  
Laboratory of Vascular Translational Science, Paris, France*

S. Lenck

*Neuroradiology Department, Hôpital Lariboisière, Université Paris VII, Paris,  
France*

D. Bresson

*Neurosurgery Department, Hôpital Lariboisière, Université Paris VII, Paris,  
France*

P. Herman

*Otolaryngology - Head and Neck Surgery Department, Hôpital Lariboisière,  
Université Paris VII, Paris, France*

C. Hautefort\*

*Otolaryngology - Head and Neck Surgery Department, Hôpital Lariboisière,  
Université Paris VII, Paris, France*

Corresponding author at: Service d'ORL et chirurgie cervico-faciale -  
Hôpital Lariboisière, 2 rue Ambroise Paré, 75475 Paris Cedex 10, France.  
E-mail address: [charlotte.hautefort@aphp.fr](mailto:charlotte.hautefort@aphp.fr)

25 April 2016

Available online 30 August 2016