

LETTER TO THE EDITOR

Hypersensitivity to an intracerebral stent and symptomatic cerebral lesions: A possible link?

Dear Editor,

Contact hypersensitivity to metals is frequent in the general population but allergic patients often tolerate medical implants containing those metals.¹ Here, we report the case of a patient with severe nickel hypersensitivity presenting with neurological symptoms and cerebral lesions, which developed after the implantation of a nickel-containing stent.

A 45-year-old woman presented with recurrent paresthesia on the left side of the body 3 weeks after stenting of a right internal carotid aneurysm with a nickel-containing stent (Pipeline[®] flex embolization device [diverter flow]; ev3, Paris, France). Magnetic resonance imaging (MRI) showed gadolinium-enhancing lesions located downstream of the stent and surrounding edema. An infectious or ischemic cause was excluded. Steroid treatment was administrated for 8 months. Symptoms and lesions cleared progressively. Three weeks

after the withdrawal of steroid treatment, the patient presented with a relapse. MRI showed a moderate worsening of the known cerebral lesions and steroid treatment was reintroduced and is currently ongoing. Based on previous reports of allergic reactions to cerebral aneurysm clips,^{1,2} a delayed hypersensitivity to the stent was suspected in our patient.

Epicutaneous patch tests were performed with the European baseline series (Hermal, Reinbek, Germany) and a personal series, which included the stent, with IQ Ultra[®] patch test chambers (Chemotechnique Diagnostics, Vellinge, Sweden). Readings were performed on the 4th day. Patch testing with the stent was positive (+) and the skin biopsy of the reaction showed epidermal intercellular edema (spongiosis) with a dermal lymphocytic infiltrate containing a few eosinophils (Fig. 1), consistent with a delayed hypersensitivity reaction. The stent was composed of 75% cobalt chromium, 25% platinum tungsten and less than 2%

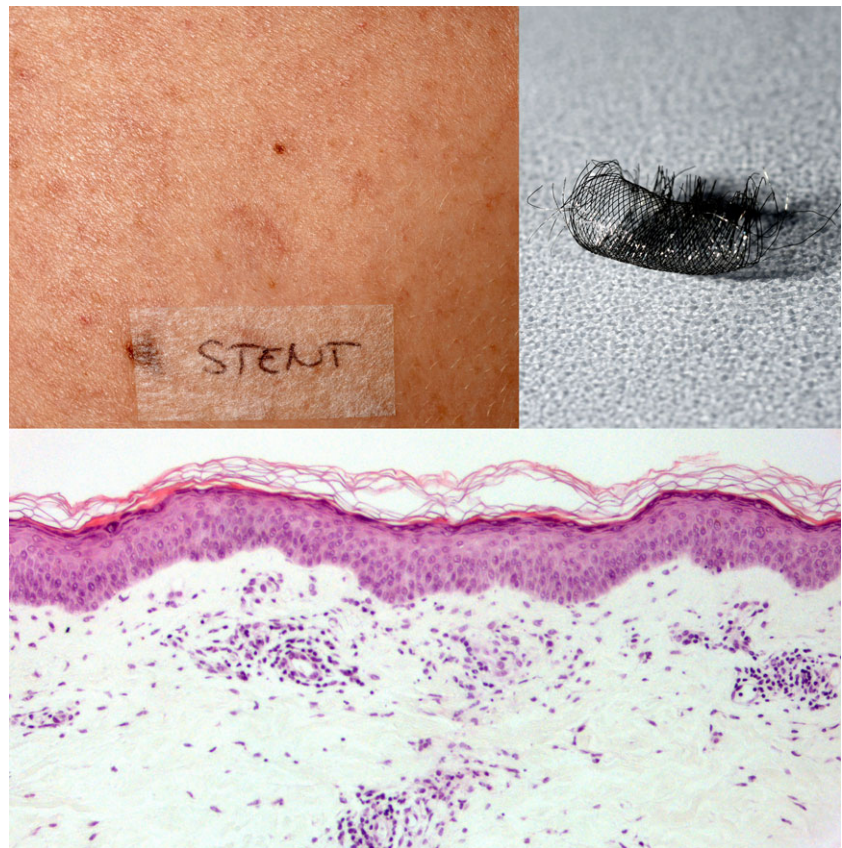


Figure 1. Clinical picture (upper left). Picture of the stent used in patch testing (upper right). Histopathological image (bottom) (hematoxylin–eosin, original magnification $\times 20$).

nickel. Patch testing of cobalt and chrome, the two other components of the stent according to manufacturer, were negative. Patch testing with nickel had to be removed after 24 h on patient request because of an extreme reaction (+++). Patch tests were performed and read according to the International Contact Dermatitis Research Group criteria.

It has been suggested that hypersensitivity reactions may play a role in restenosis after a cardiovascular stenting procedure, cerebral lesions following cerebral clipping, localized eczema after orthopedic or dental implants,¹⁻³ as well as in systemic effects due to corrosion-induced release of the stent content in the body.^{4,5} However definite evidence is lacking. Interestingly, the blood levels of nickel were increased after implantation (not measured before implantation) and decreased progressively from a maximum value of 22.3 nmol/L 2 months post-implantation to 16.5, 12.8 and 11.1 nmol/L at 3, 7 and 9 months post-implantation, respectively (threshold, <10 nmol/L).

In summary, our patient presented unexplained recurrent symptomatic cerebral lesions following an intracerebral stenting procedure with a stent containing low levels of nickel. Investigation revealed that the patient had severe nickel allergy and a contact hypersensitivity most likely to the nickel contained in the stent used during the procedure. We conclude from this case that it seems reasonable to perform patch tests previous to intracerebral stenting procedures in case of suspected metal hypersensitivity.

ACKNOWLEDGMENTS: Each author participated sufficiently to take public responsibility for appropriate portions of the work and consented to the final, submitted version.

CONFLICT OF INTEREST: None declared.

Ana MARCOS-GONZALEZ,¹ David SPOERL,²
Basile DARBELLAY,³ Pierre PILETTA³

¹Department of Neuroradiology, ²Division of Clinical Immunology and Allergy, Department of Medical Specialties, and ³Department of Dermatology, University Hospital of Geneva, Geneva, Switzerland

REFERENCES

- 1 Schmidlin K, Verzwuyvelt J, Bernstein D, Kim H. Probable delayed-type hypersensitivity to nickel-containing cerebral aneurysm clip associated with neurologic deficits. *J Allergy Clin Immunol Pract* 2015; **3**: 609–611.
- 2 Koster R, Vieluf D, Kiehn M *et al*. Nickel and molybdenum contact allergies in patients with coronary in-stent restenosis. *Lancet* 2000; **356**: 1895–1897.
- 3 Ulus S, Yakupoğlu A, Kararslan E, Işlak C, Siva A, Koçer N. Reversible intracranial parenchymal changes in MRI after MCA aneurysm treatment with stent-assisted coiling technique; possible nickel allergy. *Neuroradiology* 2012; **54**: 897–899.
- 4 Halwani DO, Anderson PG, Lemons JE, Jordan WD, Anayiotos AS, Brott BC. In-vivo corrosion and local release of metallic ions from vascular stents into surrounding tissue. *J Invasive Cardiol* 2010; **22**: 528–535.
- 5 Schuh A, Lill C, Honle W, Effenberger H. Prevalence of allergic reactions to implant materials in total hip and knee arthroplasty. *Zentralbl Chir* 2008; **133**: 292–296.