

# Cerebral venous sinuses thrombosis in both transverse sinus and torcula: Multistep endovascular treatment and stenting

G Cabral de Andrade<sup>1,2</sup>, A Lesczynsky<sup>2</sup>, VM Clímaco<sup>1</sup>, ER Pereira<sup>1</sup>, PO Marcelino<sup>2</sup>, AOC Franco<sup>2</sup> and DF De Almeida<sup>2</sup>

## Abstract

**Purpose:** Cerebral venous sinus thrombosis (CVST) is an unusual and potentially life-threatening condition with variable and nonspecific clinical symptoms and high morbimortality rates. Standard therapy consists of systemic anticoagulation; although there is no clear evidence about the best choice for treatment, intravenous heparin is used as the first-line treatment modality. Intravenous sinus thrombolysis can be an effective and relatively safe treatment for acutely deteriorating patients who have not responded to conventional therapy. This case report presents the possibility of endovascular treatment in multiple steps with mechanical thrombolysis with balloon, local pharmacological thrombolysis and stenting, in a patient with a severe form of CVST.

**Case summary:** A 67-year-old woman presented severe headache, agitation and confusion with diagnosis of venous sinus dural thrombosis in both lateral sinus and torcula. After 24 h there was neurological worsening evolving with seizures and numbness even after starting heparin, without sinus recanalization; CT scan showed left temporal intracerebral hemorrhage. We decided to take an endovascular approach in multiple steps. The first step was mechanical static thrombolysis with balloon; the second step was dynamic mechanical thrombolysis with a balloon partially deflated and “pulled”; the third step was local thrombolysis with Actilyse<sup>TM</sup>; finally, the fourth step was angioplasty and reconstruction of the sinuses using multiple carotid stents and complete angiographic recanalization of both sinuses and torcula. After 24 h of endovascular treatment there was full clinical recovery and no tomographic complications.

**Conclusion:** This result shows that mechanical clot disruption, intrasinus thrombolysis and reconstruction of wall sinuses with stenting can be an endovascular option in the severe form of CVST with intracerebral hemorrhage and rapid worsening of neurological symptoms. Although this type of treatment can re-channel the occluded sinuses, further comparative and randomized studies are needed to clarify its efficacy versus other therapeutic modalities.

## Keywords

Cerebral sinus venous thrombosis (CVST), thrombectomy, thrombolysis, angioplasty, stent

Received 20 August 2016; revised: 24 September 2016; accepted 26 September 2016

Cerebral venous sinus thrombosis (CVST) more commonly affects young women, and is responsible for less than 1% of cerebrovascular accidents. Patients aged over 65 years with cerebral hemorrhage and associated CVST with severe clinical–neurological symptoms have a high mortality rate.<sup>1</sup> Systematic reviews reveal that the improvement in diagnostic methods, including venography by computed tomography (CT) and magnetic resonance imaging (MRI), has supported a better understanding of this pathology, managing to identify the most and least severe cases, as well as the increasing use of various endovascular therapy methods which can be applied in severe cases; in general, this has influenced a downward mortality rate.<sup>2,3</sup> Anticoagulation therapy using systemic heparin is the preferred

treatment, being the only treatment with a high level of evidence in randomized clinical trials.<sup>4–6</sup> The endovascular approach has been taken only in severe cases with considerable clinical worsening and without response to systemic heparin, and with progression to intracranial hemorrhage, mental status disorder, coma (Glasgow Coma Scale (GCS) < 9) or thrombosis of the deep

<sup>1</sup>CINN – Integrated Center of Neurology and Neurosurgery, Maringá, Brazil

<sup>2</sup>Parana Hospital, Maringá, Brazil

## Corresponding author:

GUILHERME Cabral de Andrade, CINN Neurologia e Neurocirurgia

Integradas R SANTOS DUMONT Nº 719 Maringá, PARANA 87050-100 Brazil.

Email: g.c.andrade@hotmail.com

cerebral venous system.<sup>4,7,8</sup> Some publications, mainly case reports or small clinical series, have been added to the literature; however, the most appropriate treatment remains undefined. More aggressive therapies may be required in selected cases. However, there are some reports attesting the efficacy of an endovascular approach with mechanical thrombectomy, aspiration thrombectomy and local thrombolysis in cases where recanalization after systemic anticoagulation has not occurred.<sup>9-13</sup>

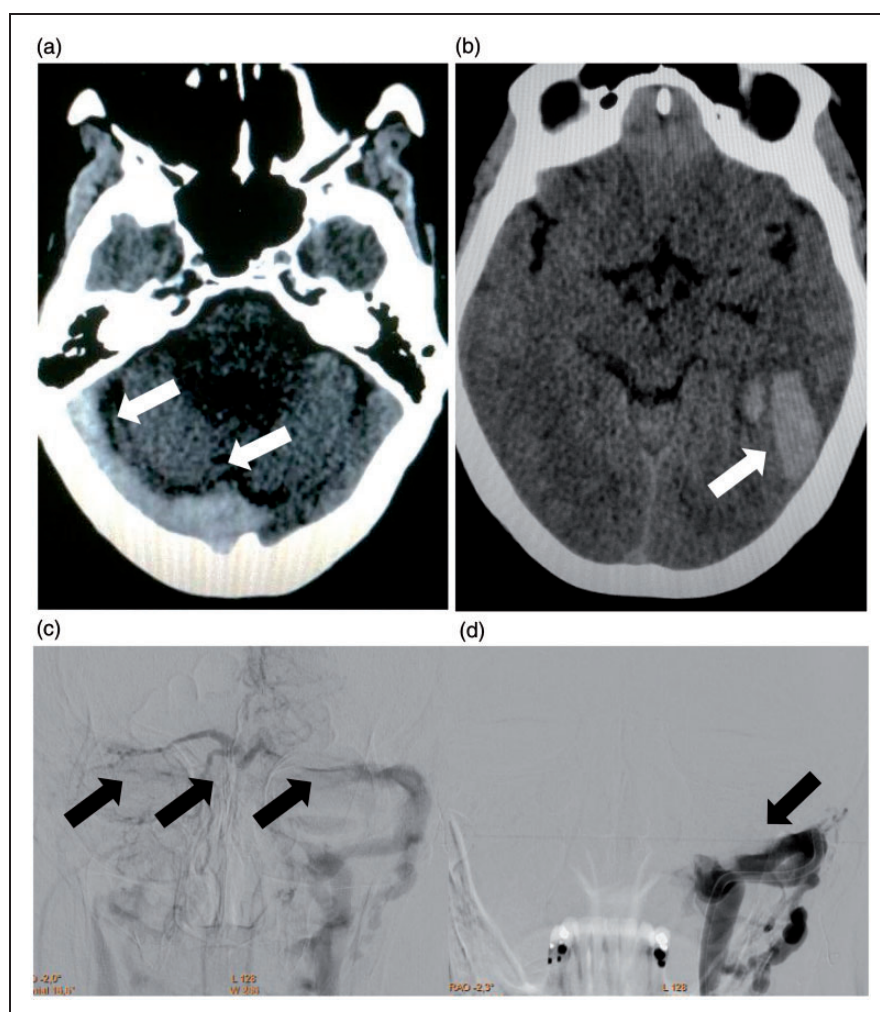
### Case report

We report a female patient, 67 years old, admitted to emergency care with severe headache and vomiting for 24 h, evolving into a confusional state within a few hours, with a consciousness level of 13 on the GCS. A CT scan showed hyperdensity in the topography of both lateral sinus and torcula and no other ischemic or hemorrhagic injuries in the brain parenchyma (Figure 1(a)). The family denied any infectious event, recent trauma or use of any medication. Blood

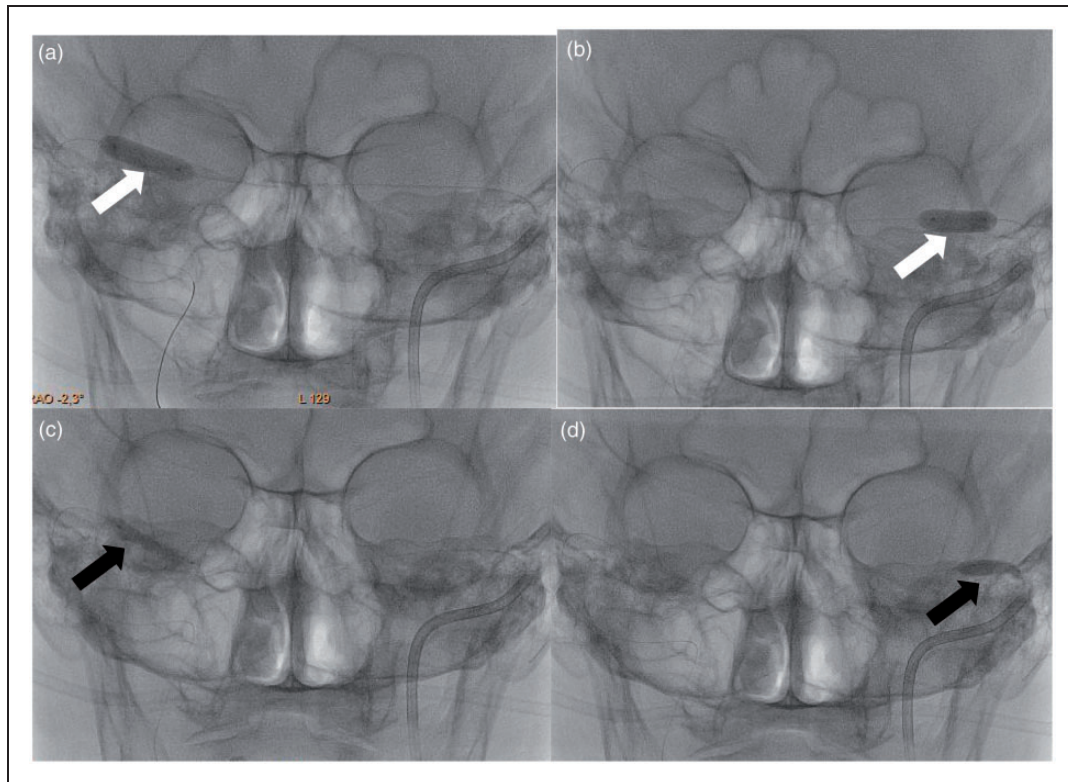
coagulation tests were normal. After the CT scan of CVST, systemic heparinization as a bolus (5000 IU) was started followed by continuous infusion (800 IU/h), with a target activated partial thromboplastin time (aPTT) of 60–90 s, with evaluation of the aPTT every 6 h. After 24 h, there was worsening neurology of the consciousness level, with GCS of 10 and seizures. Another CT scan was performed with the diagnosis of left temporal intracerebral hemorrhage without recanalization of dural sinuses (Figure 1(b)). Digital subtraction angiography (DSA) showed extensive venous sinus occlusion of both lateral sinus and torcula, in arterial and venous catheterization, respectively (Figure 1(c) and (d)); we considered this a severe form of CVST and decided to take an endovascular approach.

### Endovascular treatment

The patient was placed under general anesthesia. The femoral artery was punctured with the 5 F introducer, followed by catheterization of the left internal carotid artery with vertebral catheter 5 F for arterial



**Figure 1.** (a) CT scan admission with extensive clot involving both lateral sinus and torcula, white arrow; (b) CT scan after 24 h and systemic heparin and seizure, with left temporal intracerebral hemorrhage, white arrow; (c) and (d) Digital subtraction angiography, arterial and venous infusion respectively arterial and venous phase occlusion of both lateral sinuses and torcula, black arrows.



**Figure 2.** (a) and (b) Endovascular therapy with balloon and static mechanical thrombolysis in both lateral sinus and torcula, white arrows (first step); (c) and (d) Mechanical thrombolysis, but performed in a dynamic way with the balloon partially inflated, pulling it from one extreme to another of the occluded lateral sinus, black arrows (second step).

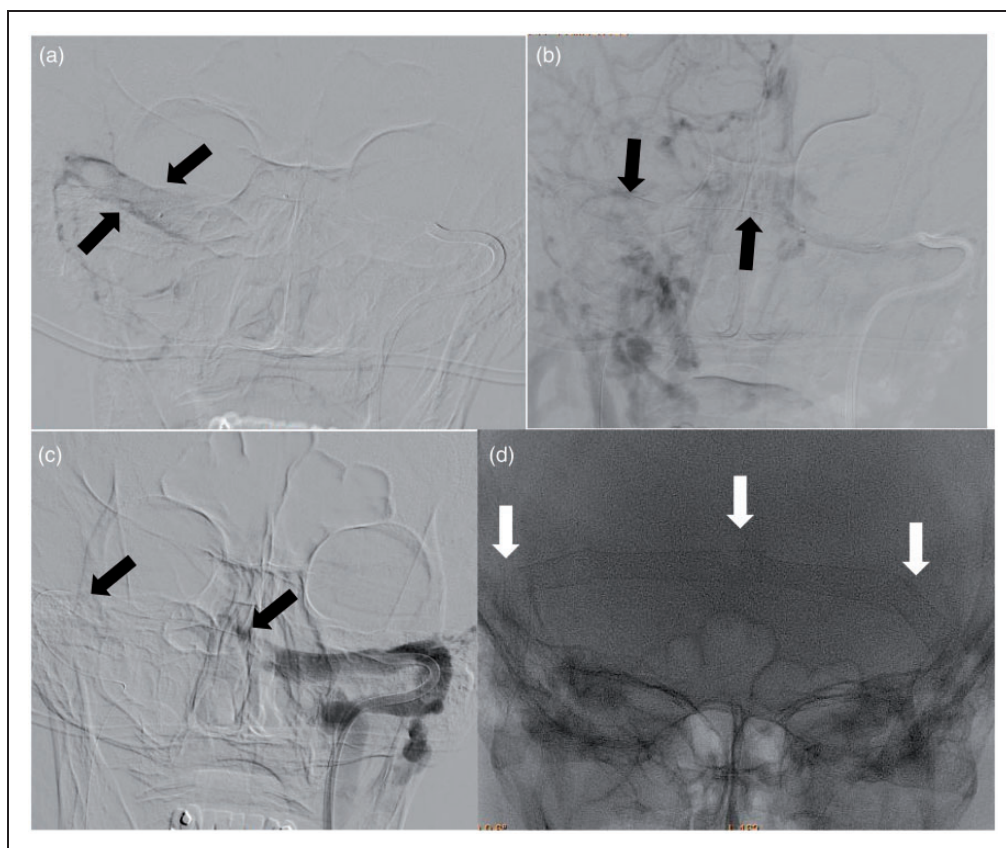
angiographic control. Left femoral venous puncture was done with the introducer 8 F, and catheterization of the left sigmoid sinus with a catheter guider 8 F (Boston Scientific, Massachusetts, USA). The endovascular procedure was performed following four steps. In the first step we performed mechanical thrombolysis with balloon angioplasty; after microcatheterization of the venous sinus, transfixing the whole clot with the Microcatheter Echelon 14 (COVIDIEN Ev3, Irvine, USA) and Microguide wire Traxcess 14 and Traxcess Docking Wire 14 (Microvention/Terumo, Tustin, USA), the angioplasty balloon Viatrac 6 × 20 mm (Abbott, Chicago, USA) was positioned in a coaxial position and inflated, performing static mechanical thrombolysis all over the extension of both lateral sinus and torcula (Figure 2(a) and (b)). The second step was also mechanical thrombolysis, but performed in dynamic way with the balloon partially inflated, pulling it from one extreme to another of the occluded lateral sinus multiple times in order to reach a further clot fragmentation (Figure 2(c) and (d)). The third step was local pharmacological thrombolysis with Alteplase (Boehringer Ingelheim, Ingelheim am Rhein, Germany) infused through the microcatheter at a total dose of 0.9 mg/kg and a final dose of 65 mg (Figure 3(a)). Angiographic controls were performed for 30 min without sinus recanalization (Figure 3(b) and (c)). Following this a fourth and final step was performed, which was angioplasty with multiple carotid

stents, with a total of six (06) from the right sigmoid sinus to the left transverse sinus, using the carotid Stent Xact 7 × 30 mm (Abbott, Chicago, USA) (Figure 3(d)) with final angiographic control showing a complete recanalization all over the venous dural system (Figure 4(a)); a CT scan after 24 h showed the maintenance of venous sinus permeability without bleeding or cerebral ischemia (Figure 4(b)). The patient was discharged on the fifth day after the endovascular treatment, with a consciousness recovery level of GSC 15 and without any neurological deficit. The use of the anticoagulant Rivaroxabana 10 mg (Bayer, Leverkusen, Germany) was maintained for 6 months, despite negative results for thrombophilia (Factor V Leiden, antiphospholipid antibody syndrome, antithrombin deficiency, protein C and S deficiency, possibly homozygous prothrombin 20210 mutation), and antiplatelet clopidogrel (75 mg/day) and aspirin (200 mg/day) were continued for 1 year. In the follow-up period the patient reported an occipital trauma by a simple fall, about 20 days before the thrombotic event. Cerebral angiography follow-up at 11 months showed no sinus reocclusion and normal venous dural system permeability (Figure 4(c)).

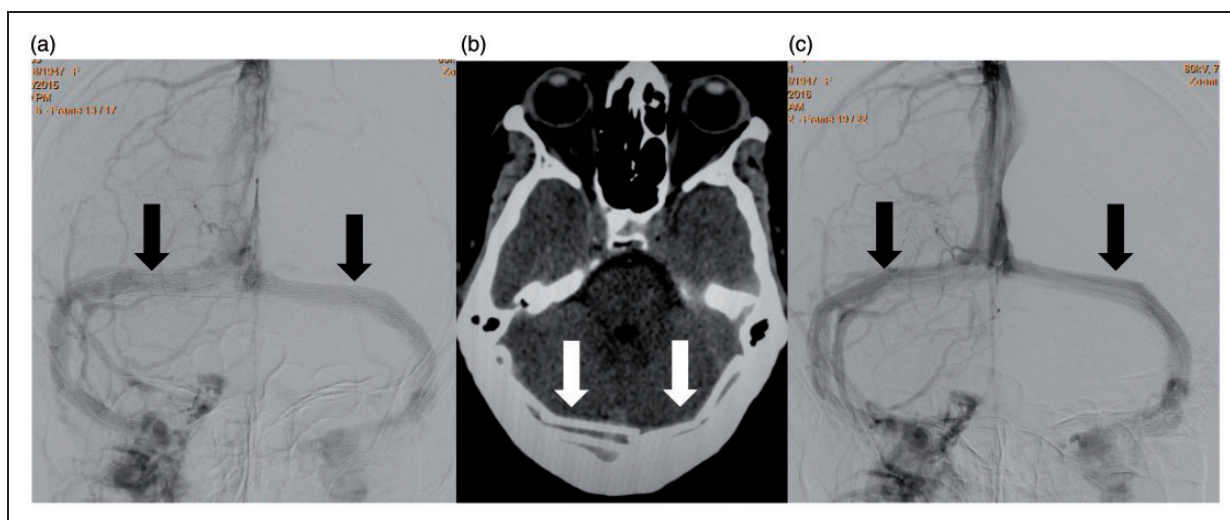
## Discussion

The American Heart Association guideline recommends anticoagulant therapy in the acute phase of





**Figure 3.** (a) Micro catheterization and thrombolysis with Alteplase, black arrows (third step); Arterial and venous angiography control (b) and (c), respectively, after mechanical and chemical thrombolysis without recanalization of right lateral sinus and torcula, black arrows; (d) Angioplasty with multiple carotid stents between right sigmoid and left transverse sinus, white arrows (fourth step).



**Figure 4.** (a) Digital subtraction angiography, arterial phase the end of endovascular treatment with complete recanalization of both sides and torcula, black arrows. (b) CT scan 24 h after endovascular recanalization keeping the venous system, white arrows and (c) Follow-up angiography at 11 months, with complete recanalization in 100% of all the dural venous system, black arrows.

cerebral vein thrombosis, even in the presence of intracranial hemorrhage.<sup>7</sup>

A systematic review of patients with CVST showed a tendency of decreasing mortality, from 40–50% in 1960

to 0–28% after 2000, probably as a result of better support with new diagnostic methods (venography by CT and MRI) and treatment of these injuries.<sup>2</sup> According to the International Study on Cerebral

Vein and Dural Sinus Thrombosis (ISCVT), the largest prospective cohort study of 624 patients, 21% had a poor outcome (death 8%).<sup>14</sup>

Venous sinus dural anatomy must be considered in the understanding and treatment of this pathology. Anatomical studies of the dural sinus in corpses reveal a high incidence of trabeculations, sinus intra septa, also described as fibrous bands, in 29.4% of the specimens, with potential to alter the venous sinus flow.<sup>15,16</sup>

Another important aspect to be considered in cerebral venous thrombosis is the presence of an inflammatory process involving monocytes, neutrophils and platelets in clot propagation and consequent obstruction of the venous flow; this may also influence clot characteristics, leaving it with a greater consistency and better grip.<sup>17</sup>

Endovascular treatment for CVST with mechanical thrombolysis and angioplasty balloon, even with no high-level evidence, has been reported as an adjuvant therapy of systemic anticoagulation in the severe form with risk factors: intracerebral hemorrhagic lesion, mental status disorder, coma (GCS < 9) or thrombosis of the deep cerebral venous system.<sup>8,18,19</sup> A recent systematic review assessed 185 patients who underwent mechanical thrombectomy, noting that in severe cases venous anticoagulation may not be the treatment of choice, with indication for intrathrombolysis and/or mechanical thrombolysis.<sup>20</sup>

The use of venous stents in venous occlusion treatment, described initially in a traumatic thrombosis case of both internal jugular veins, resulted in a significant reduction of the intracranial hypertension after recanalization with stents.<sup>21</sup>

The first report about the use of stents in the intracranial venous sinus system was a procedure performed following mechanical thrombolysis treatment and the use of angioplasty balloon, after clinical worsening in a dural arteriovenous fistula (FAVD) associated with occipital sinus thrombosis.<sup>22</sup> There are other reported cases of superior sagittal sinus thrombosis, without recanalization after systemic anticoagulation, followed by mechanical thrombectomy with balloon and thrombolysis. The use of stents can be considered as a viable treatment option in the case of failure of endovascular treatment for the severe form of CVST.<sup>23,24</sup>

Multicentric experience of endovascular treatment of CVST with intracranial hypertension, in cases where there is no good result with systemic thrombolysis, shows the use of multiple clot rescue systems such as Stents Retrievers, Solitaire FR (Covidien, Irvine, California, USA) and Trevo (Stryker, Kalamazoo, Michigan, USA), as well as catheters developed for thrombus suction in cerebrovascular accident, such as the Penumbra catheter (Penumbra Inc., Alameda, California, USA) with manual aspiration or Penumbra pump. A complete restoration of blood flow was observed in 38% of cases, but there was also a high mortality rate of 27%, indicating an

improvement in the strategies of dural sinus recanalization in severe cases. A multi-center randomized clinical trial is currently running, comparing anticoagulation with endovascular treatment with mechanical thrombolysis and aspiration to define the effectiveness of this treatment.<sup>8</sup>

In a related case, after 24 h of ineffective systemic heparinization the option of an endovascular intervention was taken after evolution to severe form. The endovascular approach has most commonly used mechanical thrombolysis with balloon (first step), mechanical thrombolysis with balloon partially inflated, pulling it and fragmenting the clot (second step) and local pharmacological thrombolysis (third step). We made every effort to obtain recanalization with these methods; despite the failure of these procedures, we opted for multiple carotid stents (fourth step). We initially placed a stent at the distal end of the thrombus and, after ensuring that recanalization had been obtained, placed additional stents until recanalization was confirmed.

Although the use of stents as a complementary technique in the endovascular treatment for the severe form of CVST is debatable, the recanalization of both lateral sinus and torcula was effective in this case, with good recovery, and maintenance of long-term permeability; patients must be submitted to an initial treatment through systemic heparin anticoagulation, being the endovascular approach already used in severe forms. We do not recommend routine use of this off-label technique. However, it may be an option for treatment in cases where there is failure of systematic treatments. Controlled studies are required to provide an answer on the efficacy of using stents in such cases.

#### Declaration of conflicting interests

The authors declared no potential conflicts of interest with respect to the research, authorship, and/or publication of this article.

#### Funding

The authors received no financial support for the research, authorship, and/or publication of this article.

#### References

1. Canhao P, Ferro JM, Lindgren AG, et al. Causes and predictors of death in cerebral venous thrombosis. *Stroke* 2005; 36: 1720–1725.
2. Coutinho JM, Zuurbier SM and Stam J. Declining mortality in cerebral venous thrombosis: A systematic review. *Stroke* 2014; 45: 1338–1341.
3. Medel R, Monteith SJ, Crowley RW, et al. A review of therapeutic strategies for the management of cerebral venous sinus thrombosis. *Neurosurg Focus* 2009; 27(5): E6.
4. Einhaupl KM, Villringer A, Meister W, et al. Heparin treatment in sinus venous thrombosis. *Lancet* 1991; 338: 597–600.

5. Coutinho J, de Bruijn SF, Deveber G, et al. Anticoagulation for cerebral venous sinus thrombosis. *Cochrane Database Syst Rev* 2011; 8: 1–21.
6. De Bruijn SFTM and Stam J. Randomized, placebo-controlled trial of anticoagulant treatment with low-molecular-weight heparin for cerebral sinus thrombosis. *Stroke* 1999; 30: 484–488.
7. Saposnik G, Barinagarrementeria F, Brown Jr, RD, et al. Diagnosis and management of cerebral venous thrombosis: A statement for healthcare professionals from the American Heart Association/American Stroke Association. *Stroke* 2011; 42: 1158–1192.
8. Coutinho JM, Ferro JM, Zuurbier SM, et al. Thrombolysis or anticoagulation for cerebral venous thrombosis: Rationale and design of the TO-ACT trial. *Int J Stroke* 2013; 8(2): 135–140.
9. Gala NB, Agarwal N, Barrese J, et al. Current endovascular treatment options of dural venous sinus thrombosis: A review of the literature. *J Neurointerv Surg* 2013; 5: 28–34.
10. Mokin M, Lopes DK, Binning MJ, et al. Endovascular treatment of cerebral venous thrombosis: Contemporary multicenter experience. *Interv Neuroradiol* 2015; 21(4): 520–526.
11. Borhani Haghighi A, Mahmoodi M, Edgell RC, et al. Mechanical thrombectomy for cerebral venous sinus thrombosis: A comprehensive literature review. *Clin Appl Thromb Hemost* 2014; 20: 507–515.
12. Jankowitz BT, Bodily LM, Jumaa M, et al. Manual aspiration thrombectomy for cerebral venous sinus thrombosis. *J Neurointerv Surg* 2013; 5: 534–538.
13. Wasay M, Bakshi R, Kojan S, et al. Nonrandomized comparison of local urokinase thrombolysis versus systemic heparin anticoagulation for superior sagittal sinus thrombosis. *Stroke* 2001; 32: 2310–2317.
14. Ferro JM, Canhao P, Stam J, Boussier MG and Barinagarrementeria F. Prognosis of cerebral vein and dural sinus thrombosis: Results of the International Study on Cerebral Vein and Dural Sinus Thrombosis (ISCVT). *Stroke* 2004; 35: 664–670.
15. Strydom MA, Briers N, Bosman MC, et al. The anatomical basis of venographic filling defects of the transverse sinus. *Clin Anat* 2010; 23: 153–159.
16. Subramaniam RM, Tress BM, King JO, et al. Transverse sinus septum: A new aetiology of idiopathic intracranial hypertension? *Australas Radiol* 2004; 48: 114–116.
17. Von Brühl ML, Stark K, Steinhart A, et al. Monocytes, neutrophils, and platelets cooperate to initiate and propagate venous thrombosis in mice in vivo. *JEM* 2012; 209(4): 819–835.
18. Stam J, Majoie CB, van Delden OM, et al. Endovascular thrombectomy and thrombolysis for severe cerebral sinus thrombosis: A prospective study. *Stroke* 2008; 39: 1487–1490.
19. Chaloupka JC, Mangla S and Huddle DC. Use of mechanical thrombolysis via microballoon percutaneous transluminal angioplasty for the treatment of acute dural sinus thrombosis: Case presentation and technical report. *Neurosurgery* 1999; 45: 650–656.
20. Siddiqui FM, Dandapat S, Banerjee C, et al. Mechanical thrombectomy in cerebral venous thrombosis. Systematic review of 185 cases. *Stroke* 2015; 46: 1263–1268.
21. Duke BJ, Ryu RK, Brega KE, et al. Traumatic bilateral jugular vein thrombosis: Case report and review of the literature. *Neurosurgery* 1997; 41: 680–683.
22. Malek AM, Higashida RT, Balousek PA, et al. Endovascular recanalization with balloon angioplasty and stenting of an occluded occipital sinus for treatment of intracranial venous hypertension: Technical case report. *Neurosurgery* 1999; 44: 896–901.
23. Adachi H, Mineharu Y, Ishikawa T, et al. Stenting for acute cerebral venous sinus thrombosis in the superior sagittal sinus. *Interv Neuroradiol* 2015; 1(6): 719–723.
24. Matsumoto N, Kuramoto Y, Shinoda N, et al. A case of stenting for acute cerebral venous sinus thrombosis in the superior sagittal sinus. *Interv Neuroradiol* 2016; August 17 (online).