

Cessation of Smoking and Alcohol Addiction Following Thalamic Hemorrhage

Fatima Najeeb, MD, Brian Silver, MD,* and Muhib Khan, MD*†*

Introduction: We describe a case of thalamic intracerebral hemorrhage leading to cessation of smoking.

Case Report: A 53-year-old female presented to the emergency department with right-sided weakness and dysarthria. Initial systolic blood pressure was 220 mm Hg. Computed tomography scan showed a left thalamic hemorrhage with associated edema and hemorrhage extending into the left lateral and third ventricle. She recovered uneventfully and was discharged to inpatient rehabilitation and eventually transitioned home. Three months later in the clinic, she reported that following the stroke, she abruptly stopped smoking without any smoking cessation aid. She reported that she had no craving for cigarettes. She also developed an aversion to drinking alcohol.

Discussion: Cessation of smoking following a thalamic intracerebral hemorrhage is not reported earlier. This observation suggests that the thalamus may play a role in nicotine and alcohol addiction. Further studies are needed to elucidate the possible involvement of the thalamic circuits in addiction pathways and as a potential target for modulation.

Key Words: nicotine addiction, thalamus, intracerebral hemorrhage
(*The Neurologist* 2016;21:91–92)

Smoking cessation reduces the risk of stroke; after 5 years, the risk of having a stroke is equal to that of a nonsmoker.¹ Many factors play a role in smoking cessation following stroke including stroke location, intention to stop smoking before stroke,² living in a rehabilitation after stroke, and receiving smoking cessation education.³ Abrupt smoking cessation has been described in patients with stroke in the insular cortex. We present a patient who abruptly stopped smoking and consuming alcohol following a left thalamic hemorrhage.

CASE REPORT

A 53-year-old female with a prior history of hypertension, hypothyroidism, and transient ischemic attack presented to the emergency department with right-sided weakness and dysarthria. On physical examination, she was alert and oriented to time, place, and person but was unable to tell her correct age and month; she had right facial droop and arm weakness, and impaired sensation to pinprick. Initial systolic blood pressure was 220 mm Hg. Computed tomography scan showed a left thalamic hemorrhage with associated edema and

hemorrhage extending into the left lateral and third ventricle (Fig. 1). Magnetic resonance imaging confirmed a left thalamic hemorrhage with associated edema (Fig. 2). She recovered uneventfully and was discharged to inpatient rehabilitation and eventually transitioned to home. Three months later, she had residual right-leg weakness with no significant difficulty in walking. Before the stroke, she was a 30 pack-year smoker and suffered from alcoholism. Following the stroke, she abruptly stopped smoking without any smoking cessation aid. She reported that she had no craving for cigarettes. She also developed an aversion to drinking alcohol, which was replaced by a preference for sweets, particularly apples, which she did not have before the stroke. A repeat magnetic resonance imaging of the brain showed encephalomalacia in the left thalamus (Fig. 3).

DISCUSSION

Strokes in the insular cortex have been reported in association with abrupt smoking cessation, without any urge to smoke again.⁴ Clinical syndromes related to thalamic infarcts and hemorrhages have been extensively studied.^{5,6} The clinical features of thalamic syndromes involve multiple faculties.^{5,6} Motor weakness with hemiparesis, dysarthria, apraxia and sensory deficits of hemianesthesia, hemineglect, and hemianopia have been observed.^{5,6} Language issues of semantic paraphasias, impaired comprehension, and acalculia have been reported.^{5,6} Thalamic injury also leads to impaired consciousness, anterograde amnesia, and apraxia.^{5,6} Personality changes ranging from apathy, abulia, executive dysfunction, alteration of social skills, aggression, and agitation are caused by thalamic infarcts and hemorrhages.^{5,6} Movement disorders such as dystonia and hand tremor have been reported as well. However, strokes exclusively in the thalamus have not been reported with this phenomenon.

Our patient had a hemorrhage in the thalamus, which was followed by abrupt smoking cessation and an aversion to alcohol. This observation suggests that the thalamus may play a role in nicotine and alcohol addiction.

Central control centers for smoking and alcohol addiction are uncertain. Nicotine binds to receptors in the ventral tegmental area, which causes stimulation of nucleus accumbens and an eventual release of dopamine, causing a feeling of satisfaction from smoking. Over time, conditioning occurs and a positive subjective feeling occurs while opening a pack even before any smoke is inhaled.⁷

Animal studies have shown that specific neurons in the medial basal forebrain encode reward uncertainty, expected reward value, anticipation of punishment, and unexpected reward and punishment.⁸ These studies highlight the importance of basal forebrain in memory processing pertaining to addiction.^{8,9}

Orexin/hypocretin is a neuropeptide expressed exclusively in neurons of dorsal tuberal hypothalamic nuclei.¹⁰ The orexin/hypocretin neurons influence multiple neuronal circuits and are especially dense in cerebral cortex, hippocampus, amygdala, basal forebrain, hypothalamus, and paraventricular nucleus of the thalamus.¹⁰ The system regulates the feeling of

From the *Department of Neurology, Warren Alpert Medical School of Brown University, Providence, RI; and †Neuroscience Institute (Division of Neurology), Spectrum Health, Michigan State University, Michigan State University, Grand Rapids, MI.

The authors declare no conflict of interest.

Reprints: Muhib Khan, MD, Neuroscience Institute (Division of Neurology), Spectrum Health, Michigan State University, 25 Michigan Ave NE Suite 6100, Grand Rapids, MI 49503. E-mail: muhibalamkhan@hotmail.com.

Copyright © 2016 Wolters Kluwer Health, Inc. All rights reserved.

ISSN: 1074-7931/16/2106-0091

DOI: 10.1097/NRL.0000000000000091

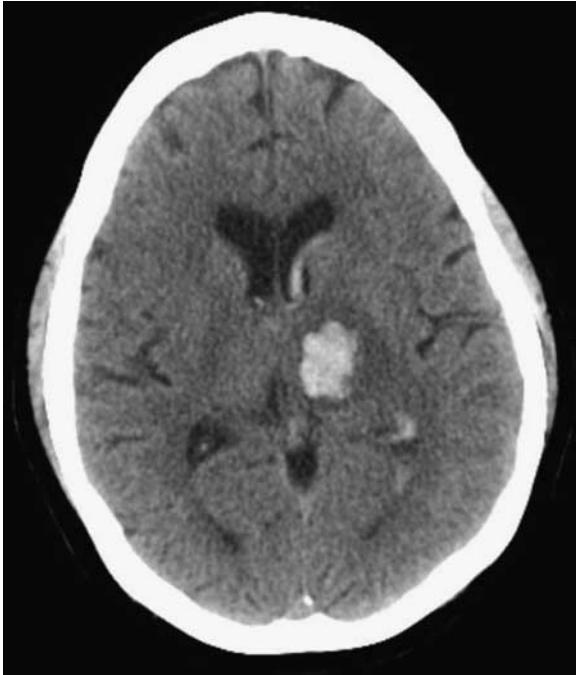


FIGURE 1. Initial head CT showing the left thalamic and intraventricular hemorrhage.

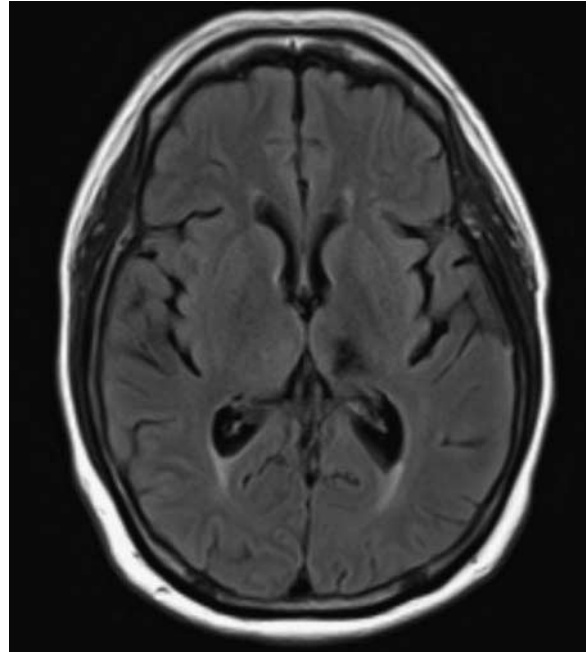


FIGURE 3. Three-month MRI showing the left thalamic encephalomalacia.

reward along with feeding, arousal and stress response, and sleep/wake states. Nucleus accumbens activity is affected by modulation of basal forebrain as shown in rats and this network is candidate for further investigation related to addiction.¹¹

Further studies are needed to elucidate the possible involvement of the thalamic circuits, especially interconnectivity

to basal forebrain and nucleus accumbens, in addiction pathways and as a potential target for modulation.

REFERENCES

1. Wolf PA, D’Agostino RB, Kannel WB, et al. Cigarette smoking as a risk factor for stroke. The Framingham Study. *JAMA*. 1988;259:1025–1029.
2. Suñer-Soler R, Grau A, Gras ME, et al. Smoking cessation 1 year poststroke and damage to the insular cortex. *Stroke*. 2012;43:131–136.
3. Sauerbeck LR, Khoury JC, Woo D, et al. Smoking cessation after stroke: education and its effect on behavior. *J Neurosci Nurs*. 2005;37:316–319.
4. Naqvi NH, Rudrauf D, Damasio H, et al. Damage to the insula disrupts addiction to cigarette smoking. *Science*. 2007;315:531–534.
5. Bogousslavsky J, Regli F, Uske A. Thalamic infarcts: clinical syndromes, etiology, and prognosis. *Neurology*. 1988;38:837–848.
6. Schmahmann JD. Vascular syndromes of the thalamus. *Stroke*. 2003;34:2264–2278.
7. Hunt WA. *Learning Mechanism in Smoking*. Chicago: Aldine; 1970.
8. Monosov IE, Leopold DA, Hikosaka O. Neurons in the primate medial basal forebrain signal combined information about reward uncertainty, value, and punishment anticipation. *J Neurosci*. 2015;35:7443–7459.
9. Monosov IE, Hikosaka O. Selective and graded coding of reward uncertainty by neurons in the primate anterodorsal septal region. *Nat Neurosci*. 2013;16:756–762.
10. Matzeu A, Zamora-Martinez ER, Martin-Fardon R. The paraventricular nucleus of the thalamus is recruited by both natural rewards and drugs of abuse: recent evidence of a pivotal role for orexin/hypocretin signaling in this thalamic nucleus in drug-seeking behavior. *Front Behav Neurosci*. 2014;8:117.
11. Sharma R, Dumontier S, DeRoode D, et al. Nicotine infusion in the wake-promoting basal forebrain enhances alcohol-induced activation of nucleus accumbens. *Alcohol Clin Exp Res*. 2014;38:2590–2596.

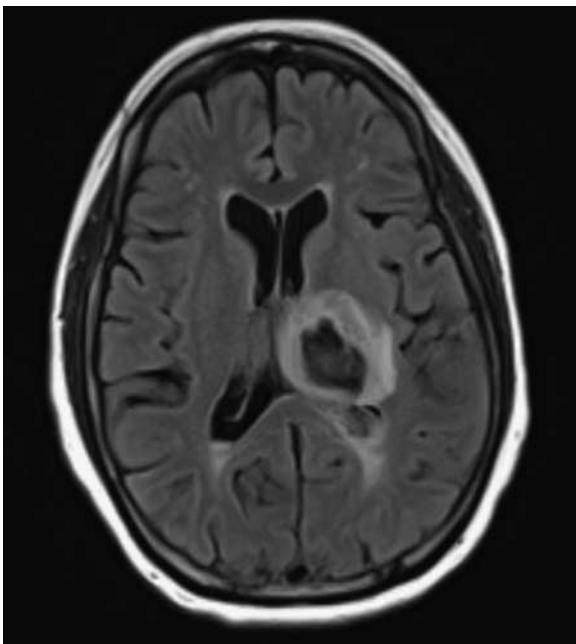


FIGURE 2. Initial MRI brain showing the left thalamic and intraventricular hemorrhage.