

Received: 2016.07.09
Accepted: 2016.08.24
Published: 2016.11.17

ISSN 1941-5923
© Am J Case Rep, 2016; 17: 860-863
DOI: 10.12659/AJCR.900498

Rapidly Sequential and Fatal Hemorrhaging in a Case of Cerebral Amyloid Angiopathy

Authors' Contribution:
Study Design A
Data Collection B
Statistical Analysis C
Data Interpretation D
Manuscript Preparation E
Literature Search F
Funds Collection G

ABCDEF 1 **Zachary B. Bulwa**
ABCDEF 2 **G. Carter Ward**
ABCDEF 3 **Owen N. Kramer**
ABCDEF 3 **Birju Rao**
ABCDEF 4 **Melvin Wichter**

1 Department of Internal Medicine, University of Chicago – NorthShore University Health System, Evanston, IL, U.S.A.
2 Department of Family Medicine, Medical College of Wisconsin, Milwaukee, WI, U.S.A.
3 Department of Neurology, University of Illinois at Chicago, Chicago, IL, U.S.A.
4 Department of Neurology, Advocate Christ Medical Center, Oak Lawn, IL, U.S.A.

Corresponding Author: Zachary B. Bulwa, e-mail: ZacharyBulwa@gmail.com
Conflict of interest: None declared

Patient: Female, 63
Final Diagnosis: Cerebral amyloid angiopathy
Symptoms: Altered mental state • aphasia • hemiplegia
Medication: —
Clinical Procedure: —
Specialty: Neurology

Objective: Unusual clinical course





Background: Cerebral amyloid angiopathy (CAA) is an increasingly recognized cause of lobar intracerebral hemorrhage (ICH) and cognitive impairment in the aging population. Magnetic resonance imaging (MRI) of cerebral microbleeds is the most reliable option for clinical diagnosis of suspected CAA. The pathophysiology of microbleeds and ICH in CAA is not well understood, but it is thought to be the result of vessel weakening and rupture secondary to amyloid deposition. Little evidence has been established pertaining to the time course of recurrent CAA-related microbleeds or larger hemorrhages. Although several risk factors have been associated with an increased risk of ICH in CAA, there are no current treatment guidelines for recurrent hemorrhaging in CAA.

Case Report: We present a rare case of rapidly sequential and fatal lobar hemorrhaging in the setting of suspected CAA, diagnosed by numerous microbleeds on MRI, compounded by the use of subcutaneous heparin in a 63-year-old female patient.

Conclusions: This case broadens our understanding of a rarely identified progression of CAA and illustrates the need for further investigation of the use of subcutaneous heparin in the setting of probable CAA.

MeSH Keywords: Cerebral Amyloid Angiopathy • Heparin • Intracranial Hemorrhages

Full-text PDF: <http://www.amjcaserep.com/abstract/index/idArt/900498>

 1263  —  1  24



Background

Cerebral amyloid angiopathy (CAA) is an increasingly recognized cause of lobar intracerebral hemorrhage (ICH) and cognitive impairment in the aging population [1]. CAA accounts for 15% of non-traumatic ICHs in the older population (greater than 60 years of age) [2]. Definitive diagnosis of CAA requires histopathological analysis, which is of minimal practical use. Thus, magnetic resonance imaging (MRI) is the most reliable option for clinical diagnosis of suspected CAA and can be prognostic for recurrent hemorrhaging [3,4].

CAA is a vasculopathy resulting from deposition of β -amyloid protein in the media and adventitia of small- and medium-sized arteries as well as capillaries in the leptomeninges and cerebral cortex [1,4]. CAA-related bleeds have a posterior predilection with most bleeds occurring in the occipital lobe [5]. The pathophysiology of microbleeds and ICH in CAA is not well understood, but it is thought to be the result of vessel weakening and rupture secondary to amyloid deposition [1].

Little evidence has been established pertaining to the time course of recurrent CAA-related microbleeds or larger hemorrhages. Although several risk factors have been associated with an increased risk of ICH in CAA, there are no current treatment guidelines specific to recurrent hemorrhaging in CAA [6].

Here we present a rare case of sequential and fatal lobar hemorrhaging in the setting of probable CAA in a 63-year-old female patient over a one-month period.

Case Report

A 63-year-old female with a history of multiple sclerosis, chronic right upper extremity weakness, heavy tobacco use, depression, migraines, hypertension, and dyslipidemia, who was taking 81 mg aspirin daily, was found unresponsive by her family.

The patient was emergently seen in a Chicago-area hospital where computed tomography (CT) of the head demonstrated left frontal lobe hemorrhage with intraventricular extension. The patient was admitted to the intensive care unit where she was hemodynamically stable, but exhibited worsening mental status. She was aphasic with right hemiplegia, and was unable to follow commands. A repeat CT head demonstrated a 0.8 cm midline shift, associated edema and mass effect, and acute intra-axial hematoma, measuring 7.5×4.2 cm axially, centered in the left frontal lobe with intraventricular extension and notable left subarachnoid hemorrhage (Figure 1A). Emergent craniotomy was performed without complication. An intraoperative diagnosis of arteriovenous malformation was made, which pathology defined as a cavernoma.

During the following days the patient exhibited improving mental status, however, she remained aphasic with right hemiplegia. One week later she was found to be more lethargic and a follow-up head CT demonstrated a new right frontal lobe hemorrhage (Figure 1B). A brain MRI demonstrated numerous microbleeds on susceptibility weighted imaging (SWI) suggestive of CAA (Figure 1D–1F).

After this acute event, the patient continued to regain strength bilaterally. Two weeks later the patient was started on subcutaneous heparin (5,000 units every eight hours) for deep venous thrombosis prophylaxis.

Three days later the patient was found to be more confused with increased drowsiness and left facial droop. A head CT demonstrated new right parietal cortical and subcortical hemorrhages. Simvastatin and subcutaneous heparin were immediately discontinued. Coagulation studies were within normal limits.

The next day the patient became more lethargic and a head CT revealed three new right frontal bleeds (the largest measuring 4.7 cm) with edema and midline shift (Figure 1C). A decision was made with the family to pursue comfort care only. The patient died three days later.

Discussion

Cerebral amyloid angiopathy (CAA) should be suspected in patients over the age of 55 years old with spontaneous lobar microbleeds or a larger hemorrhage in the setting of normotension [5]. Prognosis in a patient with CAA is correlated with the burden of microbleeds at initial presentation [3]. Several risk factors are associated with CAA-related bleeds including age, Alzheimer disease, apolipoprotein E ϵ 2 and ϵ 4 alleles, head trauma and, of controversy, medications including thrombolytics, anticoagulants, anti-platelets, and cholesterol-lowering statins [1,5–7].

When the diagnosis of CAA with microbleeds is probable, strict medical management is imperative [6]. Current treatment of symptomatic CAA-related microbleeds and hemorrhages follows the guidelines for the management of all spontaneous intracerebral hemorrhage [5,8]. Because the bleeding in CAA is often sporadic, effective prevention strategies are imperative [1].

The PROGRESS trial demonstrated that blood pressure-lowering treatment provides protection against all types of intracerebral hemorrhage including CAA-related hemorrhage (77% risk reduction), which may represent a practical therapeutic approach [9]. Our patient's blood pressure ranged from 172/90 mm Hg to 96/42 mm Hg and elevations were not correlated with ICH (Figure 2). The spatial pattern of the

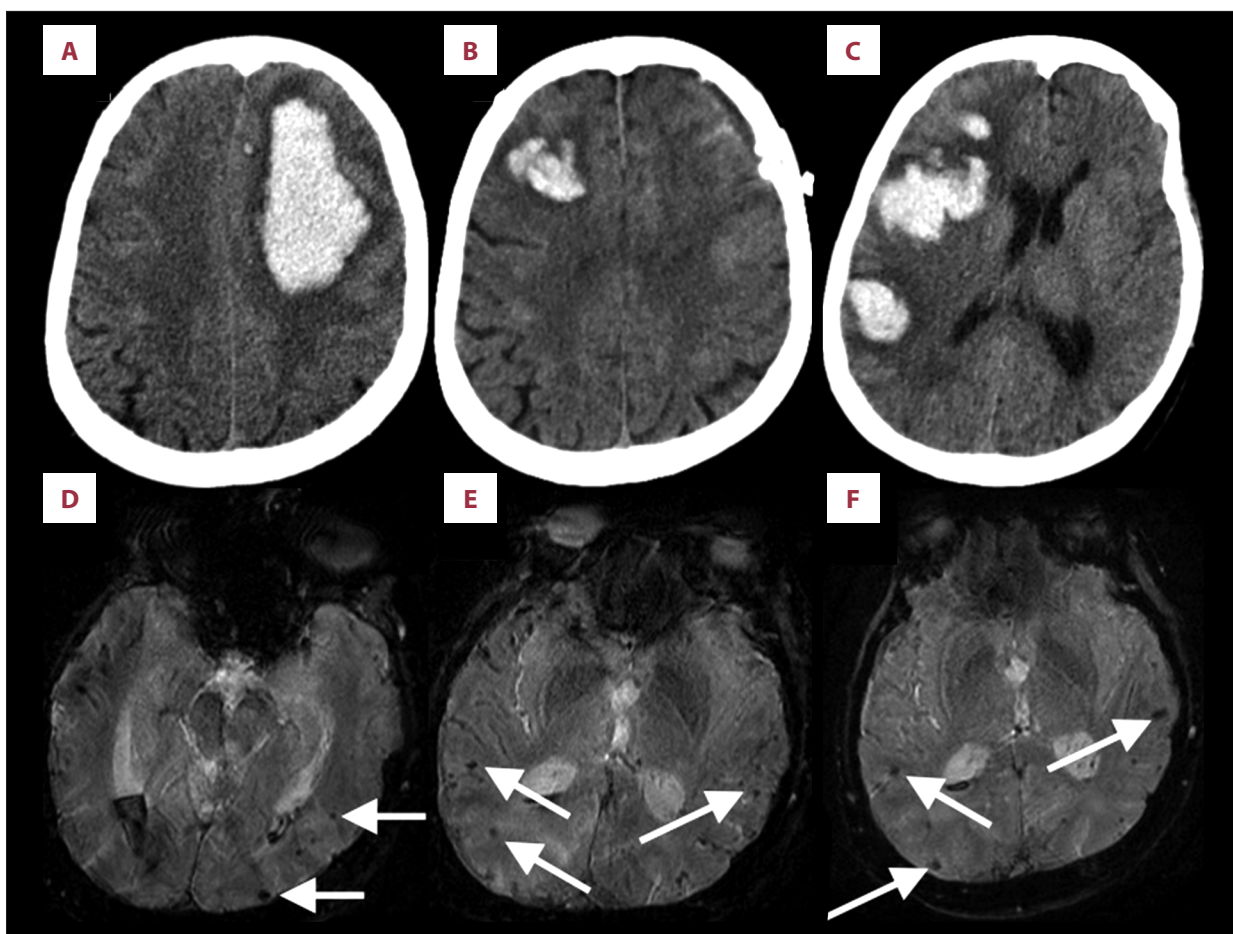


Figure 1. (A–C) CT head images. CT head scan on admission (A), one week later (B), and 25 days after admission (C). (D–F) Susceptibility weighted MR imaging, limited by motion artifact, demonstrates multiple strictly lobar microbleeds (white arrows) suggestive of cerebral amyloid angiopathy.

microbleeds was strictly posterior and lobar, inconsistent with the typical non-lobar, deep location of hypertensive intracerebral hemorrhages [10,11].

A pathologic diagnosis of cavernoma was made during the initial craniotomy, which may have marginally contributed to the initial hemorrhage. However, the size of the initial hemorrhage was magnitudes larger than the mean size of the hemorrhage (13.4 ± 7.3 mm) described by Jeon et al. [12] in 410 patients with cavernomas. The sequential hemorrhaging was also inconsistent with an etiology of cavernoma; and multiplicity of cavernomas has not been shown to be a risk for subsequent hemorrhage [13].

Additionally, the literature is replete with reports of medication-associated CAA-related bleeds, explicitly associated with thrombolytic, anticoagulant, antiplatelet, and statin therapy [2,7,9,14–21]. However, most controversially is the role of statin therapy in cerebral microbleeds and ICH. Reports have demonstrated that statin therapy can increase the risk of cerebral microbleeds [19,20], and Westover et al. [21] recommended

the avoidance of statins in patients with a history of ICH. Alternatively, a meta-analysis of 31 randomized controlled trials of statin therapy did not find an association between statin therapy and increased risk for ICH [22]. The exact contributory role of statin therapy in our case was unclear. It seemed clear that the rate of hemorrhaging was increased by concomitant use of subcutaneous heparin, but ongoing statin therapy may have been an additional risk factor.

According to the guidelines for the management of spontaneous intracerebral hemorrhages adopted by the American Heart Association and American Stroke Association [8]: “After documentation of cessation of bleeding, low dose subcutaneous low-molecular-weight heparin or unfractionated heparin may be considered for prevention of venous thromboembolism in patients with lack of mobility after 1 to 4 days from onset.” In our case, deep vein thrombosis prophylaxis with subcutaneous heparin (5,000 units every eight hours) was initiated after the first two hemorrhages had stabilized and the patient was clinically improving. Despite the cautious timeframe, three days

after initiation of subcutaneous heparin, multiple new hemorrhages developed resulting in fatal herniation.

The recurrence of hemorrhaging in this case was extremely rapid and fatal. In a large Japanese nationwide survey, the average interval between CAA-related lobar ICH was 11.3 months with recurrent hemorrhages in 31.7% of patients over the 35.3 month study period [23]. In a recent study, Biffi et al. reviewed 505 cases of recurrent lobar ICH and found zero recurrences within the first three months and only one recurrence within the first six months [24]. Greenberg et al. found recurrent lobar hemorrhages in 27 of 94 patients (28%) with a mean secondary hemorrhage at 20.8 ± 16.7 months [3]. While a timeline was not specifically indicated for tertiary bleeds and onward, our patient comparatively demonstrated an accelerated timeline of sequential hemorrhages.

References:

1. Viswanathan A, Greenberg SM: Cerebral amyloid angiopathy in the elderly. *Ann Neurol*, 2011; 70: 871–80
2. Sharma N, Vyas S: Cerebral amyloid angiopathy. *BMJ Case Rep*, 2014; 2014: pii: bcr2013201558
3. Greenberg SM, Eng JA, Ning M et al: Hemorrhage burden predicts recurrent intracerebral hemorrhage after lobar hemorrhage. *Stroke*, 2004; 35: 1415–20
4. Auriel E, Greenberg SM: The pathophysiology and clinical presentation of cerebral amyloid angiopathy. *Curr Atheroscler Rep*, 2012; 14: 343–50
5. Mehndiratta P, Manjila S, Ostergard T et al: Cerebral amyloid angiopathy-associated intracerebral hemorrhage: Pathology and management. *Neurosurg Focus*, 2012; 32: 7
6. Charidimou A, Nicoll JA, McCarron MO: Thrombolysis-related intracerebral hemorrhage and cerebral amyloid angiopathy: Accumulating evidence. *Front Neurol*, 2015; 6: 99
7. Yamada M: Cerebral amyloid angiopathy: Emerging concepts. *J Stroke*, 2015; 17: 17–30
8. Hemphill JC III, Greenberg SM, Anderson CS et al: Guidelines for the Management of Spontaneous Intracerebral Hemorrhage: A Guideline for Healthcare Professionals From the American Heart Association/American Stroke Association. *Stroke*, 2015; 46: 2032–60
9. Arima H, Tzourio C, Anderson C et al: Effects of perindopril-based lowering of blood pressure on intracerebral hemorrhage related to amyloid angiopathy: The PROGRESS trial. *Stroke*, 2010; 41: 394–96
10. Towfighi A, Greenberg SM, Rosand J: Treatment and prevention of primary intracerebral hemorrhage. *Semin Neurol*, 2005; 25: 445–52
11. Wu Y, Chen T: An up-to-date review on cerebral microbleeds. *J Stroke Cerebrovasc Dis*, 2016; 25: 1301–6
12. Jeon JS, Kim JE, Chung YS et al: A risk factor analysis of prospective symptomatic hemorrhage in adult patients with cerebral cavernous malformation. *J Neurol Neurosurg Psychiatry*, 2014; 85: 1366–70
13. Gross BA, Du R: Hemorrhage from cerebral cavernous malformations: A systematic pooled analysis. *J Neurosurg*, 2016 [Epub ahead of print]
14. Biffi A, Halpin A, Towfighi A et al: Aspirin and recurrent intracerebral hemorrhage in cerebral amyloid angiopathy. *Neurology*, 2010; 75: 693–98
15. Rosand J, Hylek EM, O'Donnell HC, Greenberg SM: Warfarin-associated hemorrhage and cerebral amyloid angiopathy: A genetic and pathologic study. *Neurology*, 2000; 55: 947–51
16. Vernooij MW, Haag MD, van der Lugt A et al: Use of antithrombotic drugs and the presence of cerebral microbleeds: The Rotterdam Scan Study. *Arch Neurol*, 2009; 66: 714–20
17. Charidimou A, Shakeshaft C, Werring DJ: Cerebral microbleeds on magnetic resonance imaging and anticoagulant-associated intracerebral hemorrhage risk. *Front Neurol*, 2012; 3: 133
18. Gregoire SM, Jäger HR, Yousry TA et al: Brain microbleeds as a potential risk factor for antiplatelet-related intracerebral haemorrhage: Hospital-based, case-control study. *J Neurol Neurosurg Psychiatry*, 2010; 81: 679–84
19. Romero JR, Preis SR, Beiser A et al: Risk factors, stroke prevention treatments, and prevalence of cerebral microbleeds in the Framingham heart study. *Stroke*, 2014; 45: 1492–94
20. Haussen DC, Henninger N, Kumar S, Selim M: Statin use and microbleeds in patients with spontaneous intracerebral hemorrhage. *Stroke*, 2012; 43: 2677–81
21. Westover MB, Bianchi MT, Eckman MH, Greenberg SM: Statin use following intracerebral hemorrhage: a decision analysis. *Arch Neurol*, 2011; 68: 573–79
22. McKinney JS, Kostis WJ: Statin therapy and the risk of intracerebral hemorrhage: A meta-analysis of 31 randomized controlled trials. *Stroke*, 2012; 43: 2149–56
23. Hirohata M, Yoshita M, Ishida C et al: Clinical features of non-hypertensive lobar intracerebral hemorrhage related to cerebral amyloid angiopathy. *Eur J Neurol*, 2010; 17: 823–29
24. Biffi A, Anderson CD, Battley TW et al: Association between blood pressure control and risk of recurrent intracerebral hemorrhage. *JAMA*, 2015; 314: 904–12

Conclusions

The combination of sequential hemorrhages compounded by the use of subcutaneous heparin broadens our understanding of the disease course and risk factors associated with CAA. What has been always thought of as a benign anticoagulant, subcutaneous heparin must now be examined, like other anticoagulants, as having the potential to increase the risk of hemorrhaging in patients with CAA.

Statement

There were no sources of funding for this report.