

## Case Studies

## A Case of Transient Global Amnesia with Small Left Putamen Infarction

Kosuke Yoshida, MD

A 67-year-old right-handed woman experienced a sudden anterograde and retrograde short-term memory deficit that recovered on the next day. Magnetic resonance imaging (MRI) showed a spotty high-intensity lesion in the left putamen in the diffusion-weighted and fluid-attenuated inversion recovery images. Transient global amnesia due to lacunar infarction of the left putamen was diagnosed. Transient global amnesia is characterized by a sudden onset of anterograde amnesia that disappears within 24 hours. The cause of transient global amnesia is still uncertain. Some studies with MRI showed small lesions in the hippocampus at 24-74 hours after the episode. These lesions disappear within several weeks. However, our case of transient global amnesia showed a small lesion in the left putamen, not the hippocampus. Some studies with functional MRI reported that the stratum plays an important role in short-term memory and cognitive function. This case showed only a left putamen lesion, which indicates that a putamen lesion can cause transient global amnesia. **Key Words:** Transient global amnesia—ischemic stroke—putamen—MRI.

© 2016 National Stroke Association. Published by Elsevier Inc. All rights reserved.

### Case Report

A 67-year-old right-handed woman experienced a sudden anterograde and retrograde short-term memory deficit during a party with her colleagues. The next day, she could not remember not only the details of the party but also the events before the party; therefore, she visited our neurology clinic. We could not detect any neurological deficit. Magnetic resonance imaging (MRI) showed a spotty high-intensity lesion in the left putamen in the diffusion-weighted and fluid-attenuated inversion recovery images (Fig 1). *N*-isopropyl [123I]-*p*-iodoamphetamine single photon

emission computed tomography did not show any focal decreasing cerebral blood flow (Fig 1). The patient did not have a migraine, and her electroencephalography was normal. Her transthoracic echocardiography showed no evidence of patent foramen ovale or any embolic sources. Holter electrocardiography showed only a few premature atrial contractions. In laboratory tests, fibrinogen and fibrin/fibrinogen degradation products showed normal results. In addition, the low-density lipoprotein cholesterol level was 149.0 mg/dL and hemoglobin A1c was 7.2% at admission. Transient global amnesia (TGA) due to lacunar infarction of the left putamen was diagnosed and treated with aspirin.

Fisher and Adams first described TGA as a clinical syndrome characterized by a sudden onset of anterograde amnesia occurring in the middle-aged or elderly population.<sup>1</sup> TGA disappears within 24 hours. Although some studies reported that TGA is associated with ischemic stroke, metabolism, emotional stress, and other factors, the cause of TGA is still uncertain. Some studies with MRI showed small lesions in the hippocampus at 24-74 hours after the episode. These lesions disappear

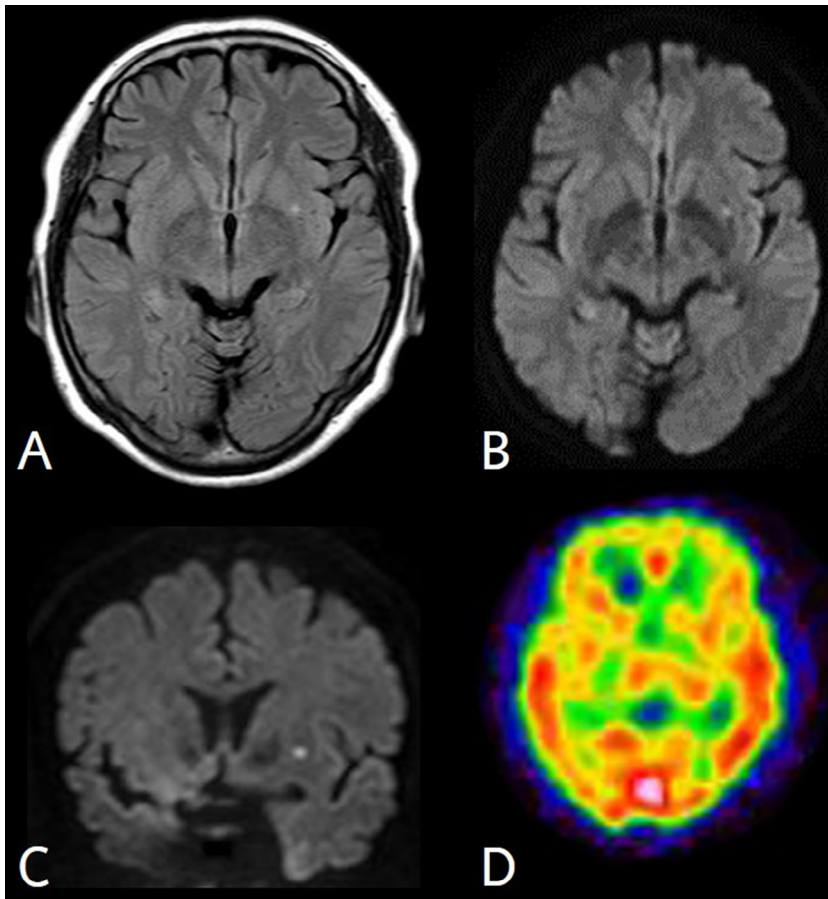
From the Department of Neurology, Asahikawa Medical Center, National Hospital Organization, Asahikawa, Hokkaido, Japan.

Received September 21, 2016; revision received October 13, 2016; accepted October 23, 2016.

Address correspondence to Kosuke Yoshida, MD, Department of Neurology, Asahikawa Medical Center, National Hospital Organization, Asahikawa, Hokkaido, Japan. E-mail: [yoshidak@asahikawa.hosp.go.jp](mailto:yoshidak@asahikawa.hosp.go.jp). 1052-3057/\$ - see front matter

© 2016 National Stroke Association. Published by Elsevier Inc. All rights reserved.

<http://dx.doi.org/10.1016/j.jstrokecerebrovasdis.2016.10.028>



**Figure 1.** Magnetic resonance and N-isopropyl [123I]-p-iodoamphetamine single photon emission computed tomography (IMP-SPECT) images taken on admission. A small lesion of the left putamen showing high-intensity signal in fluid-attenuated inversion recovery (A), and axial (B) and coronal (C) diffusion-weighted images. SPECT showed no evidence of any focal decreasing cerebral blood flow (D).

within several weeks. However, our case of TGA showed a small lesion in the left putamen, not the hippocampus.

Kim et al reported a similar case of TGA with a tiny putamen lesion.<sup>2</sup> The putamen projects from Brodmann's area 6, 4, and the intralaminar nucleus of the thalamus.<sup>3,4</sup> The win-shift task (explicit memory) is disturbed by hippocampal lesions, whereas the win-stay task (implicit memory) is disturbed by caudate lesions. The stratum has an important role in learning.<sup>5</sup> Functional MRI study in healthy right-handed adults reported that the left putamen and caudate have important roles in working memory task.<sup>6</sup> Recently, the putamen was found to be activated in cognitively impaired patients with Parkinson's disease.<sup>7</sup> These reports indicate that the putamen has an important role in short-term memory and cognitive function.

The putamen is supplied by a lenticular stratum artery, a branch of the middle cerebral artery. This is distinguished from strategic stroke caused by the posterior cerebral artery.

Our reported case showed only a left putamen lesion, which indicates that a putamen lesion can cause TGA. Further study is necessary to reveal the association of the putamen with short-term memory and cognitive

function. We conclude that a left putamen lesion can cause TGA.

## References

1. Fisher CM, Adams RD. Transient global amnesia. *Acta Neurol Scand Suppl* 1964;40(Suppl 9):1-83.
2. Kim H-J, Kim H, Lim SM, et al. An acute tiny left putamen lesion presenting with transient global amnesia. *Neurologist* 2012;18:80-82.
3. Alexander GE, DeLong MR, Strick PL. Parallel organization of functionally segregated circuits linking basal ganglia and cortex. *Annu Rev Neurosci* 1986;9:357-381.
4. Alexander GE, Crutcher MD, DeLong MR. Basal ganglia-thalamocortical circuits: parallel substrates for motor, oculomotor, "prefrontal" and "limbic" functions. *Prog Brain Res* 1990;85:119-146.
5. Packard MG, Hirsh R, White NM. Differential effects of fornix and caudate nucleus lesions on two radial maze tasks: evidence for multiple memory systems. *J Neurosci* 1989;9:1465-1472.
6. Chang C, Crottaz-Herbette S, Menon V. Temporal dynamics of basal ganglia response and connectivity during verbal working memory. *Neuroimage* 2007;34:1253-1269.
7. Poston KL, YorkWilliams S, Zhang K, et al. Compensatory neural mechanisms in cognitively unimpaired Parkinson disease. *Ann Neurol* 2016;79:448-463.