

Regional cerebral blood flow and metabolism in patients with transient global amnesia: a positron emission tomography study

KENICHIRO FUJII, SEIZO SADOSHIMA, TAKAO ISHITSUKA, KENJI KUSUDA, YASUO KUWABARA,* YUICHI ICHIYA,* MASATOSHI FUJISHIMA

*From the Second Department of Internal Medicine, and *Department of Radiology, Faculty of Medicine, Kyushu University, Fukuoka City, Japan*

SUMMARY In four patients who experienced transient global amnesia (TGA), clinical features and neuroadiological findings including positron emission tomography (PET) were studied within three months of the episodes, and compared with those in seven cases with cerebral transient ischaemic attacks (TIA). None of TGA patients had a previous history or significant risk factors for the cerebrovascular diseases. Their electroencephalogram, brain CT and angiogram for the head and neck were almost normal. PET study showed better preserved cerebral blood flow and oxygen metabolism in each area of the brain in patients with TGA compared with those with TIA in whom focal reductions of flow and metabolism were evident. These observations suggest that TGA is caused by reversible circulatory and/or metabolic disturbance, of which mechanism might be different from that in TIA.

Transient global amnesia (TGA) is known as a reversible neurological disorder characterised by sudden onset of retrograde amnesia and transient inability to obtain new memories.¹ The cause of TGA remains unclear and several underlying conditions, such as transient ischaemic attacks (TIA),²⁻⁷ epilepsy,^{8,9} migraine^{10,11} are reported to be possible candidates. Transient circulatory disturbance in the hippocampal-fornical-mamillary system or the thalamus is suggested to play an important role in the development of TGA.^{2,4-6} Recently, intensive studies of cerebrovascular diseases have focused on the impairment of regional cerebral circulation and metabolism using positron emission tomography (PET).¹² In the present study, four cases of TGA were analysed by PET and their findings were compared with patients with TIA. The pathogenesis of TGA is discussed.

Subjects and methods

Four cases with TGA admitted consecutively to our clinic between October, 1985 and June, 1987 were examined. All of the patients with TGA satisfied the criteria proposed by Kushner.⁷ Physiological and neurological examinations were performed in our clinic within three months of the last episodes of TGA. Laboratory and neuroradiological examinations including electrocardiography (ECG), serum chemistry, electroencephalography (EEG), brain computed tomography (CT) (TCT 60A, Toshiba Inc., Tokyo, Japan; spatial resolution 0.8 mm) conventional or digital subtraction angiography (DSA) (Angiotron, Siemens Inc., Erlangen, West Germany) for the head and neck, and PET were carried out in all patients. These findings were compared with those in seven patients with TIA who were admitted to our clinic during the same period. The diagnosis of TIA was made based on the criteria suggested by the US Joint Committee,¹³ and neurophysiological studies were also performed between one and three months after the last neurological symptoms.

PET study

The patients were placed in supine, with eyes open and ears unplugged in a dimly lit PET scanning room. One femoral artery was cannulated for sampling blood for the measurement of radio-activity in the blood and for blood gas analysis. Regional cerebral blood flow (rCBF), oxygen extraction fraction (rOEF) and cerebral metabolic rate of

Address for reprint requests: Kenichiro Fujii, M.D., The Second Department of Internal Medicine, Faculty of Medicine, Kyushu University, Maidashi 3-1-1, Higashi-ku, Fukuoka City, 812 Japan.

Received 23 September 1988 and in revised form 12 December 1988.
Accepted 19 December 1988

oxygen (rCMRO₂) were measured on the same day by H₂¹⁵O continuous infusion through ante-cubital vein and by ¹⁵O₂ continuous inhalation according to the oxygen-15 steady state technique, described by Frackowiak *et al.*¹² rOEF and rCMRO₂ were corrected with regional cerebral blood volume (rCBV) measured by single inhalation of C¹⁵O gas.¹⁴ HEADTOME-III (Shimazu Inc., Kyoto, Japan and Akita Noken, Akita, Japan) with a spatial resolution of 8.2 mm full width at half maximum (FWHM) was used. Correction for attenuation was carried out by means of a transmission scan using an external ⁶⁸Ge-⁶⁸Ga ring source in each patient.

Ten slices were scanned in each brain; parallel to the orbitomeatal (OM) line and then at 20, 27, 35, 42, 50, 57, 65, 72, 80 and 87 mm above OM line. Regions of interest (ROIs), 18 × 14 mm, were set to be the bilateral cerebral cortical areas (frontal, temporal, parietal and occipital cortices and hippocampus) white matter (centrum semiovale), deep gray matter (striatum and thalamus), bilateral cortices of the cerebellum, and the brainstem as shown in fig 1. In addition, all values in each parameter in the cortical ROIs were averaged and those values were compared between the two groups. Informed consent was obtained from all the patients before the PET study.

Data analysis

The average values for CBF, OEF, CMRO₂, and CBV in each ROI in patients with TGA were compared with those in patients with TIA by Student's small sample *t* test, or with unequal variance, Welch's *t* test. Blood pressure, serum chemistry and arterial blood gases were also compared between the two groups.

Case report

Case 1. A 61 year old female had a past history of hyperthyroidism, and was euthyroid after the age of 60. On 6 July, 1985, she practiced swimming from 12.00 am to 2.00 pm, and no unusual movement nor attitude was noticed by her swimming instructor. Around 2.30 pm, after putting on her clothes she was found looking for something anxiously. She was unable to recall anything from 12.00 am to 2.30 pm in the swimming school. She vaguely remembered that she dropped in and talked with her friend before going to

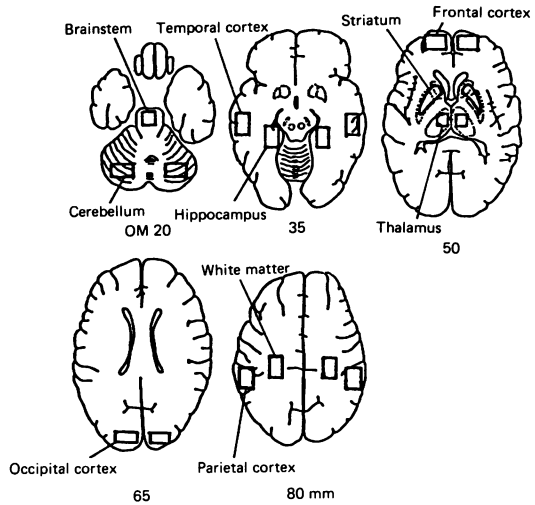


Fig 1 Location of regions of interest (ROIs). ROIs were placed symmetrically on each hemisphere. In the brainstem the ROI was placed on the midline. Numbers in the bottom indicate the distance from the orbitomeatal (OM) line to the plane.

the swimming school. She said that she looked for something for wearing but she could not indicate what she looked for. She recovered gradually and was in her usual state at 5.00 pm. On the next day she consulted a physician who found no neurological brain CT or EEG abnormalities. On 27 November, she was admitted to our hospital for the further examination. Her family history was not significant. She had smoked 10 cigarettes/day for 30 years. Blood pressure on admission was 112/74 mm Hg. Clinical examination did not reveal heart disease, diabetes mellitus nor hyperlipidaemia. Her brain CT demonstrated no abnormal findings except for bilateral calcified lesions in the striatum. EEG, intravenous (IV)-DSA of the head and neck and cerebral blood flow PET images (fig 2) were all within normal range.

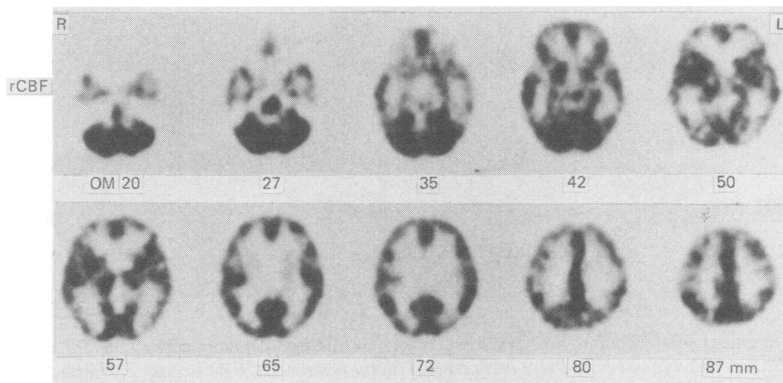


Fig 2 Regional cerebral blood flow (rCBF) in case 1. Numbers in the bottom indicate the distance from the orbitomeatal (OM) line to the plane. No abnormalities are observed.

Case 2. A 59 year old female had suffered from occipital non-throbbing frontal headache for five years. She was hypertensive at the age of 56 and had antihypertensive drugs for a month, being normotensive thereafter. On 30 September 1985, she visited her friend at 11.30 am, where she mentioned the same subject over and over and repeated the same questions. However, her walking and other behaviour seemed to be normal. She could vaguely remember that she visited her friend at 11.30 am and that her friend's husband came back at 1.30 pm; thus, she was totally amnesic from 11.30 am to 1.30 pm. She became gradually well and normal by 3.30 pm. She was admitted to a hospital on that day when she had non-throbbing dull headache but was found to be normal on neurological examination. On 28 October, 1985, she was admitted to our hospital for the further examination. Her family history revealed cerebrovascular diseases in her father, an uncle and an aunt. She did not smoke or drink regularly. Her blood pressure was 132/84 mm Hg on admission. Physical and neurological examination including an intelligence test revealed no abnormal findings. ECG showed mild left ventricular hypertrophy and monitored ECG demonstrated sporadic supraventricular premature contraction but otherwise normal. Laboratory examination revealed no impaired glucose tolerance or hyperlipidaemia. EEG,

brain CT and IV-DSA of the head and neck revealed no abnormalities. PET study demonstrated slight reduction of both rCBF and rCMRO₂ in the right basal ganglia and frontal lobe (fig 3). Absolute values for rCBF and rCMRO₂ of the other cortices and deep structures were within the normal range.

Case 3. A 62 year old female was found to be behaving unusually at 3.00 pm, 23 November, 1986, by her husband at home. She completely lost her memory for the plants which she had prepared for her friend and repeatedly asked "Why are these here?" She could not recall the occurrence just before, and for example, she repeatedly advised her grandchildren to have supper which they had just finished. Her family noticed no paresis, convulsive movements, aphasia or disturbance in other higher cortical functions. She became gradually well and was almost normal at 8.00 pm but she completely lost her memory in a five hour period from 3.00 pm to 8.00 pm. She was admitted to our hospital for evaluation of the amnesic episode on 23 December, 1986. Her family history or her past history was not remarkable. On admission, she was normotensive and physical and neurological examinations including mental tests were all within the normal range. Her serum chemistry including glucose tolerance test were normal except for slightly elevated

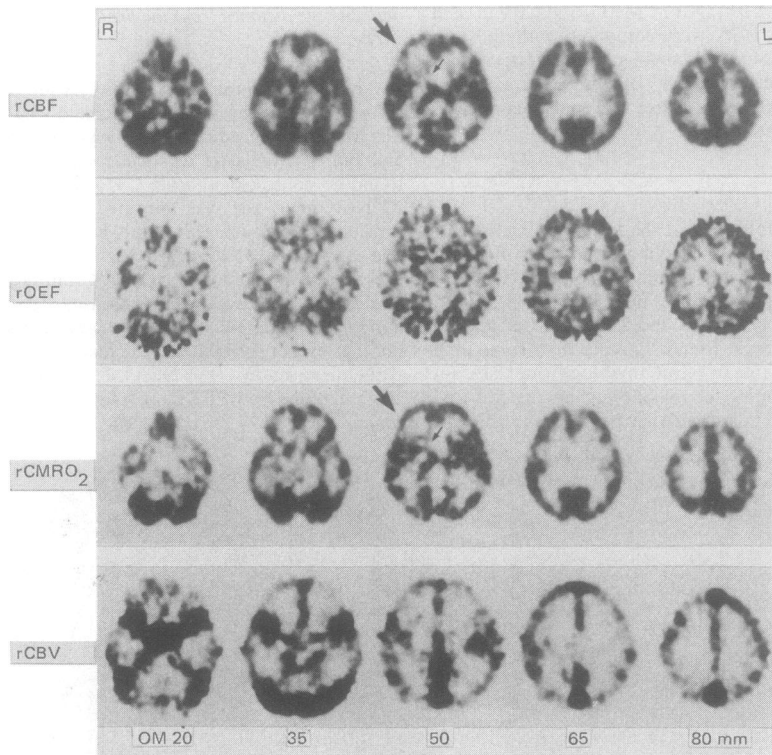


Fig 3 Regional cerebral blood flow (rCBF), oxygen extraction fraction (rOEF), cerebral metabolic rate of oxygen (rCMRO₂) and cerebral blood volume (rCBV) in case 2. Numbers in the bottom indicate the distance from the orbitomeatal (OM) line to the plane. Slight reduction of both rCBF and rCMRO₂ are seen in the right basal ganglia (small arrows) and frontal lobe (large arrows).

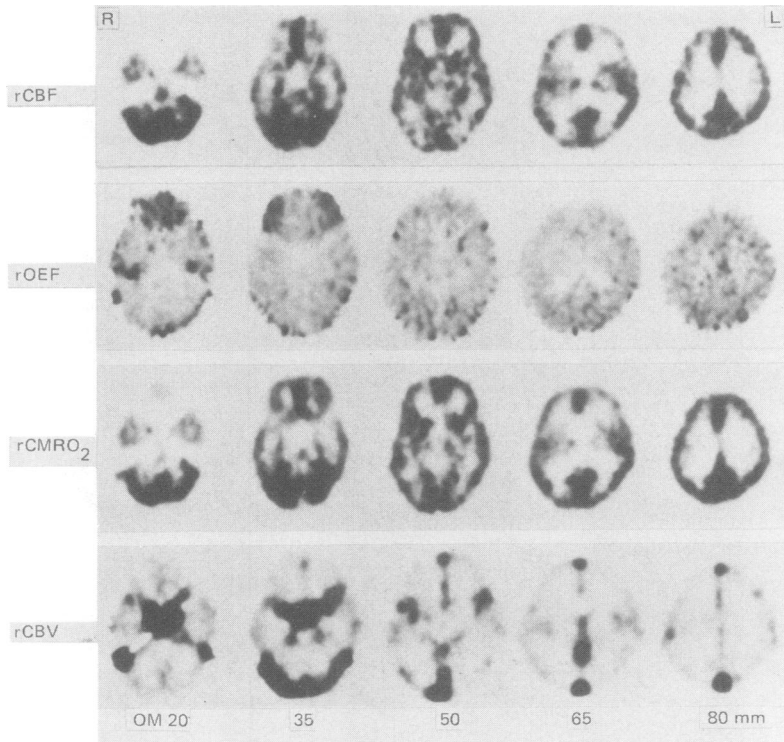


Fig 4 Regional cerebral blood flow (rCBF), oxygen extraction fraction (rOEF), cerebral metabolic rate of oxygen (rCMRO₂) and cerebral blood volume (rCBV) in case 3. No abnormal changes in these parameters are seen.

cholesterol level (288 mg/dl, normal range; 130–250). ECG, brain CT and EEG showed no specific changes. Carotid and vertebral angiogram showed diffuse but not remarkable intracranial arteriosclerosis. PET study for CBF, CMRO₂ and CBV revealed no localised or diffuse abnormalities (fig 4).

Case 4. A 53 year old male had two episodes of transient amnesia. The first episode occurred on 28 September 1984 at 3.30 pm when he was talking at work. He suddenly started to talk repeatedly on the same subject. Sometimes the conversation was disrupted and he could not respond to what he was asked. He complained of a non-throbbing headache and became pale and was transferred to the emergency hospital. At the hospital he could not retain new memories but neurological examination or head CT revealed no abnormalities. His total amnesia persisted from 3.30 pm to 9.30 pm and gradually returned to his normal state. Neurological examination, head CT and EEG performed at our hospital two days after the attack also revealed no abnormality. The second amnesic episode occurred on 18 January 1987 around 6.00 pm when his colleagues working with him were aware of his behaviour. He repeated the same question and became pale and, soon thereafter was taken to a hospital. He had no memory of the attending doctors and nurses. After his amnesic period of five hours neurological examination in the hospital were normal. Three months after the second episode

he was admitted to our clinic for the further examinations. One of his brothers was hypertensive. He smoked until aged 25 years but quitted thereafter. He was a moderate drinker. Blood pressure on admission was 104/70 mm Hg and other physical and neurological examinations were normal. ECG, chest radiograph and echocardiogram revealed no abnormality. His serum triglyceride was 222 mg/dl (normal range; 50–150), but cholesterol and glucose tolerance were within the normal range. EEG was normal and brain CT, brain magnetic resonance imaging (MRI) (Sigma System, GE Medical Systems, Milwaukee, Wisconsin, USA; spatial resolution 0.31 mm) and intra-arterial-DSA of the head and neck demonstrated no abnormality. Brain PET images for CBF, OEF, CMRO₂ and CBV showed no localised lesions (fig 5) and absolute values for rCBF, rOEF, rCMRO₂ and rCBV were also within normal range.

Results

Comparison of clinical, neuroradiological and PET findings between patients with TGA and those with TIA

Tables 1 and 2 depict clinical and neuroradiological findings in four patients with TGA and seven with TIA. The averaged mean arterial blood pressure was

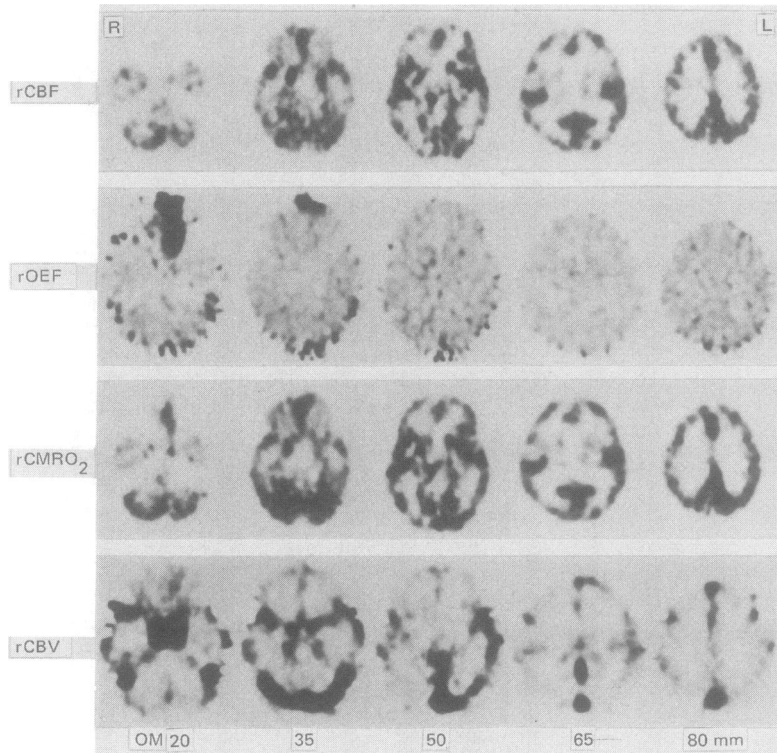


Fig 5 Regional cerebral blood flow (rCBF), oxygen extraction fraction (rOEF), cerebral metabolic rate of oxygen (rCMRO₂) and cerebral blood volume (rCBV) in case 4. No abnormalities are seen.

Table 1 Clinical and neuroradiological findings in 4 patients with transient global amnesia (TGA) and 7 patients with transient ischaemic attacks (TIA)

No.	Age (yr)	Sex	Transient neurological features (type and number of events)	Blood pressure		Ocular Fundi (K-W-K)	ECG LVH/ST- change
				SBP/DBP (mm Hg)	MABP (mm Hg)		
TGA							
1	61	F	Amnesia (1)	112/74	87	I	-/-
2	59	F	Amnesia (1)	132/84	100	I	+/-
3	62	F	Amnesia (1)	112/76	88	O	-/-
4	53	M	Amnesia (2)	104/70	81	O	-/-
Mean, (SD) 59 (4)					89 (8)*		
TIA							
1	52	M	Paraparesis (VB, 5)	130/ 84	99	I	-/-
2	64	M	Paraparesis (VB, 2)	150/ 84	106	IIb	-/-
3	71	M	Left hemiparesis (C, 1)	190/100	130	I	-/+
4	70	F	Dizziness, dysarthria (VB, 20)	156/ 86	109	IIa	-/-
5	60	F	Right numbness (C, 38)	142/ 70	94	I	+/-
6	61	M	Amaurosis fugax (C, 1)	134/ 88	103	IIb	-/-
7	68	M	Left hemiparesis (C, 10)	164/ 78	107	I	+/-
Mean, (SD) 64 (7)					107 (11)		

SBP: systolic blood pressure; DBP: diastolic blood pressure; MABP: mean arterial blood pressure; K-W-K: Keith-Wagener-Keidai classification; EC: electrocardiogram; LVH: left ventricular hypertrophy; CT: computed tomography; PET: positron emission tomography; CBF: cerebral blood flow; ICA: internal carotid artery; VA: vertebral artery; +, -, present or absent of abnormal findings, respectively; VB: vertebrobasilar TIA; C: carotid TIA. *p = 0.05, as TIA.

Table 2 Serum chemistry and smoking and drinking habits in patients with transient global amnesia (TGA) and transient ischaemic attacks (TIA)

	TGA (n = 4)	TIA (n = 7)
Total cholesterol mg/dl	230 (23)	236 (52)
Triglyceride mg/dl	137 (76)	167 (56)
Fasting blood sugar mg/dl	93 (7)	103 (12)
Blood urea nitrogen mg/dl	14 (1)	16 (3)
Creatinine mg/dl	1.0 (0.2)	1.1 (0.3)
Smoking > 10 cigarettes/day	1	3
Drinking > 34 g alcohol/day	2	3

Values are mean (SD).

significantly higher in TIA (107 SD 11 mm Hg) than TGA (89 SD 8 mm Hg). The patients with TIA showed more severe hypertensive vascular and retinal changes in the ocular fundi and a higher incidence of abnormal findings on CT and angiogram in comparison with TGA, although all low density areas seen on CT in TIA were small and clinically silent. These findings indicate that systemic arteriosclerosis is more advanced in our TIA patients than in TGA. Serum chemistry, smoking and drinking habits were similar in the two groups (table 2). The values for arterial blood gases, pH, haemoglobin and haematocrit on the PET study were within the normal range in the TGA as well as TIA and each value did not differ between the two groups (table 3). In seven patients with TIA, focal decrease in CBF was detected in all, while only one among four patients with TGA showed focal decrease in CBF (table 1).

An example of abnormal PET findings in patients with TIA is shown in fig 6. rCBF and rCMRO₂ were decreased not only in the right basal ganglia where a

Table 3 Arterial blood gases, pH, haemoglobin (Hb) and haematocrit (Hct) in patients with transient global amnesia (TGA) and transient ischaemic attacks (ITA)

	TGA (n = 4)	TIA (n = 7)
pCO ₂ mm Hg	39.7 (2.8)	40.4 (2.7)
PO ₂ mm Hg	70.4 (2.6)	81.5 (11.9)
pH	7.42 (0.02)	7.41 (0.03)
Hb g/dl	13.4 (1.4)	13.9 (1.2)
Hct %	40.0 (4.2)	42.8 (3.9)

Values are mean (SD).

low density area was seen on brain CT but also in the frontal and parieto-occipital lobes.

Table 4 depicts mean values for CBF, OEF, CMRO₂ and CBV in each ROI of patients with TGA and TIA. The values for OEF, CMRO₂ and CBV were excluded from the case TGA No 1 because of inappropriate head position during the study. Regional CBF and CMRO₂ in patients with TGA were higher than with TIA. The differences in rCBF were statistically significant in bilateral parietal and left occipital cortices and in bilateral striatum, while the differences in rCMRO₂ were significant in the left hippocampus and in the right thalamus. In contrast, rOEF tended to be higher in patients with TIA. These data indicate that total as well as regional CBF and CMRO₂ in patients with TGA were better preserved as compared with TIA.

Discussion

In this communication four patients with TGA were analysed neuroradiologically and the findings were

Neuroradiology		PET
Brain CT		
Site of low density area	Angiography	Regions with decreased CBF
—	—	—
—	—	Right frontal lobe-basal ganglia
—	Arteriosclerosis	—
—	—	—
—	Right ICA occlusion, left VA stenosis	Right parietal lobe
Left cerebellum	Right ICA stenosis	Left cerebellum and left fronto-temporo-parietal lobe
Left caudate nucleus	—	Left frontal lobe-basal ganglia
—	—	Right frontal lobe, right thalamus and left basal ganglia
—	Arteriosclerosis	Left temporal lobe
—	Bilateral ICA stenosis	Whole cerebrum
Right caudate nucleus	Right ICA arteriosclerosis	Right basal ganglia, right frontal and parieto-occipital lobe

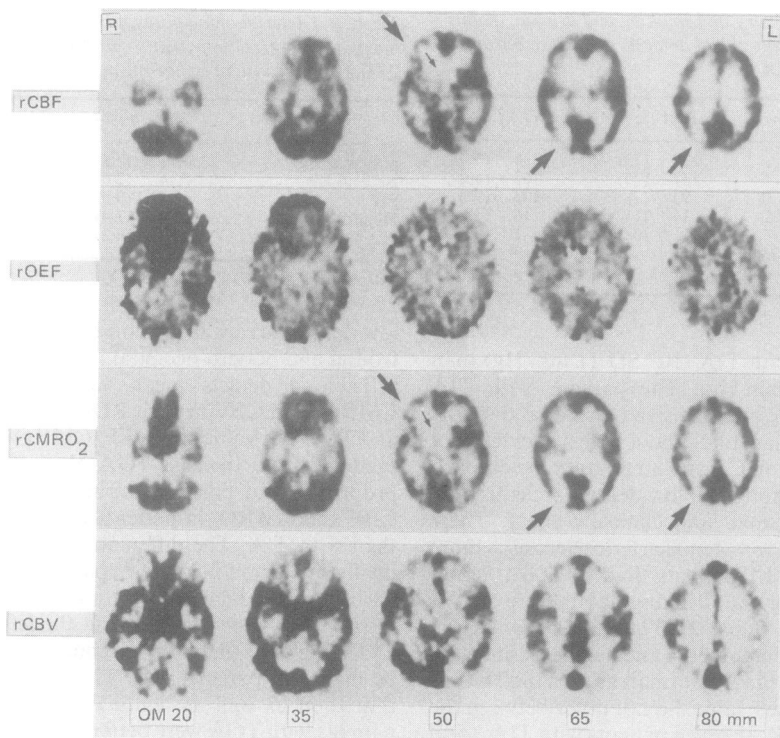


Fig 6 Regional cerebral blood flow (rCBF), oxygen extraction fraction (rOEF), cerebral metabolic rate of oxygen (rCMRO₂) and cerebral blood volume (rCBV) in the patient TIA 7. Numbers in the bottom indicate the distance from the orbitomeatal (OM) line to the plane. rCBF and rCMRO₂ were decreased not only in the right basal ganglia (small arrows) where a low density area was seen on brain CT but also in frontal and parieto-occipital lobes (large arrows).

compared with TIA. Three were women aged 59 to 62 years old, and one was a 53 year old man. None of these had previous histories of cerebrovascular diseases, head trauma, epilepsy or migraine. Their amnesic episode lasted two to six hours without other neurological deficits except for two cases who complained of mild non-throbbing headache. The major sign of amnesia was such that the patients could not recall very recent events and they repeated the same behaviour or speech. Retrograde amnesia was evident in two cases but did not exceed one hour. Neuro-radiological examinations including brain CT, MRI, DSA and PET revealed no abnormalities in the responsible regions for the development of transient amnesia. EEG study was normal in all the patients.

Several conditions such as TIA,²⁻⁷ epilepsy,^{8,9} migraine^{10,11} have been reported to be possible causes for the development of TGA. Despite numerous case reports and their analysis, however, the mechanism of TGA remain a matter for debate. Our results indicate that an organic cause may operate for the occurrence

of TGA, but that it leaves no permanent sequela of an organic or structural nature in the brain.

In addition to initial symptoms and signs described by Fisher and Adams,¹ some neurological deficits such as transient ataxia, dizziness, facial palsy or nystagmus have been frequently observed during or between episodes of TGA. Kushner *et al*⁷ recently have mentioned in a case-control study that only antecedent cerebral ischaemia appeared a risk factor for the initiation of TGA. In five of 13 TGA cases, brain CT revealed focal thalamic and temporal lobe abnormalities.⁷ Mathew *et al*⁴ examined 14 TGA patients and found that 11 had cerebrovascular insufficiency in the vertebrobasilar and/or posterior cerebral arterial distributions. Shuttleworth *et al*³ reported two cases of TGA which were developed during cardiac angiography and suggested that transient and focal impairment of cerebral circulation due to embolisation was the most probable mechanism of the initiation of TGA. These observations support the hypothesis¹ that at least in part TGA results from transient ischaemia

Table 4 Comparison of regional cerebral blood flow (rCBF), oxygen extraction fraction (rOEF), cerebral metabolic rate of oxygen (CMRO₂) and cerebral blood volume (rCBV) between patients with transient global amnesia (TGA) and transient ischaemic attacks (TIA)

	rCBF ml/100 ml/min		rOEF		rCMRO ₂ ml/100 ml/min		rCBV ml/100 ml	
	TGA (n = 4)	TIA (n = 7)	TGA (n = 3)	TIA (n = 7)	TGA (n = 3)	TIA (n = 7)	TGA (n = 3)	TIA (n = 7)
Frontal cortex								
Left	35.9 (6.5)	30.9 (3.8)	0.38 (0.03)	0.42 (0.04)	2.50 (0.17)	2.45 (0.31)	3.11 (0.48)	3.32 (0.66)
Right	34.1 (3.2)	29.7 (5.8)	0.39 (0.03)	0.43 (0.06)	2.28 (0.13)	2.34 (0.34)	3.07 (0.26)	3.14 (0.79)
Temporal cortex								
Left	36.1 (4.6)	28.5 (2.1)	0.38 (0.03)	0.42 (0.05)	2.41 (0.09)	2.25 (0.36)	3.16 (0.52)	3.19 (0.29)
Right	34.0 (3.2)	28.3 (3.8)	0.38 (0.03)	0.44 (0.04)	2.39 (0.25)	2.28 (0.20)	3.31 (0.55)	3.44 (0.57)
Hippocampus								
Left	34.9 (2.9)	28.8 (1.8)	0.34 (0.02)	0.37 (0.04)	2.29 (0.18)†	1.91 (0.11)	3.89 (0.92)	4.69 (1.74)
Right	35.3 (1.8)	29.5 (3.7)	0.33 (0.03)	0.38 (0.04)	2.17 (0.09)	1.99 (0.12)	4.52 (1.68)	4.66 (1.52)
Parietal cortex								
Left	38.6 (3.2)‡	29.2 (2.4)	0.39 (0.05)	0.43 (0.04)	2.76 (0.44)	2.33 (0.16)	3.03 (0.43)	2.73 (0.50)
Right	37.2 (0.8)‡	30.5 (3.6)	0.40 (0.04)	0.43 (0.04)	2.67 (0.46)	2.41 (0.16)	3.20 (0.71)	3.65 (0.88)
Occipital cortex								
Left	37.0 (1.3)‡	28.9 (4.0)	0.39 (0.06)	0.44 (0.03)	2.67 (0.51)	2.33 (0.18)	3.49 (0.58)	3.25 (0.87)
Right	36.0 (3.3)	27.8 (6.4)	0.40 (0.05)	0.45 (0.03)	2.67 (0.61)	2.26 (0.39)	4.24 (1.31)	3.52 (0.76)
Insular cortex								
Left	39.9 (2.2)‡	29.9 (4.4)	0.39 (0.01)	0.42 (0.06)	2.73 (0.48)	2.34 (0.29)	2.90 (0.18)	2.78 (0.39)
Right	38.5 (4.1)*	30.4 (6.1)	0.40 (0.02)	0.42 (0.03)	2.60 (0.43)	2.38 (0.52)	3.04 (0.29)	2.95 (0.52)
Substantia nigra								
Left	39.8 (4.7)	31.6 (6.3)	0.36 (0.04)	0.37 (0.05)	2.37 (0.59)	2.12 (0.22)	3.38 (0.86)	3.62 (0.80)
Right	37.2 (5.1)	30.6 (3.9)	0.34 (0.02)	0.37 (0.05)	2.43 (0.27)*	2.08 (0.12)	3.42 (0.63)	3.97 (0.87)
White matter								
Left	17.9 (2.8)	14.8 (5.4)	0.33 (0.02)	0.40 (0.09)	1.04 (0.18)	1.01 (0.25)	2.10 (0.28)	1.71 (0.56)
Right	17.6 (3.5)	14.1 (5.0)	0.36 (0.00)	0.39 (0.05)	1.13 (0.35)	0.98 (0.24)	2.30 (0.47)	1.94 (0.55)
Brainstem								
Left	47.0 (7.8)	39.4 (6.5)	0.37 (0.04)	0.40 (0.05)	3.09 (0.06)	2.94 (0.65)	2.97 (0.76)	3.29 (0.78)
Right	49.2 (10.3)	39.6 (3.3)	0.37 (0.04)	0.40 (0.04)	3.01 (0.10)	3.08 (0.55)	3.11 (0.38)	3.77 (1.62)
Brainstem	35.9 (3.2)	30.6 (3.9)	0.31 (0.04)	0.34 (0.04)	2.18 (0.24)	1.91 (0.16)	3.85 (1.35)	4.66 (2.20)

Values are mean (SD) (n): number of patients examined. *p < 0.05, †p < 0.01, ‡p < 0.001 vs. TIA.

especially in the territory of vertebrobasilar and posterior cerebral arteries. Interestingly, analyses of the prognosis of TGA have shown that subsequent strokes or deaths in TGA are similar to those in the general population.^{15,16} It has also been shown that the degree of severity of atherosclerosis in the extracranial carotid arteries is significantly lower in patients with TGA than in focal TIA.¹⁷ These findings strongly indicate that TGA is unlikely to be based on the persistent ischaemia due to cerebral arterial diseases.

In the present study patients with TGA showed no neurological disorders except for mild headache, or significant risk factors for cerebrovascular disease. They had no remarkable abnormalities on brain CT or DSA. Furthermore, PET revealed no changes in any regions of the brain, and the regional values for CBF and CMRO₂ were better maintained in comparison with those in patients with TIA. For example, average values for cortical CBF and CMRO₂ in the volunteers (aged 40 years or less) in our institute are 38 ml/100 ml/min and 2.8 ml/100 ml/min, respectively (unpublished data). The values for cortical CBF and CMRO₂ in patients with TGA are not much different even from these control values. Recent studies on patients with TIA and/or reversible ischaemic neurological deficits (RIND) revealed a coupled reduction of rCBF and rCMRO₂ in the symptomatic hemisphere¹⁸⁻²¹ and

increase in OEF in some regions.²¹ These results suggest that tissue damage and/or neuronal cell loss in the brain contribute at least to some extent for the symptoms in TIA and RIND. In contrast, risk factors and neuroradiological abnormalities were absent in our TGA patients, supporting the notion that the development of TGA does not depend on the focal tissue damage or persistent circulatory disturbance, which was shown by PET, although PET study has limitation as a diagnostic tool in spatial resolution.

Several authors^{8,9} have indicated that TGA is more likely to be epileptogenic in origin because of their abruptness of onset, reversibility and occasional association with EEG abnormalities such as transient temporal spikes. In other studies, no epileptiform activity was found among the patients with TGA.²² Other features of TGA such as low rate of recurrence, relatively long period of the attack, preserved consciousness and lack of convulsion or motor dysfunction seem to argue against a relationship between TGA and seizures. In addition, recently, PET studies have demonstrated hypometabolic areas in the brain in the most patients with partial seizures.^{23,24} Thus if TGA is a kind of seizure, which usually has its focus in the temporal lobe or hypothalamus, PET study may show focal abnormalities, namely reduction of blood flow and metabolism even between the ictus. Both our

PET and CT studies, however, failed to demonstrate any focal abnormalities in all cases but one (case 2) who had slight reduction of rCBF and rCMRO₂ in the right basal ganglia and frontal cortex; these changes cannot be considered to be responsible for the memory disturbance.

Several reports demonstrating a TGA connection with migraine,^{10,11} suggest that TGA and migraine are based on the similar functional vasomotor disorder. Although two cases in this study had non-throbbing headache, none of these showed visual symptoms such as scintillating scotoma, homonymous hemianopsia, micropsia, or bilateral amaurosis, which are frequently accompanied with migraine. Although the aetiology of migraine is still unclear, migraine itself does not explain the primary mechanism of TGA.

Notable risk factors for cerebrovascular disease were not found in our TGA patients who showed almost normal EEG, angiogram of the head and neck, brain CT and PET. These observations offer minimum evidence that TGA is a form of chronic cerebral ischaemia, epilepsy or migraine. To clarify the aetiology of TGA, further studies on cerebral circulation and metabolism are needed, especially in the early stage or during the attack.

References

- 1 Fisher CM, Adams RD. Transient global amnesia. *Acta Neurol Scand* 1964;**40**(suppl 9):7-83.
- 2 Heathfield KWG, Croft PB, Swash M. The syndrome of transient global amnesia. *Brain* 1973;**96**:729-36.
- 3 Shuttleworth EC, Wise GR. Transient global amnesia due to arterial embolism. *Arch Neurol* 1973;**29**:340-2.
- 4 Mathew NT, Meyer JS. Pathogenesis and natural history of transient global amnesia. *Stroke* 1974;**5**:303-11.
- 5 Rowan AJ, Protass LM. Transient global amnesia: clinical and electroencephalographic findings in 10 cases. *Neurology* 1979;**29**:869-72.
- 6 Ponsford JL, Donnan GA. Transient global amnesia—a hippocampal phenomenon? *J Neurol Neurosurg Psychiatry* 1980;**43**:285-7.
- 7 Kushner MJ, Hauser WA. Transient global amnesia: a case-control study. *Ann Neurol* 1985;**18**:684-91.
- 8 Fisher CM. Transient global amnesia-precipitating activities and other observations. *Arch Neurol* 1982;**39**:605-8.
- 9 Cantor FK. Transient global amnesia and temporal lobe seizures. *Neurology* 1971;**21**:430-1.
- 10 Caplan L, Chedru F, Lhermitte F, Mayman C. Transient global amnesia and migraine. *Neurology* 1981;**31**:1167-70.
- 11 Crowell GF, Stump DA, Biller J, McHenry LC Jr, Toole JF. The transient global amnesia-migraine connection. *Arch Neurol* 1984;**41**:75-9.
- 12 Frackowiak RSJ, Lenzi GL, Jones T, Heather JD. Quantitative measurement of regional cerebral blood flow and oxygen metabolism in man using ¹⁵O and positron emission tomography: theory, procedure, and normal values. *J Comput Assist Tomogr* 1980;**4**:727-36.
- 13 Heyman A (chairman, Study Group on TIA Criteria and Detection). Report of the Joint Committee for Stroke Facilities. XI. Transient focal cerebral ischemia: Epidemiological and clinical aspects. *Stroke* 1974;**5**:277-87.
- 14 Lammertsma AA, Jones T. Correction for the presence of intravascular oxygen-15 in the steady-state technique for measuring regional oxygen extraction ratio in the brain: 1. Description of the method. *J Cereb Blood Flow Metab* 1983;**3**:416-24.
- 15 Hinge HH, Jensen TS, Kjaer M, Marquardsen J, Olivarius Bdf. The prognosis of transient global amnesia. Results of a multicenter study. *Arch Neurol* 1986;**43**:673-6.
- 16 Miller JW, Petersen RC, Metter EJ, Millikan CH, Yanagihara T. Transient global amnesia: Clinical characteristics and prognosis. *Neurology* 1987;**37**:733-7.
- 17 Feuer D, Weinberger J. Extracranial carotid artery in patients with transient global amnesia: evaluation by real-time B-mode ultrasonography with duplex doppler flow. *Stroke* 1987;**18**:951-3.
- 18 Gibbs JM, Wise RJS, Leenders KL, Jones T. Evaluation of cerebral perfusion reserve in patients with carotid-artery occlusion. *Lancet* 1984;**1**:310-4.
- 19 Powers WJ, Grubb RL Jr, Raichle ME. Physiological responses to focal cerebral ischaemia in humans. *Ann Neurol* 1984;**16**:546-52.
- 20 Powers WJ, Grubb RLJ, Darriet D, Raichle ME. Cerebral blood flow and cerebral metabolic rate of oxygen requirements for cerebral function and viability in humans. *J Cereb Blood Flow Metab* 1985;**5**:600-8.
- 21 Itoh M, Hatazawa J, Pozzilli C, et al. Haemodynamics and oxygen metabolism in patients after reversible ischaemic attack or minor ischaemic stroke assessed with positron emission tomography. *Neuroradiology* 1987;**29**:416-21.
- 22 Miller JW, Yanagihara T, Petersen RC, Klass DW. Transient global amnesia and epilepsy. Electroencephalographic distinction. *Arch Neurol* 1987;**44**:629-33.
- 23 Theodore WH, Dorwart R, Holmes M, Porter RJ, DiChiro G. Neuroimaging in refractory partial seizures: Comparison of PET, CT, and MRI. *Neurology* 1986;**36**:750-9.
- 24 Stefan H, Pawlik G, Böcher-Schwarz HG, Biersack HJ, Burr W, Penin H, Heiss W-D. Functional and morphological abnormalities in temporal lobe epilepsy: a comparison of interictal and ictal EEG, CT, MRI, SPECT, and PET. *J Neurol* 1987;**234**:377-84.