



Letter to the Editor

Small world brain network characteristics during EEG Holter recording of a stroke event



1. Introduction

Several studies revealed that cerebral ischemia provokes transient or permanent disruption of functional connections both locally and distantly from the lesion. Recently, brain connectivity has been described using graph theory, a mathematical approach which depicts the brain as a network in order to simplify its complex topology. The human brain consists of complex inhibitory and excitatory circuits located in specialized areas, which are engaged in sharing and integrating information with a time-varying interplay at resolution in the millisecond range. Brain functional activity is based on a balance between manifold processes of local segregation and global integration, quantified by the *clustering coefficient* and the *path length coefficient*, respectively (Bassett and Bullmore, 2006). A connectivity pattern characterized by high *clustering* and short *path*, known as “small world” network model (Watts and Strogatz, 1998), reflects the need of the brain networks to satisfy the competitive demands of local and global processing. Recent studies demonstrated that stroke presents functional balance disruption with respect to control subjects (Yin et al., 2014).

In this unique case report, we analyzed an EEG Holter recording before and during a stroke attack, using graph theory.

2. Materials and methods

2.1. Recordings and pre-processing

A 72-year-old male patient, with a previous history of chronic hypertension, had been referred to our hospital's emergency unit because of sudden onset of confusion and speech production difficulty. Brain-MRI documented an acute ischemic lesion in the fronto-basal region of the left medial cerebral artery (MCA) territory, and extracranial ultrasound revealed left internal carotid artery (ICA) occlusion.

Approximately one week after the first event, the patient came to our attention for recurrent, transient episodes of severe weakness of the right limbs and inferior facial paresis, with almost complete recovery. A new MRI showed multiple acute and subacute ischemic lesions in the left MCA territory (frontal lobe, putamen, temporo-insular region, parietal lobe) with moderate mass effect.

EEG Holter (Fp1, Fp2, O1, O2, T3, C3, C4, T4) was recorded for evaluating signs of stroke-related epilepsy. After more than 14 h of recording, the patient presented another stroke attack during nocturnal sleep, experiencing persistent right facio-brachio-crural hemiplegia without subsequent recovery.

Holter EEG data were subdivided offline into three 40-min-periods of interest: Baseline (12 h before the event), Stroke I (first 40 min-period from the event), Stroke II (40 min-period immediately following Stroke I).

Data were analyzed with Matlab using scripts based on EEGLAB. EEG recordings (band-pass 0.2–47 Hz, sampling frequency 256 Hz) were fragmented in 2-s duration epochs. Detection and rejection of artifacts were performed through independent component analysis.

A further brain MRI, performed after this last event, showed enlargement of the recent ischemic lesions in left hemisphere with extensive involvement of frontal lobe, temporo-insular area and basal nuclei and increased compression on the left lateral ventricle.

2.2. Functional connectivity

Functional connectivity analysis was obtained by a spectral coherence algorithm of the coupling between two (EEG) signals at any given frequency (delta (2–4 Hz), theta (4–8 Hz), alpha1 (8–10 Hz), alpha2 (10–13 Hz), beta1 (13–20 Hz), and beta2 (20–30 Hz)). It was computed by magnitude squared coherence (*mscohere*) with home-made Matlab software. In addition, total coherence was calculated by averaging all possible links between all pairs of contacts in order to obtain an index of global brain connectivity.

2.3. Graph analysis

A network is a mathematical representation of a real-world complex system and is defined by a collection of nodes (vertices) and links (edges) between pairs of nodes. In this study, weighted and undirected networks were built. Network vertices are the electrode contacts, while edges are weighted by the *mscohere* value.

Weighted Clustering C^w and Weighted Characteristic Path length L^w were used to compute the small world coefficient S^w , defined as the ratio between normalized C^w and L^w , and used to describe the balance between local connectedness and global integration brain processes.

2.4. Compliance with ethical standards

Ethical approval: All procedures performed in studies involving human participants were in accordance with the ethical standards of the institutional and national research committee and with the 1964 Helsinki declaration and its later amendments or comparable ethical standards. Informed consent was obtained from the participant included in this study.

3. Results

Fig. 1A shows the brain imaging after the event (DWI, FLAIR, T1, T2* and MR angiography): FLAIR images and

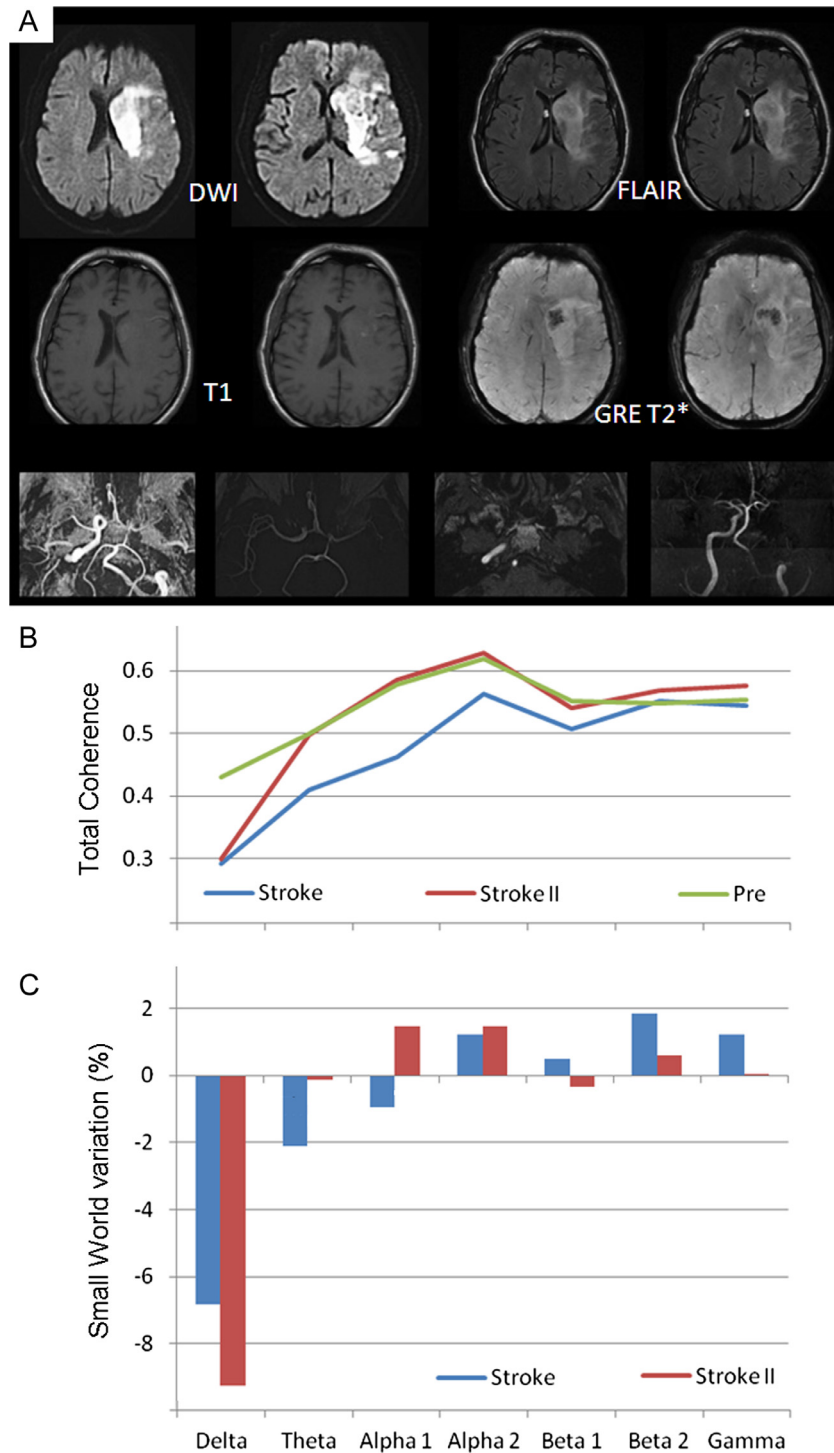


Fig. 1. The A part of the figure shows MRI findings after the ischemic stroke event (DWI, FLAIR, T1 and T2* are illustrated). The B part illustrates the EEG signal total coherence. The C part of the figure reports the percentage variation of Small World connectivity at the beginning and after the stroke event compared to the baseline period.

diffusion-weighted images (DWI) revealed an extensive, recent ischemic lesion in the left MCA territory involving frontal lobe, temporo-insular area and basal ganglia; T1-weighted images and gradient-echo (GRE) T2*-weighted sequences showed signs of partial hemorrhagic transformation in different phases of evolution. A MR Angiography (MRA), previously performed, showed complete occlusion of the left ICA and collateral flow to the left MCA, provided by the contralateral ICA via the anterior communicating artery and the vertebrobasilar system via the posterior

communicating artery. Fig. 1B illustrates the EEG signal total coherence in the different frequency bands for the three different time periods. A prominent decrease of functional coupling was observed at the beginning of the stroke event, and a partial recovery near to the end of event, except for the delta band. Fig. 1C reports the small world percentage change at the beginning and at the end of the stroke event compared to the baseline period. It shows an evident reduction in the delta band and, to a lesser extent, an increase in the alpha bands.

4. Discussion

The present results, collected in a unique case of EEG recordings during an ischemic stroke event, confirm that stroke provokes immediate functional changes of brain networks. The modulation of EEG rhythms is noted to be frequency-dependent, involving most evidently the delta and alpha EEG bands. The decrease of SW in the delta band and increase of SW in the alpha bands are in line with previous evidence of SW modulation in physiological and pathological brain networks (Miraglia et al., 2016; Vecchio et al., 2014, 2016a,b; Caliandro et al., 2016). It could be supposed that locally reduced and globally increased connectivity in the alpha rhythm (as a possible interpretation of the increased SW) might reflect a balance, in the acute phase, between functional impairment due to acute stroke and an attempt of compensation. On the other hand, the reduction of delta SW could be seen as a sort of more ordered network but in a pathological band, namely an indication of physiological disconnection. In conclusion, stroke-related acute cerebral network modulation as revealed by analysis of EEG data could reflect the electrophysiological counterpart of disruptive and adaptive brain processes of integration and segregation that are well described by graph theory indexes.

Conflict of interest

None.

References

- Bassett DS, Bullmore E. Small-world brain networks. *Neuroscientist* 2006;12:512–23.
- Caliandro P, Vecchio F, Miraglia F, Reale G, Della Marca G, La Torre G, et al. Small-world characteristics of cortical connectivity changes in acute stroke. *Neurorehabil Neural Repair* 2016. pii: 1545968316662525.
- Miraglia F, Vecchio F, Bramanti P, Rossini PM. EEG characteristics in “eyes-open” versus “eyes-closed” conditions: small-world network architecture in healthy aging and age-related brain degeneration. *Clin Neurophysiol* 2016;127:1261–8.
- Vecchio F, Miraglia F, Marra C, Quaranta D, Vita MG, Bramanti P, Rossini PM. Human brain networks in cognitive decline: a graph theoretical analysis of cortical connectivity from EEG data. *J Alzheimers Dis* 2014;41:113–27.
- Vecchio F, Miraglia F, Piludu F, Granata G, Romanello R, Caulo M, et al. “Small world” architecture in brain connectivity and hippocampal volume in Alzheimer’s disease: a study via graph theory from EEG data. *Brain Imaging Behav* 2016. <http://dx.doi.org/10.1007/s11682-016-9528-3>.
- Vecchio F, Miraglia F, Quaranta D, Granata G, Romanello R, Marra C, et al. Cortical connectivity and memory performance in cognitive decline: a study via graph theory from EEG data. *Neuroscience* 2016b;316:143–50.
- Watts DJ, Strogatz SH. Collective dynamics of ‘small-world’ networks. *Nature* 1998;393:440–2.
- Yin D, Song F, Xu D, Sun L, Men W, Zang L, et al. Altered topological properties of the cortical motor-related network in patients with subcortical stroke revealed by graph theoretical analysis. *Hum Brain Mapp* 2014;35:3343–59.

Fabrizio Vecchio *

Brain Connectivity Laboratory, IRCCS San Raffaele Pisana, Rome, Italy

* Corresponding author at: Brain Connectivity Laboratory, IRCCS San Raffaele Pisana, Via Val Cannuta, 247, 00166 Rome, Italy.

E-mail addresses: fabrizio.vecchio@uniroma1.it, fabrizio.vecchio@sanraffaele.it

Francesca Miraglia

Brain Connectivity Laboratory, IRCCS San Raffaele Pisana, Rome, Italy
Institute of Neurology, Dept. Geriatrics, Neuroscience & Orthopedics,
Catholic University, Policlinic A. Gemelli, Rome, Italy

Angela Romano

Institute of Neurology, Dept. Geriatrics, Neuroscience & Orthopedics,
Catholic University, Policlinic A. Gemelli, Rome, Italy

Placido Bramanti

IRCCS Centro Neurolesi Bonino-Pulejo, Messina, Italy

Paolo Maria Rossini

Brain Connectivity Laboratory, IRCCS San Raffaele Pisana, Rome, Italy
Institute of Neurology, Dept. Geriatrics, Neuroscience & Orthopedics,
Catholic University, Policlinic A. Gemelli, Rome, Italy

Available online 3 November 2016