

Letter to the Editor

Hemichorea improvement following endarterectomy for internal carotid artery stenosis


Keywords:

Hemichorea
Internal carotid artery stenosis
Cerebral blood flow
Endarterectomy

Dear Editor,

Chorea is a hyperkinetic syndrome characterized by brief, irregular purposeless movements resulting from a continuous flow of random muscle contractions [1]. Chorea has various differential diagnoses such as infections, autoimmune diseases, genetic disorders, drug exposure, neoplasm, and stroke [1]. Here, we report a rare case of hemichorea caused by brain hypoperfusion due to severe carotid artery stenosis and successfully treated by carotid endarterectomy.

A 73-year-old man abruptly developed continuous involuntary movements of his left arm and leg. He had no history of diabetes mellitus or prior neuroleptic drug exposure. He had no significant family history. His brain MRI showed no hemorrhagic or ischemic lesions. Carotid duplex ultrasonography revealed severe stenosis in the right internal carotid artery (ICA). His serum glucose level was 102 mg/dl and glycated hemoglobin (HbA1c) level was 6.0%. Clopidogrel (75 mg daily) was prescribed by his general practitioner. His involuntary movements persisted. After two weeks from the onset of symptoms, he was referred to our hospital. Neurological examination was unremarkable except for choreic movements of his left face and distal parts of his left upper and lower extremities. Chorea was mild at rest and became more evident on action (Supplementary video, segment 1). Results of laboratory tests, including complete blood cell counts and serum electrolyte levels, and liver function were normal. Antinuclear antibodies, lupus anticoagulant activity, and anti-cardiolipin antibodies were absent. Brain MRI with fluid-attenuated inversion recovery (FLAIR) imaging showed no ischemic lesions in the basal ganglia, bilateral corona radiata, or cerebral cortices (Fig. 1A–C). His three-dimensional CT angiogram showed severe stenosis (95%) of his right ICA (Fig. 1D, E). His cerebral blood flow detected by ^{123}I -N-isopropyl-4-iodoamphetamine (^{123}I -IMP) single-photon emission computed tomography (SPECT) was markedly decreased in the right ICA territory including the caudate nucleus (Fig. 1F). Because the ICA stenosis on the right side was significant, carotid endarterectomy (CEA) was performed two months after the onset of symptoms, which was successful. One week later, choreic movements of his foot had improved but mild chorea of his hand still remained (supplementary video, segment 2). His ^{123}I -IMP SPECT showed an improvement of cerebral perfusion in the right middle cerebral artery (MCA) territory (Fig. 1G). Six months after the CEA, choreic

movements of his left hand occurred intermittently in the absence of new cerebral infarction on MR images (not shown); the patient remained on clopidogrel treatment at 75 mg/day with no antichoreic agents throughout.

Recently, there have been several cases of patients who developed transient or recurrent hemichorea, suggesting a transient ischemic attack, which can be a consequence of carotid or MCA stenosis [2–5]. Interestingly, our patient developed persistent, rather than transient, hemichorea secondary to contralateral ICA stenosis, consistent with previous reports [6–10].

Hemichorea can be associated with lesions involving the caudate nucleus, putamen, thalamus, subthalamic nucleus, subcortical white matter, and cerebral cortex, which are involved in the cortico-striato-pallido-thalamo-cortical feedback loop [1]. The infarcts in the patients reported by Morigaki et al. were located in the anterior watershed and in the frontal centrum semiovale and basal ganglia, which are regions considered to lie within the anterior watershed [6]. In the patients examined by Kim et al., acute infarcts were located in the anterior watershed region in which carotid stenosis may lead to the most severe reduction in cerebral blood flow [9]. On the basis of these findings, they suggested that subcortical lesions interfere with neuronal connections between the basal ganglia and the cerebral cortex, which results in hemichorea. Pareés et al. [8] and Irioka et al. [10] showed that impaired cerebral blood flow in the basal ganglia and thalamus is the main factor contributing to the choreic movements in their patients. In our patient, ^{123}I -IMP SPECT revealed hypoperfusion in the right hemisphere including the caudate nucleus, although no underlying structural lesion was found on brain MRI. Furthermore, the symptoms and hypoperfusion improved after carotid revascularization. We think that the hemodynamic ischemia in his right basal ganglia-thalamocortical circuits was the underlying cause of his hemichorea.

The clinical course of our patient was favorable and consistent with previous reports [6–10]. However, the time to improvement of their hemichorea after revascularization differed. In one patient, reported by Galea et al., the duration between the onset of chorea and surgery was within 3 months, and chorea improved within 2 weeks [7]. On the other hand, the choreic movements of the patient presented by Pareés et al. gradually subsided over three months after revascularization, although the duration of chorea before surgery was two months [8]. Moreover, patients who had the same duration of chorea before surgery showed choreic movements that persisted for 11 to 24 months [6, 10]. In our patient, his choreic movements improved after revascularization, but intermittently occurred in his left hand six months after the surgery. We hypothesize that several factors, such as age, cerebral collateral circulation, and aberrant neuronal plasticity after the initial hypoperfusion in his right basal ganglia-thalamocortical circuits, may affect recovery time. Further study is required to determine the pathophysiology of choreic movements caused by carotid artery stenosis.

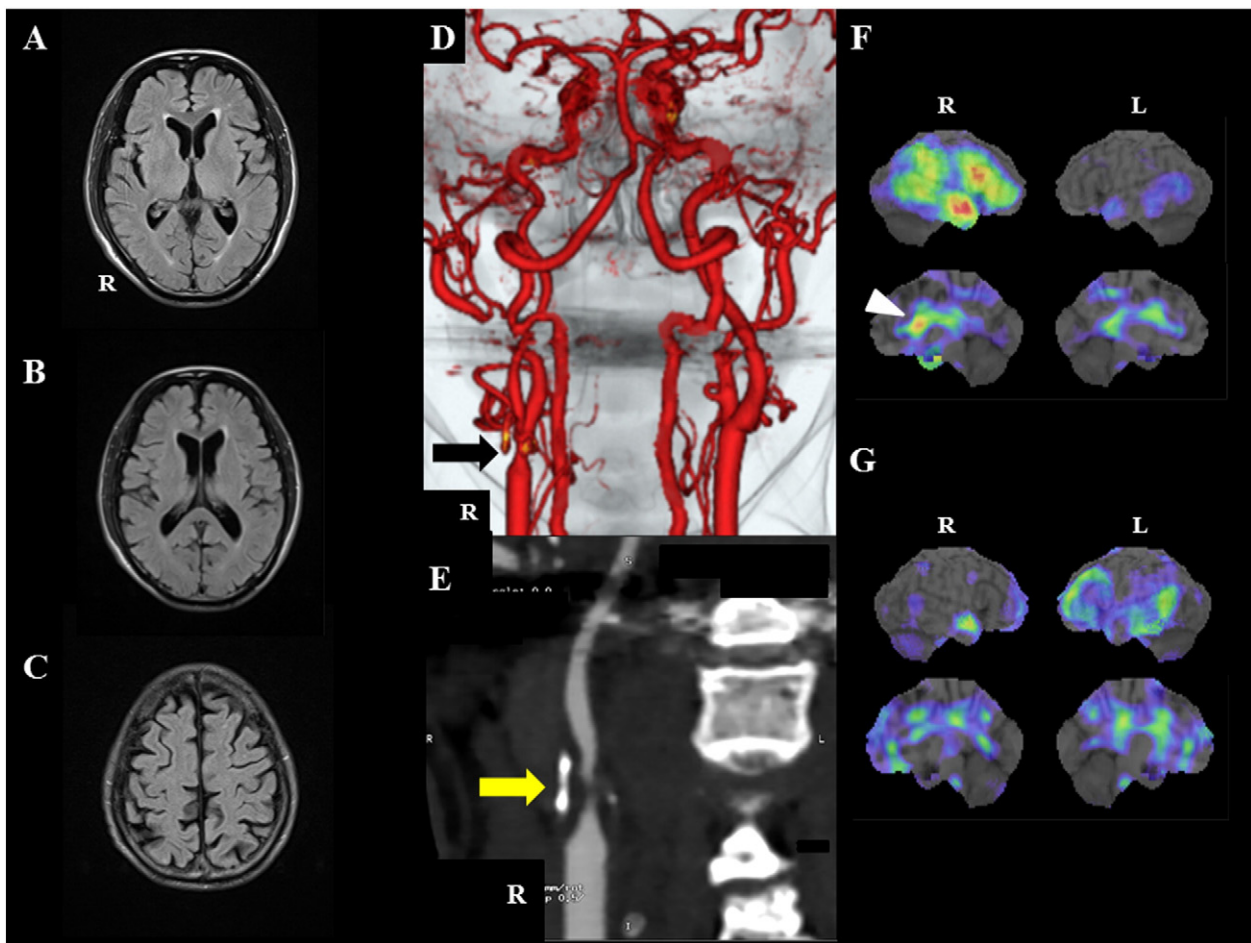


Fig. 1. (A–C) Axial fluid-attenuated inversion recovery images showing no ischemic lesions in basal ganglia, subcortical white matter and cerebral cortices. (D and E) Computed tomography angiography (CTA) images showing severe stenosis of the right internal carotid artery (arrows). (F) Preoperative ^{123}I -IMP SPECT images showing hypoperfusion in right hemisphere including the caudate (arrowhead). (G) Postoperative ^{123}I -IMP SPECT images showing improvement of perfusion in previously affected areas.

In conclusion, detailed vascular investigations of patients with hemichorea should be carried out to enable the early detection of carotid disease and prevention of subsequent ischemic event, despite of normal structural neuroimaging.

Supplementary data to this article can be found online at doi:10.1016/j.jns.2016.10.019.

Conflict of interest

The authors declare that they have no competing interests.

Patient consent

The authors obtained the informed consent of the patient for publication including the videos.

References

- [1] F. Cardoso, K. Seppi, K.J. Mair, et al., Seminar on choreas, *Lancet Neurol.* 5 (2006) 589–602.
- [2] J.M. Kim, J.S. Kim, A.H. Cho, et al., Angioplasty of middle cerebral artery stenosis improves recurrent hemichorea caused by basal ganglia hypoperfusion, *J. Stroke Cerebrovasc. Dis.* 15 (2006) 69–71.
- [3] G.S. Carmen, A.E. Lang, Paroxysmal hemiballism/hemichorea resulting from transient ischemic attacks, *Mov. Disord. Clin. Pract.* (2015) <http://dx.doi.org/10.1002/mdc3.12268>.
- [4] K. Noda, S. Nakajima, F. Sasaki, et al., Middle cerebral artery occlusion presenting as upper limb monochorea, *J. Stroke Cerebrovasc. Dis.* 24 (2015) e291–e293.
- [5] J.V. Alonso, F.J. Del Pozo, J.C. Simón, et al., Limb-shaking TIA presenting as hemichorea-hemiballismus: TIA chameleons diagnostic challenge in the emergency department, *J. Stroke Cerebrovasc. Dis.* 24 (2015) e327–e331.
- [6] R. Morigaki, M. Uno, A. Suzue, et al., Hemichorea due to hemodynamic ischemia associated with extracranial carotid artery stenosis. Report of two cases, *J. Neurosurg.* 105 (2006) 142–147.
- [7] I. Galea, F. Norwood, M.J. Phillips, et al., Pearls and oysters: resolution of hemichorea following endarterectomy for severe carotid stenosis, *Neurology* 71 (2008) e80–e82.
- [8] I. Pareés, F. Pujadas, J. Hernández-Vara, et al., Reversible hemichorea associated with extracranial carotid artery stenosis, *J. Neurol. Sci.* 300 (2011) 185–186.
- [9] D.W. Kim, Y. Ko, S.H. Jang, et al., Acute hemichorea as an unusual presentation of internal carotid artery stenosis, *J. Mov. Disord.* 6 (2013) 17–20.
- [10] T. Irioka, J. Ayabe, H. Mizusawa, Hemichorea improved by extracranial-intracranial bypass surgery for middle cerebral artery occlusion, *J. Neurol.* 257 (2010) 1756–1758.

Kazuyuki Noda

Department of Neurology, Juntendo University Shizuoka Hospital, 1129 Nagaoka, Izunokuni, Shizuoka 410-2295, Japan

Corresponding author.

E-mail address: k-noda@juntendo.ac.jp

Reo Ishimoto

Department of Neurosurgery, Juntendo University Shizuoka Hospital, 1129 Nagaoka, Izunokuni, Shizuoka 410-2295, Japan

Nobutaka Hattori

Department of Neurology, Juntendo University School of Medicine, 2-1-1 Hongo, Bunkyo, Tokyo 113-8421, Japan

Yasuyuki Okuma

*Department of Neurology, Juntendo University Shizuoka Hospital, 1129
Nagaoka, Izunokuni, Shizuoka 410-2295, Japan*

Takuji Yamamoto

*Department of Neurosurgery, Juntendo University Shizuoka Hospital, 1129
Nagaoka, Izunokuni, Shizuoka 410-2295, Japan*

9 August 2016