

# Accepted Manuscript

Coiling of a ruptured large internal carotid aneurysm via extracranial-intracranial saphenous vein bypass graft just after proximal ligation of the internal carotid artery

Hayato Tajima, MD, Yoshio Araki, MD, PhD, Takashi Izumi, MD, PhD, Masahiro Nishihori, MD, Sho Okamoto, MD, PhD, Toshihiko Wakabayashi, MD, PhD

PII: S1878-8750(16)31214-1

DOI: [10.1016/j.wneu.2016.11.066](https://doi.org/10.1016/j.wneu.2016.11.066)

Reference: WNEU 4876

To appear in: *World Neurosurgery*


Received Date: 15 August 2016

Revised Date: 11 November 2016

Accepted Date: 12 November 2016

Please cite this article as: Tajima H, Araki Y, Izumi T, Nishihori M, Okamoto S, Wakabayashi T, Coiling of a ruptured large internal carotid aneurysm via extracranial-intracranial saphenous vein bypass graft just after proximal ligation of the internal carotid artery, *World Neurosurgery* (2016), doi: 10.1016/j.wneu.2016.11.066.

This is a PDF file of an unedited manuscript that has been accepted for publication. As a service to our customers we are providing this early version of the manuscript. The manuscript will undergo copyediting, typesetting, and review of the resulting proof before it is published in its final form. Please note that during the production process errors may be discovered which could affect the content, and all legal disclaimers that apply to the journal pertain.



**Coiling of a ruptured large internal carotid aneurysm via extracranial-intracranial saphenous vein bypass graft just after proximal ligation of the internal carotid artery**

Hayato Tajima, Yoshio Araki, Takashi Izumi, Masahiro Nishihori, Sho Okamoto, Toshihiko Wakabayashi

Department of Neurosurgery, Nagoya University, Graduate School of Medicine

**Corresponding author:**

Yoshio Araki, MD, PhD

Department of Neurosurgery, Nagoya University, Graduate School of Medicine, 65

Tsurumai-cho, Showa-ku, Nagoya, Aichi 466-8550, Japan

E-mail: [y.araki@med.nagoya-u.ac.jp](mailto:y.araki@med.nagoya-u.ac.jp)

Phone: +81-52-744-2353

Fax: +81-52-744-2360

**Author degrees:** Hayato Tajima, MD, Yoshio Araki, MD, PhD, Takashi Izumi, MD, PhD,

Masahiro Nishihori, MD, Sho Okamoto, MD, PhD, Toshihiko Wakabayashi, MD, PhD

**Key words:** Coiling, Extracranial-intracranial bypass, Internal carotid aneurysm

ACCEPTED MANUSCRIPT

**ABSTRACT**

**Background:** Direct and endovascular combined surgery has been performed to treat large to giant internal carotid artery (ICA) aneurysms. This report describes successful treatment of the large ICA aneurysm by coiling of the aneurysm via extracranial-intracranial (EC-IC) saphenous vein graft (SVG) just after bypass and ICA proximal ligation. **Case Description:**

A 66-year-old woman presented with left ICA supraclinoid aneurysm with progressive visual field defect and impaired visual acuity in the left eye. While waiting for scheduled surgery, she suffered subarachnoid hemorrhage. EC-IC high-flow bypass using SVG and proximal ligation of the ICA were performed. Coiling of the aneurysm was immediately successfully performed via the SV bypass graft. The patient experienced no new neurological deficit after this treatment. Magnetic resonance imaging and magnetic resonance angiography as follow-up radiological evaluations revealed complete aneurysm occlusion. **Conclusions:** Aneurysm coiling via EC-IC SV bypass graft could offer an alternative when an antegrade access route to the ICA is not utilized due to prior parent artery ligation.

## INTRODUCTION

Treatment of large to giant aneurysms by clipping or coiling alone is challenging. The effectiveness of direct and endovascular combined surgery has thus been emphasized.<sup>1,2</sup> In particular, use of a hybrid operative/endovascular operation room allows performance of simultaneous procedures comprising bypass surgery and catheter intervention.<sup>3</sup> However hybrid operation room is unutilized, the other strategies are warranted. This report describes the successful treatment of a large internal carotid artery (ICA) aneurysm by coil embolization of the aneurysm via extracranial-intracranial (EC-IC) saphenous vein graft (SVG) just after ICA proximal ligation.

## CASE PRESENTATION

A 66-year-old woman presented with a 1-year history of visual field defects and impaired visual acuity in the left eye. Magnetic resonance imaging (MRI) and magnetic resonance angiography (MRA) revealed a left supraclinoid aneurysm measuring 19.7 mm in maximum diameter, compressing and displacing the left optic nerve upward. Digital-subtraction angiography revealed the aneurysmal orifice located between the left ophthalmic artery and posterior communicating artery (PcomA). The left PcomA was a fetal-type which ran along the aneurysmal wall (Fig. 1. A), indicating the importance of its preservation during surgery.

The anterior communicating artery and left first segment of the posterior cerebral artery (P1) were hypoplastic.

Preoperatively, a balloon occlusion test was performed for 20 min to check tolerance against left ICA permanent occlusion. Right hemiparesis and aphasia subsequently appeared and were judged as representing intolerance. We therefore decided to perform EC-IC high-flow bypass and parent artery occlusion according to our established strategy.<sup>4</sup>

The patient suffered mild subarachnoid hemorrhage while waiting for the scheduled operation. First, external carotid artery (ECA)-SVG-second segment of the middle cerebral artery bypass was performed with the usual end-to-side fashion. PcomA was a fetal type and the left P1 was hypoplastic, so PcomA could not be sacrificed. The PcomA also ran along the aneurysm with severe adhesions (Fig. 1. A), meaning that dissection of the PcomA was needed to interact with the aneurysm. To avoid intraprocedural aneurysmal re-rupture, dissection of the PcomA from the aneurysmal wall was abandoned. The treatment strategy was then changed to surgical proximal ligation of the ICA to reduce aneurysmal flow and coiling of the aneurysm, including the parent artery, for complete aneurysmal occlusion just after the direct surgery. Before endovascular surgery, antiplatelet loading was performed with acetylsalicylic acid (200 mg). Heparin was intravenously administered in a bolus of 3000 IU and intermittently during the procedure to maintain activated clotting time at >200 s. A 6-Fr Envoy guiding catheter (Johnson & Johnson, Miami, FL) supported by a 6-Fr

Shuttle Sheath (Cook Medical, Bloomington, IN) was navigated into the left common carotid artery through right femoral artery access. Carotid angiography showed retrograde flow into the aneurysm via the SVG (Fig. 1. B). A Headway 17 advanced microcatheter (MicroVention; TERUMO, Tustin, CA) was guided through the SVG over a CHIKAI guidewire (Asahi Intecc, Aichi, Japan) (Fig. 1. C). The aneurysm was embolized using 17 detachable coils (DELTAMAXX; Johnson & Johnson, Miami, FL) until retrograde filling disappeared, and retrograde PcomA flow was preserved (Fig. 1. D). Postoperatively, although transient left oculomotor nerve palsy and right hemiparesis appeared for 1 week, these findings disappeared. Three months after the procedure, the patient visited our outpatient clinic and showed no neurological deficits. MRI and MRA showed no recurrence of the aneurysm.

## **DISCUSSION**

In this ruptured aneurysm case, we have not adopted a treatment strategy of partial coil embolization, stent assisted coil embolization and flow diverting stent placement. It is not technically difficult to treat with partial coil embolization of the aneurysm. However, we had considered that this strategy for ruptured broad neck aneurysm might not to avoid rebleeding for insufficient intra-aneurysmal flow reduction. In addition, for the stent placement technique, dual antiplatelet therapy is generally recommended to avoid thrombus formation

and stent occlusion. We have considered that dual antiplatelet therapy might increase the risk of rebleeding and single antiplatelet therapy with stent placement might induce thrombo-embolic complications in case of ruptured aneurysm. Basically, the strategy to treat with flow diversion stenting alone for ruptured aneurysm was not efficient to immediate flow obliteration. Because flow diversion stenting immediately could not disappear the flow of the aneurysm. It was reported that the complete occlusion rates were 80% at 4-6 months, and 100% at 7-12 months.<sup>5</sup> On the other hand, for maximal flow reduction of the aneurysm without endovascular treatment, proximal carotid ligation and clipping of distal to the aneurysm were reasonable. However, tight adhesion between aneurysmal dome and PComA made difficult to dissect technically. So, intraoperatively, we concerned that forceful dissection might induce aneurysmal tear and re-rupture of the aneurysm. Therefore, we performed EC-IC high flow bypass with endovascular internal trapping of the aneurysm. EC-IC high-flow bypass with endovascular internal trapping is a widely known treatment for ICA large to giant aneurysm.<sup>6,7</sup> However, if retrograde filling of the aneurysm remains, complications such as embolism, regrowth and re-rupture of the aneurysm may occur.<sup>8-12</sup> Additional coil embolization through the bypass graft to prevent these complications has recently been reported (Table 1).<sup>13-17</sup> In four of the five cases, retrograde blood flow from the bypass graft to the aneurysm remained and the aneurysm was enlarged. In one of the five cases, the aneurysm was closed using coils after performing the bypass to avoid possible



rupture of the lesion resulting from the increased intra-aneurysmal pressure that develops after EC-IC bypass. All cases underwent additional treatment in the chronic phase. Frederick et al.<sup>18</sup> proposed the following mechanisms of aneurysmal rupture. 1) Even if the flow and arterial pressure seemed faint, intra-aneurysmal flow direction could have been redirected to part of the dome where the wall was weak. 2) Enlargement of the aneurysm by acute luminal clot could have led to stretching of the aneurysm wall. Accordingly, we thought the possibility of re-rupture was higher in ruptured cases than in unruptured case. We therefore performed coil embolization just after direct surgery to prevent aneurysmal re-rupture.

Ezura et al.<sup>19</sup> reported that proximal occlusion may not produce complete thrombosis of the aneurysm and a risk of microemboli from the intra-aneurysmal thrombus to the distal ICA remains. We considered that additional coil embolization including the parent artery was efficient for preventing that complication.

Using heparin just after craniotomy encourages intracranial hemorrhage.<sup>20</sup> On the other hand, heparin is needed to prevent embolization during endovascular therapy. In this case, we could avoid intracranial hemorrhage with close hemostasis at direct surgery.

One concern is that the bypass graft may be perforated during catheter manipulation. Tokugawa et al.<sup>16</sup> stated that endovascular therapy should be performed with extreme care, particularly when a catheter passes the anastomotic site.

**CONCLUSION**

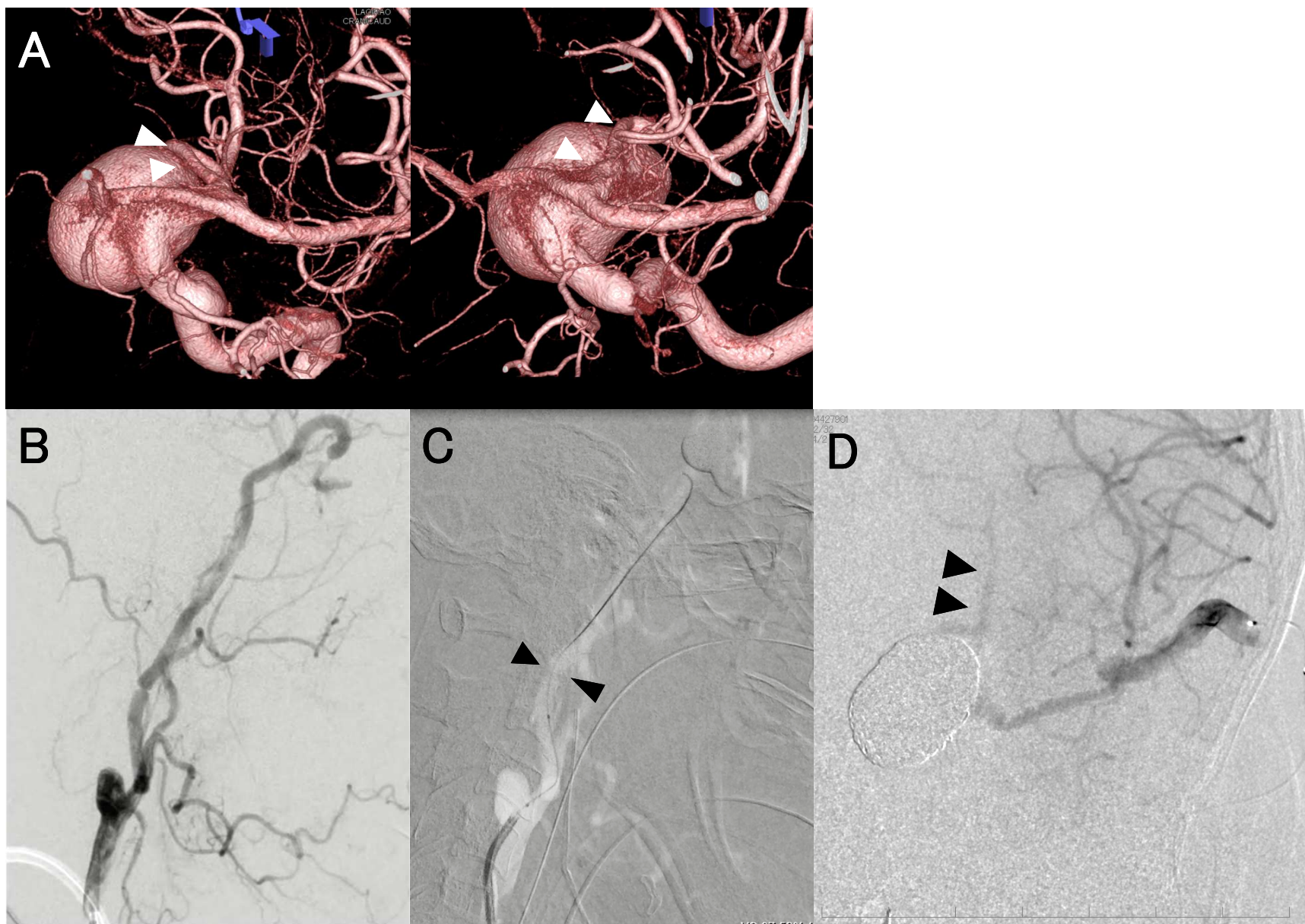
In cases where the antegrade access route is not utilized for complete trapping of the ruptured aneurysm, coil embolization via bypass graft could offer an alternative strategy.

**REFERENCES**

1. Serbinenko FA, Filatov JM, Spallone A, et al. Management of giant intracranial ICA aneurysms with combined extracranial-intracranial anastomosis and endovascular occlusion. *J Neurosurg.* 1990;73:57-63.
2. Hoh BL, Carter BS, Budzik RF, et al. Results after surgical and endovascular treatment of paraclinoid aneurysms by a combined neurovascular team. *Neurosurgery.* 2001;48:78-90.
3. Nakajima N, Nagahiro S, Satomi J, et al. Prevention of retrograde blood flow into large or giant internal carotid artery aneurysms by endovascular coil embolization with high-flow bypass: surgical technique and long-term results. *World Neurosurg.* 2015;83:1127-1134.
4. Uozumi Y, Okamoto S, Araki Y, et al. Treatment of symptomatic bilateral cavernous carotid aneurysms: long-term results of 6 cases. *J Stroke Cerebrovasc Dis.* 2015;24:1013-1018.
5. Kocer N, Islak C, Kizilkilic O, et al. Flow Re-direction Endoluminal Device in treatment of cerebral aneurysms: initial experience with short-term follow-up results. *J Neurosurg.* 2014;120:1158-1171.
6. Zhu W, Tian YL, Zhou LF, et al. Treatment strategies for complex internal carotid artery (ICA) aneurysms: direct ICA sacrifice or combined with extracranial-to-intracranial

- bypass. *World Neurosurg.* 2011;75:476-484.
7. Ishishita Y, Tanikawa R, Noda K, et al. Universal extracranial-intracranial graft bypass for large or giant internal carotid aneurysms: techniques and results in 38 consecutive patients. *World Neurosurg.* 2014;82:130-139.
  8. Kai Y, Hamada J, Morioka M, et al. Treatment strategy for giant aneurysms in the cavernous portion of the internal carotid artery. *World Neurosurg.* 2007;67:148-155.
  9. O'Shaughnessy BA, Salehi SA, Mindea SA, et al. Selective cerebral revascularization as an adjunct in the treatment of giant anterior circulation aneurysms. *Neurosurg Focus.* 2003;14:1-8.
  10. Lee HJ, Suh SH, Lee JW, et al. Intra-mural propagation of a large cavernous internal cerebral artery aneurysm after parent artery sacrifice. *Acta Neurochir (Wien).* 2009;151:389-392.
  11. Matsuda M, Shiino A, Handa J. Rupture of previously unruptured giant carotid aneurysm after superficial temporal-middle cerebral artery bypass and internal carotid occlusion. *Neurosurgery.* 1985;16:177-184.
  12. Anson JA, Stone JL, Crowell RM. Rupture of a giant carotid aneurysm after extracranial-to-intracranial bypass surgery. *Neurosurgery.* 1991;28:142-147.
  13. Santoro A, Passacantilli E, Guidetti G, et al. Bypass combined with embolization via a venous graft in a patient with a giant aneurysm in the posterior communicating artery and

- bilateral idiopathic occlusion of the internal carotid artery in the neck. *J Neurosurg.* 2002;96:135-139.
14. Zomorodi A, Bulsara KR, Friedman AH, et al. Combined microsurgical and endovascular treatment of a giant left middle cerebral artery aneurysm. *J Neurointerv Surg.* 2010;2:213-216.
15. Pandey P, Rayes M, Hong D, et al. Endovascular management of a giant aneurysm through saphenous vein graft after extracranial-intracranial bypass: case report and literature review. *J Neurointerv Surg.* 2011;3:361-363.
16. Tokugawa J, Yoshida K, Yamamoto M, et al. Large aneurysm in a nonbifurcating cervical carotid artery: an aneurysm associated with a rare anomaly treated with radial artery graft bypass: case report. *Neurosurgery.* 2011;68:250-253.
17. Guilfoyle MR, Kirkpatrick PJ, Higgins JN, et al. Coiling of a residual internal carotid artery aneurysm via an extracranial-intracranial bypass graft following parent vessel occlusion. *Br J Neurosurg.* 2012;26:759-762.
18. Vincent F, Weill A, Roy D, et al. Carotid ophthalmic aneurysm rupture after parent vessel occlusion. *AJNR Am J Neuroradiol.* 2005;26:1372-1374.
19. Ezura M, Takahashi A, Yoshimoto T. Combined intravascular parent artery and ophthalmic artery occlusion for giant aneurysms of the supraclinoid internal carotid artery. *Surg Neurol.* 1997;47:360-363.



**Highlights**

- A 66-year-old woman presented with ICA aneurysm with visual symptoms was treated.
- Coiling of the aneurysm was successfully performed via the SV bypass graft.
- EC-IC SV bypass graft could offer an alternative access route.

**Abbreviations:**

ECA: external carotid artery

EC-IC: extracranial-intracranial

ICA: internal carotid artery

MRI: Magnetic resonance imaging

MRA: Magnetic resonance angiography

PcomA: posterior communicating artery

SVG: saphenous vein graft