


Internal Carotid Artery Pseudoaneurysm and Ischemic Stroke Secondary to Retropharyngeal and Parapharyngeal Abscess: A Case Report and Review of the Literature

Journal of Child Neurology
1-7
© The Author(s) 2016
Reprints and permission:
sagepub.com/journalsPermissions.nav
DOI: 10.1177/0883073816678556
jcn.sagepub.com


Michael W. Ruff, MD¹, Deena M. Nasr, DO¹, James P. Klaas, MD¹,
and Deborah L. Renaud, MD^{1,2}

Abstract

Internal carotid artery pseudoaneurysm is an uncommon complication of retropharyngeal and parapharyngeal abscess in children. Treatment of the pseudoaneurysm has evolved in recent years from surgical ligation to endovascular techniques. Neurologic sequelae most commonly consist of Horner's syndrome with cerebral ischemia being uncommon. The clinical course of a 2-year-old boy with retropharyngeal abscess complicated by internal carotid artery pseudoaneurysm, is described and the literature is reviewed. A conventional angiogram confirmed the presence of a large pseudoaneurysm with no anterograde flow distal to the pseudoaneurysm and substantial collateral flow across the circle of Willis, with filling of the left anterior and middle cerebral arteries via the anterior and posterior communicating arteries. Endovascular occlusion resulted in nonfilling of the left internal carotid artery, pseudoaneurysm, and left internal jugular vein at the base of the skull. Following the procedure, the patient developed transient mild right hemiparesis associated with frontal lobe ischemia.

Keywords

acute ischemic stroke, endovascular coiling, internal carotid artery, pseudoaneurysm, retropharyngeal abscess

Received July 19, 2016. Received revised August 26, 2016. Accepted for publication September 30, 2016.

Internal carotid artery pseudoaneurysm is an uncommon complication of retropharyngeal and parapharyngeal abscess in children. Unlike a true aneurysm, which is a dilation of the artery involving all layers of the vessel wall, the walls of a pseudoaneurysm consist of adventitia, periarterial fibrous tissue, and hematoma. The encapsulated hematoma communicates with the lumen of the vessel as a result of damage to one or more layers of the arterial wall. Ongoing enlargement of the pseudoaneurysm results in a pulsatile hematoma, which may result in clot propagation and embolization or hemorrhage. Treatment of the abscess may include antibiotics and drainage of the abscess; however, specific treatment of the pseudoaneurysm is also required in order to prevent hemorrhage and other sequelae. Treatment of the pseudoaneurysm has evolved in recent years from surgical ligation to endovascular techniques. Neurologic sequelae most commonly consist of Horner's syndrome, with cerebral ischemia being uncommon.

The clinical course of a 2-year-old boy internal carotid artery pseudoaneurysm, associated with retropharyngeal abscess, complicated by ischemic cerebral infarction is described and the previously reported cases are reviewed.

Case

A 2-year-old boy with a history of tonsillectomy and bilateral tympanostomy, several months prior, developed 2 days of nausea and vomiting followed by sore throat with neck stiffness, decreased oral intake, irritability, and increased drooling. His parents noted decreased hand coordination. He presented to medical attention 3 days after the onset of symptoms. At presentation, he was found to have a temperature of 38.0°C, leukocytosis of $24\,000 \times 10^9/L$ (normal 5-12), and a C-reactive protein of 138 mg/L (normal <8). His examination was significant for neck discomfort with movement and

¹ Department of Neurology, Mayo Clinic, Rochester, MN, USA

² Department of Pediatrics, Mayo Clinic, Rochester, MN, USA

Corresponding Author:

Deborah Renaud, MD, Division of Child and Adolescent Neurology,
Department of Neurology, Mayo Clinic 200 First Street SW Rochester,
MN 55905, USA.

Email: renaud.deborah@mayo.edu

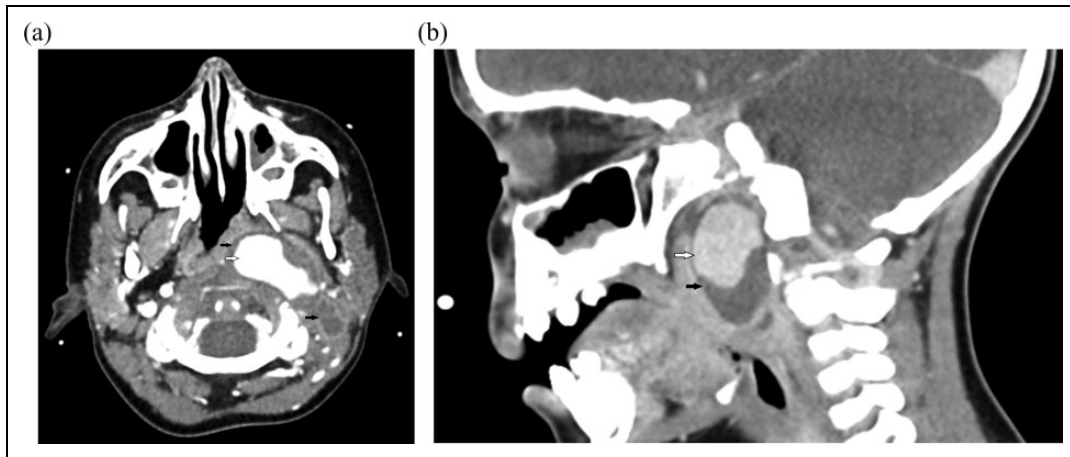


Figure 1. Axial (A) and sagittal (B) images of computed tomography with contrast revealing an internal carotid artery pseudoaneurysm (periarterial encapsulated hematoma) (white arrow) within the parapharyngeal and retropharyngeal abscess (black arrows) in a 2-year-old boy.

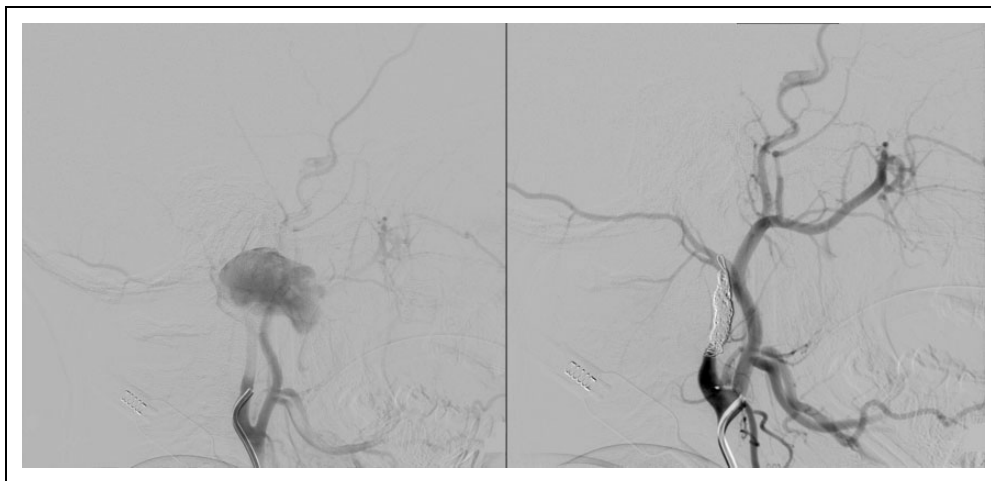


Figure 2. Conventional angiography images demonstrate a large left internal carotid artery pseudoaneurysm measuring 1.3×3.6 cm, with no anterograde flow distal to the pseudoaneurysm, pre (left) and post (right) internal carotid artery endovascular coiling.

pharyngeal erythema. The neurologic examination in the emergency room was documented as normal with no focal deficits. Coordination and hand strength were specifically documented as being normal. Broad-spectrum antimicrobials were started because of concern for meningitis or sepsis. A lumbar puncture obtained before administration of antimicrobials was negative and revealed colorless fluid with 0 nucleated cells/UL, 7 red blood cells/UL, protein of 11 mg/dL, glucose 76 mg/dL. Blood, urine, and cerebrospinal fluid cultures were negative. Both influenza swab and rapid streptococcal antigen testing was negative. However, throat cultures grew group A streptococcus. He was observed for 2 days and then discharged on oral cefdinir with a diagnosis of streptococcal pharyngitis. His C-reactive protein at discharge was 174 mg/L, after a peak value of 186 mg/L.

Following discharge, the patient's neck pain persisted and gradually worsened. He developed "muffled and gargled" speech and an antalgic gait. On reassessment, cervical adenopathy was noted on examination. The documented

examination did not specifically mention the speech or gait but noted "no focal deficits." Additional testing, including a Monospot and Epstein-Barr virus (EBV) titer, was negative. Repeat C-reactive protein and white blood cell count had normalized (1.10 mg/L and $9200 \times 10^9/L$, respectively). Observation was recommended.

He was reevaluated again 3 days later after developing reduced range of neck motion as a result of swelling at the base of his left jaw and anterior neck. He was sent to the nearest emergency department because of these clinical findings, where a computed tomography scan with contrast demonstrated a large retropharyngeal abscess and left internal carotid artery pseudoaneurysm (Figure 1).

The patient was emergently transferred to our institution. Upon arrival, a 4-vessel angiogram was performed. The left internal carotid artery injection confirmed the presence of a large pseudoaneurysm measuring $1.3 \text{ cm} \times 3.6$ with no anterograde flow distal to the pseudoaneurysm (Figure 2A). Injection of the right internal carotid artery and bilateral vertebral

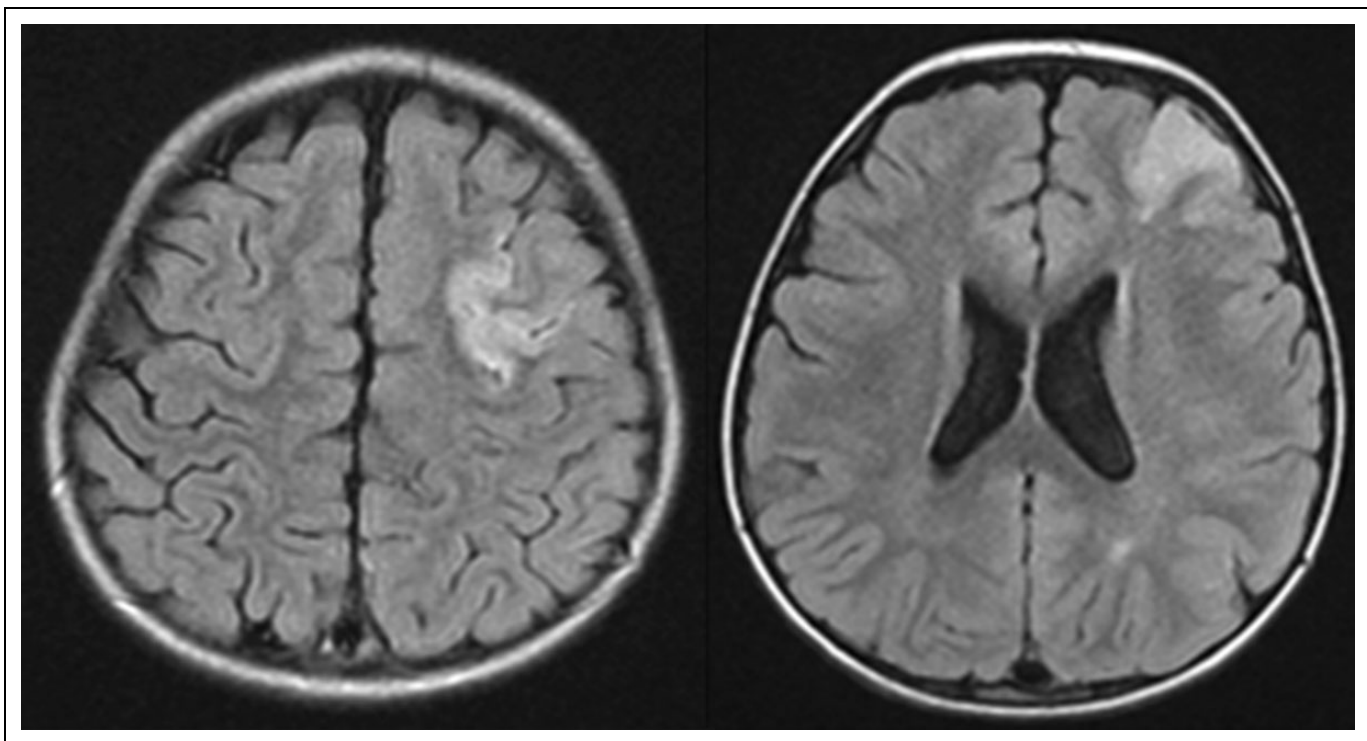


Figure 3. Magnetic resonance imaging (MRI) brain axial fluid-attenuated inversion recovery images demonstrate ischemic infarction in the left frontal and parietal regions.

arteries demonstrated substantial collateral flow across the circle of Willis, with filling of the left anterior and middle cerebral arteries via the anterior and posterior communicating arteries. Presumably as a result of the left internal carotid artery occlusion, the patient had established collateral flow, with the anterior cerebral circulation being provided by the right internal carotid artery and vertebral as well as intracranial collaterals including the artery of rotundum originating from the left external carotid artery.

In order to treat the pseudoaneurysm, and prevent clot propagation and distal embolization, the internal carotid artery was surgically occluded. This was done by placing platinum coils within the proximal left internal carotid artery between the carotid bifurcation and the pseudoaneurysm. Sacrificing the internal carotid artery was an option because the vessel was functionally occluded, and collateral flow had been established. An angiogram status post endovascular surgical occlusion demonstrated non-filling of the left internal carotid artery, pseudoaneurysm and left internal jugular vein at the base of the skull (Figure 2B). The retropharyngeal and parapharyngeal abscess remained unchanged in size. The patient's mean arterial blood pressure was measured by arterial catheter as 86-62 mmHg during the procedure.

Following the procedure, the patient was noted to have weakness of the right arm, though he appeared to move both legs without difficulty. Magnetic resonance imaging (MRI) demonstrated restricted diffusion in the left frontal lobe consistent with an acute/subacute ischemic infarct. There was also a small area of T2/fluid-attenuated inversion recovery

hyperintensity in the white matter of the left parietal lobe, which was also consistent with ischemic stroke (Figure 3). The location of the strokes was most suggestive of a watershed distribution infarction. The lesions may have occurred during the procedure; however, his parents did note clumsiness prior to his evaluation at our institution, which may have been secondary to a mild right upper extremity monoplegia. Unfortunately, his right arm was immobilized for the intravenous line prior to the procedure and therefore the exact timing of the right arm weakness cannot be definitively determined.

Broad-spectrum intravenous antibiotics were continued throughout hospitalization. On the seventh day of hospitalization (28 days after onset of symptoms), the patient underwent ultrasound-guided aspiration of the retropharyngeal abscess. The aspirated fluid was sterile. His C-reactive protein and white blood cell count were normal at time of hospital discharge, and his neurologic examination was improved.

Discussion

Infectious carotid pseudoaneurysm is an uncommon complication of deep neck infections. Although much more common in the preantibiotic era,¹ they are rarely encountered today. In adults, this may be a complication of dental infections or septic emboli from intravenous drug use, while in children it is more commonly seen in the setting of pharyngeal and retropharyngeal infections. Osler² initially felt that this was secondary to direct contiguous spread of the infection to the carotid artery sheath resulting in arteritis and erosion of all 3 layers of the

Table 1. All Cases of Extracranial Infectious Carotid Pseudoaneurysm in Pediatrics (<18 Years Old).^a

Author, year	Age/sex	Symptoms	Medical management of abscess	Treatment of pseudoaneurysm	Neurologic complication
Alexander et al, 1968 ⁵	a) 3 y/ F b) 4 y/ M	a) Pharyngomaxillary space abscess, peritonsillar abscess b) Neck swelling, sore throat, parotiditis, hematemesis	a) Drained: Yes Antibiotics : tetracycline for presumed mumps. b) Drained: yes. Antibiotics : achromycin and 2 injections of penicillin for presumed parotiditis Unknown	a) Surgical common carotid artery ligation b) Surgical internal carotid artery exploration and ligation	None
Garino and Ryan 1987 ³	15 y/M	Peritonsillar abscess, upper airway bleeding	None?	Surgical internal carotid artery ligation	None
Tovi et al, 1987 ⁶	14 y/F	Epistaxis, pharyngeal bleed	None?	Surgical internal carotid artery ligation with endovascular coil occlusion	None
Stevens, 1990 ⁷	15 y/M	Epistaxis, Group A streptococcal deep neck infection	Keflex, cefazolin, penicillin, cloxacillin	Endovascular internal carotid artery coil occlusion	CN X, XII palsy
Gonda et al, 1990 ⁸	18 mo/M	Neck mass, respiratory distress, strep throat	Antibiotics : oral penicillin failed. Penicillin and clindamycin IV × 10 d, continued oral 3 wk	Surgical external carotid artery ligation and resection	Horner syndrome
Watson et al, 1991 ⁹	7 y/M	Epistaxis, tonsillitis	Antibiotics : IV benzylpenicillin, failed oral antibiotics. Drainage: no	Surgical internal carotid artery ligation	None
Wells and Soy, 1991 ¹⁰	4 y/F	Dysphagia, cervical lymphadenitis	No drainage, no antibiotics mentioned	Surgical exploration	NA
Lueg et al, 1995 ¹¹	3 y/F	Dysphagia, bloody sputum	Cloxacillin preoperatively	Surgical common carotid artery ligation	None
Karas et al, 1997 ¹²	6 y/M	Posttonsillectomy hematemesis, 5-cm pulsatile mass	None	Surgical external carotid artery ligation	None
Willemssen et al, 1997 ¹³	9 y/M	ALL, neck mass, angioinvasive aspergillus infection	Drained, plus broad-spectrum antibiotics, then antifungal	Surgical common carotid artery ligation	Right vocal cord paralysis-resolved
Reisner et al, 1999 ¹⁴	16 y/F	Pulsatile neck mass, hemoptysis, deep neck space infection, pharyngitis, <i>Staphylococcus aureus</i>	Parapharyngeal abscess drained. Antibiotic treatment for 6 wk	Endovascular internal carotid artery coil occlusion	Horner syndrome-resolving
Ferguson et al, 2002 ¹⁵	8 y/M	Strep throat, neck pain, parapharyngeal abscess	IV antibiotics	Surgical external carotid artery ligation and endovascular internal carotid artery balloon occlusion	None
Glaiberman et al, 2003 ¹⁶	11 mo/M	Neck swelling, necrosis of third distal phalanx- strep A parapharyngeal abscess	IV antibiotics	Endovascular carotid artery balloon occlusion	None
Tannuri et al, 2003 ¹⁷	10 mo/NA	Left neck swelling: Retropharyngeal abscess 1 mo before, bruit	Broad-spectrum antibiotics for 10 d	Endovascular internal carotid artery coil occlusion and surgical drainage	None
Singh et al, 2003 ¹⁸	4 y/M	Trismus, dysphagia, face and neck swelling, parapharyngeal infection	Drained	Surgical common carotid artery ligation	Facial nerve palsy, resolved
Brochu et al, 2004 ¹⁹	6 y/F	Neck pains, dysphagia, dysphonia, parapharyngeal abscess	IV antibiotics for 6 wk and tonsillectomy	Endovascular internal carotid artery coil occlusion	Horner syndrome, vocal cord paralysis
Gralla et al, 2004 ²⁰	11 y/M	Epistaxis, pharyngeal hemorrhage	Not stated	Endovascular internal carotid artery stent exclusion	None
Mordekar et al, 2005 ²¹	8 y/F	Odynophagia, trismus, peritonsillar swelling	IV antibiotics for 4 wk	Endovascular internal carotid artery coil occlusion	None

(continued)

Table 1. (continued)

Author, year	Age/sex	Symptoms	Medical management of abscess	Treatment of pseudoaneurysm	Neurologic complication
Sample et al, 2005 ²²	15 y/M	Pulsatile neck mass, deep neck infection	Broad-spectrum antibiotics and amphotericin B	Endovascular internal carotid artery coil occlusion	None
Hoff et al, 2005 ²³	7 y/M	Posttonsillectomy hemorrhage 2 wk	Not stated	Endovascular internal carotid artery coil occlusion followed by surgical ligation	None
Pearson and Choi, 2005 ²⁴	4 y/F	Dysphonia, parapharyngeal infection	IV antibiotics for 3 wk Hematoma aspirated	Endovascular internal carotid artery coil occlusion	Deficits of IX-XII cranial nerves, vocal cord paralysis, Horner syndrome
DeFatta et al, 2005 ²⁵	8 y/F	Throat pain, peritonsillar abscess, neck swelling and pain	IV and oral antibiotics	Endovascular internal carotid artery coil occlusion	Horner syndrome, resolved
Meher et al, 2006 ²⁶	8 mo/M	Neck swelling, parapharyngeal and retropharyngeal space infection	Drained	Surgical internal carotid artery ligation	None
Beningfield et al, 2006 ²⁷	10 mo /NA	Decreased appetite, neck swelling, right retro- and parapharyngeal abscess	Drained	Endovascular internal carotid artery coil occlusion	None
Pourhassan et al, 2007 ²⁸	17 y/M	Tonsillitis s/p tonsillectomy 10 d prior, submandibular swelling, dysphagia	Oral antibiotics Not stated	Surgical external carotid artery ligation and resection	Transient dysphagia
Watanabe et al, 2009 ²⁹	15 y/NA	s/p BMT allogenic, otalgia, aspergillus	Drainage of middle ear and decompressed CN VII IV antibiotics, amphotericin B, and micafungin	Endovascular internal carotid artery coil occlusion	Hemorrhagic cerebral infarctions, right hemiplegia- resolved, persistent left facial nerve palsy (preprocedure)
Makeieff et al, 2010 ³⁰	16 y/F	Tonsillitis, retropharyngeal abscess,	Antibiotics	Endovascular internal carotid artery saccular coiling occlusion with covered stent	None
da Silva et al, 2011 ³¹	3 y/M	Epistaxis, deep neck space infection, peritonsillar abscess, cardiac arrest	Drained Antibiotics for 4 wk	Endovascular internal carotid artery balloon occlusion	Mild left hemiparesis (post procedure), resolved
Sankararaman et al, 2012 ³²	6 mo/F	Fever, pharyngitis, dysphagia, retropharyngeal abscess, neck mass	Drained IV antibiotics for 6 wk	Conservative	None
Requejo et al, 2013 ³³	4 y/M	Strep throat, pharyngitis, pulsatile neck mass	Not stated	No surgical or endovascular intervention Endovascular internal carotid artery stent occlusion	None
Current Case	2 y/M	Sore throat with neck stiffness, decreased oral intake, irritability, and increased drooling	Drained IV antibiotics	Endovascular internal carotid artery coil occlusion	Ischemic infarction with mild right hemiparesis resolved

Abbreviations: ALL, acute lymphoblastic leukemia; BMT, bone marrow transplant; CN, cranial nerve; IV, intravenous; NA, not available; s/p, Status post; strep, streptococcal.

^aExcluded cases: Age > 18 y, true internal carotid artery aneurysms, intracranial aneurysms, and traumatic or noninfectious pseudoaneurysms.

vessel wall. The extravasated blood is then contained within the surrounding fibrous tissues, creating a pseudoaneurysm or infectious aneurysm. The very limited descriptions of the pathology of infectious pseudoaneurysms throughout the body suggest an involvement of inflammation or direct injury to one or more layers of the vessel wall in the pathophysiology of pseudoaneurysm but have not definitively shown the presence of direct spread of the infection to the carotid artery sheath.

Missed or delayed diagnosis of this entity can result in devastating complications including septic cerebral emboli, carotid rupture and death. If untreated, infectious pseudoaneurysms have mortality rates of up to 77%.³ Treatment involves both antibiotic therapy for 4 to 6 weeks and either surgical ligation, resection, and grafting or endovascular occlusion of the affected vessel. Conservative management with antibiotics alone has not been favored because of the perceived risk of clot propagation and distal embolization and hemorrhage in untreated pseudoaneurysm. Although there are very limited data regarding endovascular occlusion, it is currently the favored method as it is felt to have less operative risk. Surgical internal carotid artery ligation has a reported mortality rate higher than 17%.⁴

The main risk of these procedures is a large ischemic stroke, necessitating delineation of collateral flow through the Circle of Willis prior to carotid sacrifice. In the endovascular approach, coils or balloons are placed proximal and distal to the pseudoaneurysm to exclude blood flow within the pseudoaneurysm. In our case, only the proximal occlusion with coils was performed. Distal occlusion was not felt to be required and would have been technically difficult, as the preoperative cerebral angiogram demonstrated no antegrade flow in past the pseudoaneurysm. Furthermore, contralateral internal carotid artery and vertebral artery injections demonstrated occlusion of the internal carotid artery immediately distal to the pseudoaneurysm.

In review of the literature, there are only 31 published pediatric cases of infectious extracranial carotid pseudoaneurysms described since 1968 in 30 case reports. The characteristics of the individual cases are summarized in Table 1. Previous cases have involved, on average, older patients than ours (range 6 months to 17 years, average age 14.1 years). Most previously reported cases have been male (18/31, 58%). The presentation of our case was in many ways similar to prior cases. Sore throat with pharyngitis was present in 15/31 patients. Dysphagia was mentioned in 10/31 cases and respiratory distress in 5/31. Hemorrhage during the disease course occurred in the majority (17/31) representing a serious, potentially fatal complication. An external neck mass, similar to our patient, was noted in 20/31 cases and intraoral mass was noted in 12/30. Prior tonsillectomy or tonsillitis was described in 9/31 cases although timing relative to the presentation was not consistently mentioned. Treatment of the retropharyngeal/parapharyngeal abscess included oral or intravenous antibiotics in 22/31 cases reported. Two cases did not receive antibiotics, and for 7 cases treatment of the abscess was not described. Eleven patients also had drainage of the abscess performed. Our patient received

both intravenous antibiotics and drainage of the retropharyngeal abscess.

The method for treating patients has evolved since the first case report in our cohort, as endovascular technology and techniques have progressed. The majority of recent cases have been performed with endovascular coils and stents. Of the 19 cases reported since the millennium, 12 cases have been entirely endovascular, 3 have been purely surgical, 3 have been a combined approach and 1 patient was treated conservatively with antibiotics and drainage of the retropharyngeal abscess. Endovascular coiling was planned in the latter patient but was not performed when a decrease in size of the pseudoaneurysm was observed with aggressive management of the abscess.

The majority of cases reported no neurologic sequelae (17/31, 55%). Horner's syndrome was the most common persistent neurologic deficit affecting 9/31 cases. Documented ischemic infarction, as seen in our case, is uncommon. Only 2 patients previously reported had hemiparesis (presumably secondary to infarction), which resolved. The right arm weakness seen in our patient also completely resolved. It was not possible to determine whether the infarctions noted on our patient's MRI occurred before the endovascular procedure or as a result of the procedure since the right arm had been immobilized for an intravenous line on admission to the hospital, prior to the procedure. The remaining deficits described in the literature included vocal cord paralysis, dysphagia, as well as hypoglossal, and facial nerve, palsies.

Internal carotid artery pseudoaneurysm is an uncommon but potentially life-threatening complication of retropharyngeal/parapharyngeal abscess in children. Appropriate imaging studies to evaluate for this complication is recommended.

Author Contributions

MR, DN, and DR were responsible for drafting and preparing the manuscript. JK provided critical review and editing. DR is the senior and corresponding author.

Declaration of Conflicting Interests

The authors declared no potential conflicts of interest with respect to the research, authorship, and/or publication of this article.

Funding

The authors received no financial support for the research, authorship, and/or publication of this article.

Ethical Approval

Requirement for informed consent was waived by the IRB given minimal risk to the subjects from retrospective review of records.

References

1. Salinger S, Pearlman S. Hemorrhage from pharyngeal and peritonsillar abscesses: report of cases, resume of the literature and discussion of ligation of the carotid artery. *Arch Otolaryngol.* 1933;18:464-509.
2. Osler W. The Gulstonian Lectures, on malignant endocarditis. *Br Med J.* 1885;1:577-579.

3. Garino JP, Ryan TJ. Carotid hemorrhage: a complication of peritonsillar abscess. *Am J Emerg Med.* 1987;5:220-223.
4. Knouse MC, Madeira RG, Celani VJ. *Pseudomonas aeruginosa* causing a right carotid artery mycotic aneurysm after a dental extraction procedure. *Mayo Clin Proc.* 2002;77:1125-1130.
5. Alexander DW, Leonard JR, Trail ML. Vascular complications of deep neck abscesses. A report of four cases. *Laryngoscope.* 1968;78:361-370.
6. Tovi F, Leiberman A, Hertzanu Y, Golcman L. Pseudoaneurysm of the internal carotid artery secondary to tonsillectomy. *Int J Pediatr Otorhinolaryngol.* 1987;13:69-75.
7. Stevens HE. Vascular complication of neck space infection: case report and literature review. *J Otolaryngol.* 1990;19:206-210.
8. Gonda RL Jr, Gutierrez OH, Hengerer AS, De Weese JA. Pharyngeal abscess with external carotid artery erosion and pseudoaneurysm. A combined radiologic and surgical management. *Pediatr Neurosurg.* 1990;16:21-24.
9. Watson MG, Robertson AS, Colquhoun IR. Pseudoaneurysm of the internal carotid artery: a forgotten complication of tonsillitis? *J Laryngol Otol.* 1991;105:588-590.
10. Wells RG, Sty JR. Cervical lymphadenitis complicated by mycotic carotid artery aneurysm. *Pediatr Radiol.* 1991;21:402-403.
11. Lueg EA, Awerbuck D, Forte V. Ligation of the common carotid artery for the management of a mycotic pseudoaneurysm of an extracranial internal carotid artery. A case report and review of the literature. *Int J Pediatr Otorhinolaryngol.* 1995;33:67-74.
12. Karas DE, Sawin RS, Sie KC. Pseudoaneurysm of the external carotid artery after tonsillectomy. A rare complication. *Arch Otolaryngol Head Neck Surg.* 1997;123:345-347.
13. Willemsen P, De Roover D, Kockx M, Gerard Y. Mycotic common carotid artery aneurysm in an immunosuppressed pediatric patient: case report. *J Vasc Surg.* 1997;25:784-785.
14. Reisner A, Marshall GS, Bryant K, Postel GC, Eberly SM. Endovascular occlusion of a carotid pseudoaneurysm complicating deep neck space infection in a child. Case report. *J Neurosurg.* 1999;91:510-514.
15. Ferguson DJ, Boyle JR, Millar J, Phillips MJ. Retrograde endovascular management of a mycotic internal carotid artery false aneurysm. *Eur J Vasc Endovasc Surg.* 2002;24:88-90.
16. Glaiberman CB, Towbin RB, Boal DK. Giant mycotic aneurysm of the internal carotid artery in a child: endovascular treatment. *Pediatr Radiol.* 2003;33:211-215.
17. Tannuri U, Mendes De Almeida N, Piske R, Matsumoto T. Giant pseudoaneurysm of the internal carotid artery causing upper airway obstruction in a 10-month-old infant treated by endovascular occlusion and surgical drainage. *J Pediatr Surg.* 2003;38:1393-1395.
18. Singh I, Meher R, Agarwal S, Raj A. Carotid artery erosion in a 4-year child. *Int J Pediatr Otorhinolaryngol.* 2003;67:995-998.
19. Brochu B, Dubois J, Garel L, Quintal MC, Roy D. Complications of ENT infections: pseudoaneurysm of the internal carotid artery. *Pediatr Radiol.* 2004;34:417-420.
20. Gralla J, Brekenfeld C, Schmidli J, Caversaccio M, Do DD, Schroth G. Internal carotid artery aneurysm with life-threatening hemorrhages in a pediatric patient: endovascular treatment options. *J Endovasc Ther.* 2004;11:734-738.
21. Mordekar SR, Bradley PJ, Whitehouse WP, Goddard AJ. Occult carotid pseudoaneurysm following streptococcal throat infection. *J Paediatr Child Health.* 2005;41:682-684.
22. Semple CW, Berkowitz RG, Mitchell PJ. Embolization of an extracranial internal carotid artery pseudoaneurysm. *Ann Otol Rhinol Laryngol.* 2005;114:90-94.
23. Hoff M, Graumuller S, Pau HW. Arterial aneurysms as cause of gushing post-tonsillectomy hemorrhage [in German]. *Laryngorhinootologie.* 2005;84:680-682.
24. Pearson SE, Choi SS. Pseudoaneurysm of the internal carotid artery: a case report and review of the literature. *Arch Otolaryngol Head Neck Surg.* 2005;131:454-456.
25. DeFatta RJ, Verret DJ, Bauer P. Extracranial internal carotid artery pseudoaneurysm. *Int J Pediatr Otorhinolaryngol.* 2005;69:1135-1139.
26. Meher R, Garg A, Malhotra V, Singh I. Pseudoaneurysm of the internal carotid artery in an infant aged 8 months. *N Z Med J.* 2006;119:U1815.
27. Beningfield A, Nehus E, Chen AY, Yellin S. Pseudoaneurysm of the internal carotid artery after retropharyngeal abscess. *Otolaryngol Head Neck Surg.* 2006;134:338-339.
28. Pourhassan S, Grottemeyer D, Fokou M, et al. Extracranial carotid arteries aneurysms in children: single-center experiences in 4 patients and review of the literature. *J Pediatr Surg.* 2007;42:1961-1968.
29. Watanabe T, Okada T, Okada C, et al. An aspergillotic aneurysm of the internal carotid artery following allogeneic bone marrow transplantation: successful management with catheter coil embolization and long-term antifungal agents. *Transpl Infect Dis.* 2009;11:49-53.
30. Makeieff M, Pelliccia P, Mondain M, Machi P. Pseudoaneurysm of the internal carotid artery complicating deep neck space infection. *J Pediatr.* 2010;157:510.
31. da Silva PS, Waisberg DR. Internal carotid artery pseudoaneurysm with life-threatening epistaxis as a complication of deep neck space infection. *Pediatr Emerg Care.* 2011;27:422-424.
32. Sankararaman S, Velayuthan S, Gonzalez-Toledo E. Internal carotid artery stenosis as the sequela of a pseudoaneurysm after methicillin-resistant *Staphylococcus aureus* infection. *Pediatr Neurol.* 2012;47:312-314.
33. Requejo F, Sierre S, Lipsich J, Zuccaro G. Endovascular treatment of post-pharyngitis internal carotid artery pseudoaneurysm with a covered stent in a child: a case report. *Childs Nerv Syst.* 2013;29:1369-1373.