


Accepted Manuscript

Small unruptured intracranial aneurysm ($\leq 5\text{mm}$) associated with epilepsy: report of 2 cases and literature review

Fuxin Lin, M.D., Hui Wan, M.D., Dezhi Kang, MD., Yuanxiang Lin, M.D.



PII: S1878-8750(16)31218-9

DOI: [10.1016/j.wneu.2016.11.070](https://doi.org/10.1016/j.wneu.2016.11.070)

Reference: WNEU 4880

To appear in: *World Neurosurgery*

Received Date: 15 September 2016

Revised Date: 13 November 2016

Accepted Date: 15 November 2016

Please cite this article as: Lin F, Wan H, Kang D, Lin Y, Small unruptured intracranial aneurysm ($\leq 5\text{mm}$) associated with epilepsy: report of 2 cases and literature review, *World Neurosurgery* (2016), doi: 10.1016/j.wneu.2016.11.070.

This is a PDF file of an unedited manuscript that has been accepted for publication. As a service to our customers we are providing this early version of the manuscript. The manuscript will undergo copyediting, typesetting, and review of the resulting proof before it is published in its final form. Please note that during the production process errors may be discovered which could affect the content, and all legal disclaimers that apply to the journal pertain.

Abstract:

Background: Due to the continuing improvements in imaging technology, an increasing number of epileptogenic small ($\leq 5\text{mm}$) unruptured intracranial aneurysms (sUIA) are being diagnosed since 2000. However, they are not systematically described and reviewed until now.

Case description and the literature review: We reported 2 patients with sUIA who initially presented with complex partial seizures (CPS). Scalp electroencephalography (EEG) showed the seizures activity arising from the mesial temporal/frontal areas, but conventional magnetic resonance imaging (MRI) scans were normal in both patients. The diagnoses of sUIA were achieved by cerebral angiography. One of the patients was treated as idiopathic seizure and suffered from subarachnoid hemorrhage before the final diagnosis of sUIA. Both of the patients were treated by surgical clipping without resection of the adjacent discolored brain tissue, and the seizures were controlled after surgery. Furthermore, we thoroughly reviewed the relevant literature. In total, including our cases, 5 cases were documented and analyzed to discuss the clinical characteristics, diagnosis, underlying mechanism, treatment and prognosis of epileptogenic sUIA.

Conclusions: The seizures caused by sUIAs are most likely related to subclinical hemorrhages. Angiograms may be helpful to identify seizures associated with sUIA in patients with normal conventional MRI scans. For epileptogenic sUIAs with normal preoperative MRI, clipping the aneurysm without damage to the surrounding brain tissue may be enough to resolve this complex issue.

Title Page**Small unruptured intracranial aneurysm ($\leq 5\text{mm}$) associated with epilepsy: report of
2 cases and literature review**

Authors: Fuxin Lin M.D.^{1*}, Hui Wan M.D.², Dezhi Kang MD.¹, Yuanxiang Lin M.D.¹

Affiliations:

1. Department of neurosurgery, The First Affiliated Hospital of Fujian Medical University, Fujian Medical University, Fujian province, P. R. China.
2. Department of neurosurgery, The Fourth Affiliated Hospital of Nanchang University, Nanchang, Jiangxi province, P. R. China.

Email:

FuXin Lin: lfxstudy@126.com

Hui Wan: 88572618@qq.com

Dezhi Kang: kdz99988@sina.com

Yuanxiang Lin: lyx99070@163.com

Corresponding Author: Yuanxiang Lin M.D.

Phone: 0591-87982126

Fax: 0591-83356180

E-mail: lyx99070@163.com

Keywords: Unruptured intracranial aneurysm, Epilepsy, clipping.

Abbreviations list:

ACA, anterior cerebral artery; ACoA, anterior communicating artery; AED, antiepileptic drug; CPS, complex partial seizure; CT, computed tomography; CTA, computed tomography angiography; DSA, digital subtraction angiography; EEG, electroencephalography; ICA, internal carotid artery; MCA, middle cerebral artery; MRI, magnetic resonance imaging; PCA, posterior cerebral artery; PCoA, posterior communicating artery; SAH, subarachnoid hemorrhage; SPS, simple partial seizure; sUIA, small unruptured intracranial aneurysm; UIA, unruptured intracranial aneurysm.

Abstract:

Background: Due to the continuing improvements in imaging technology, an increasing number of epileptogenic small ($\leq 5\text{mm}$) unruptured intracranial aneurysms (sUIA) are being diagnosed since 2000. However, they are not systematically described and reviewed until now.

Case description and the literature review: We reported 2 patients with sUIA who initially presented with complex partial seizures (CPS). Scalp electroencephalography (EEG) showed the seizures activity arising from the mesial temporal/frontal areas, but conventional magnetic resonance imaging (MRI) scans were normal in both patients. The diagnoses of sUIA were achieved by cerebral angiography. One of the patients was treated as idiopathic seizure and suffered from subarachnoid hemorrhage before the final diagnosis of sUIA. Both of the patients were treated by surgical clipping without resection of the adjacent discolored brain tissue, and the seizures were controlled after surgery. Furthermore, we thoroughly reviewed the relevant literature. In total, including our cases, 5 cases were documented and analyzed to discuss the clinical characteristics, diagnosis, underlying mechanism, treatment and prognosis of epileptogenic sUIA.

Conclusions: The seizures caused by sUIAs are most likely related to subclinical hemorrhages. Angiograms may be helpful to identify seizures associated with sUIA in patients with normal conventional MRI scans. For epileptogenic sUIAs with normal preoperative MRI, clipping the aneurysm without damage to the surrounding brain tissue may be enough to resolve this complex issue.

Introduction

The incidence of epilepsy in patients with unruptured intracranial aneurysm (UIA) is estimated about 2.9%-5.0%.^{3, 5, 12, 16} In the literature, the most frequent localization of the epileptogenic aneurysms was on the middle cerebral artery (MCA), and in most case reports, the aneurysms were large or giant.^{11, 15, 20} No epileptogenic aneurysms that were smaller than 5 mm in diameter were reported in the literature before 1999.¹⁰ Due to the continuing improvements in imaging technology, an increasing number of epileptogenic small (≤ 5 mm) unruptured intracranial aneurysms (sUIA) are being diagnosed since 2000.⁸ Because epileptogenic sUIAs are difficult to diagnose, their prevalence is likely underestimated, and some patients classified as having idiopathic complex partial seizures (CPS) treated with anticonvulsants could be at risk of subarachnoid hemorrhage (SAH). However, epileptogenic sUIAs are not systematically described and reviewed until now. To discuss the clinical characteristics, diagnosis, underlying mechanism, treatment and prognosis of epileptogenic sUIA, we report 2 patients with sUIA who presented with epilepsy, and review the relevant literature.

Case description:

Case 1:

A 48-year-old man presented to us in September 2013 with a 1-year history of CPS. The epilepsy began with the jerking motion of the left upper limb and culminated in a brief loss of consciousness. Carbamazepine and valproate failed to control the seizures. General and neurological examinations were normal, as were basic preoperative

laboratory tests. The past history was not significant. Scalp electroencephalography (EEG) showed frequent burst of sharp waves over the left mesial temporal lobe indicating seizure activity arising from this area. MRI scans were normal and volumetric measurements did not reveal any significant asymmetry between left and right hippocampal structures (Fig. 1 A, B). But preoperative computed tomography angiography (CTA) revealed a small aneurysm (3mm) located at C1 segment of left internal carotid artery (Fig.1 C, D). After careful consideration and patient counseling, a decision to treat both conditions was reached. Left pterional craniotomy was performed to clip the Aneurysm. During surgery, the medial left temporal lobe adjacent to the aneurysm was seen to have a yellowish hue, which we supposed to be an evidence of hemorrhagic products to indicate prior subclinical hemorrhages. Considering the normal preoperative MRI scans, the small lesion was clipped and the adjacent brain tissue was not resected (Fig. 2 A, B). Postoperative computed tomography (CT) scan was normal (Fig.1 E, F). The patient had an uneventful post-operative recovery and got seizure free without antiepileptic drug (AED) 6 months after surgery.

Case 2:

A 28-year-old man presented at our emergency department in June 2011 with an episode of severe headache. Emergent CT scans showed intracranial hematoma located at anterior longitudinal fissure (Fig. 3 A). General and neurological examinations were within normal limits. Past history was significant for a 10-year-history of CPS, which was controlled by valproate and carbamazepine. Workup included CT, MRI and EEG had

been performed 10 years ago. Ictal and interictal EEG revealed a right anterior temporal and inferior frontal lobe origin of his seizures. But MRI scans were normal and volumetric measurements did not reveal any significant asymmetry between left and right hippocampal. Emergent CTA showed a dilation of the conjunction between the left anterior cerebral artery (ACA) and the anterior communicating artery (ACoA) (Fig. 3 B). Preoperative digital subtraction angiography (DSA) identified the dilation as a small ACoA aneurysm (2mm) (Fig. 3 C, D). Left pterional craniotomy was performed to clip the aneurysm. After evacuation of the hematoma and clipping of the aneurysm, we found the mesial temporal lobe and inferior frontal lobe were discolored (Fig. 2 C, D), which we speculated to be a reaction to the previous asymptomatic and symptomatic hemorrhages. Considering the normal preoperative MRI scans, the adjacent brain tissues were preserved. The patient had an unremarkable postoperative course and was discharged home in good condition. Postoperative CT and CTA revealed complete obliteration of the aneurysm (Fig.3 E, F). After 2 years of follow-up, the patient has achieved seizure free and weaned off anti-convulsion drugs.

Discussion

Clinical characteristics

A thorough review of the literature on “Pubmed” was performed on this unusual etiology. Five cases with small epileptogenic aneurysms ($\leq 5\text{mm}$) including ours were documented and none of them were reported before 2000 (Table 1). The mean age of the patients at diagnosis was 44.2 ± 13.2 years. Seizure type of most of the patients was CPS

and only one patient noticed a musical hallucination (simple partial seizure SPS).

Seizures preceded discovery of the sUIA from 1 to 10 years in these patients, and during those intervals 1 patient suffered from SAH and 2 patients were misdiagnosed as idiopathic seizures. The aneurysm was situated on the distal internal carotid artery (ICA) (C1 segment) in 2 patients, localized at the ACoA in 1 patients, at the posterior communicating artery (PCoA) in 1 patient, and at the posterior cerebral artery (PCA) in the other one patient (Fig. 4). Only 1 of the sUIA was diagnosed by conventional MRI, 2 of them were discovered by angiography (CTA/DSA), 1 by special MRI scans (Thin MRI), and the other one was incidentally discovered during operation.

Diagnosis

Diagnosis of epilepsy caused by sUIA is difficult,¹⁷ that is reconfirmed by the long duration of epileptic symptoms (1-10 years) and unexpected SAH or misdiagnoses in this literature review study. The difficulties in diagnosis may be owing to two reasons as follows: First, cerebral aneurysms are not generally considered in the differential diagnosis of lesions causing seizures.^{6, 9, 11} In the literature, the most frequent causes of seizures are concluded as cerebrovascular disease 13.2%, developmental disorders 5.5 %, head trauma 4.1 %, brain tumors 3.6%, central nervous system infection 2.6%, degenerative diseases 1.8%, and for the remaining (70 % of the cases) the etiology are unknown.¹¹ Second, the small aneurysms with diameter lesser than 5mm is often invisible or ignored on conventional MRI scans. MRI has increased the sensitivity for the detection of focal cerebral pathology and vascular abnormalities. Thus, it has replaced cranial CT

scan as the imaging modality of choice in epilepsy.¹ However, in this study, conventional MRI detected only one sUIA in 5 cases. Thus, cerebral angiography may be necessary to identify and confirm the small vascular diseases. Because seizures resulting from small aneurysms are difficult to diagnose, their prevalence is likely underestimated and some patients classified as having idiopathic CPS treated with anticonvulsants could be at risk of SAH (such as case 2).⁹ Based on our results and the literatures, we put forward some suggestions for diagnosis in this kind of challenging patients as follows: 1). In patients with CPS or SPS arising from the mesiotemporal area or inferior frontal area, UIA should be included in the differential diagnosis. 2). Angiograms may be helpful to identify seizures associated with sUIA in patients with normal conventional MRI scans.

Mechanism of the epilepsy

In our cases, seizures were supposed to be due to the sUIA. This hypothesis was supported by the correlation between localization of the aneurysm and epileptic focus determined by EEG, and by the seizure controlling without damage to brain tissues adjacent to aneurysms and without anticonvulsant drugs after surgery. Based on the low seizure threshold of mesial temporal lobe structures, several mechanisms have been postulated to explain the seizures caused by UIA.^{2, 6, 7, 9, 19} We concluded as follows: 1) direct cortical compression by the UIA,⁷ 2) pulsatile aneurysmal wall against the brain,¹⁴ 3) emboli from distant cerebral aneurysms travelling to other parts of the brain,^{9, 19} 4) the calcified walls of the aneurysms acted as hamartomas,² 5) hemosiderin deposition and gliosis caused by subclinical SAH.⁶ For sUIAs, lesions are too small to cause any direct

compression or intermittent pulsatile compression. On the other hand, the calcified wall and intraluminal thrombus are uncommon in small aneurysms. Thus, the seizures caused by sUIAs are most likely related to subclinical hemorrhages, which were supported by intraoperative findings of yellowish hue and blood products of adjacent brain tissue in our cases.

Treatment and prognosis:

In this cohort of patients with epileptogenic sUIAs, all cases were surgically treated. In the literature, clipping of the UIAs and resection of the adjacent abnormal brain tissue are proposed to control the seizures and to prevent the risk of bleeding (Patient 3 and 5).^{5, 9,}

¹⁹ However, in our cases, only clipping of aneurysm was performed and surrounding brain tissues were preserved. As we have mentioned before, the seizures associated with sUIAs were most likely related to subclinical hemorrhages, which repeatedly irritated the surrounding brain tissues. Elimination of the subclinical hemorrhages by aneurysm clipping may be enough to control the seizures. On the other hand, considering the normal preoperative MRI scans and the risk of neuropsychologic sequelae after resection of a healthy mesial temporal lobe and hippocampus, especially with regard to memory function, the adjacent brain tissues were not resected. As expected, the seizures were resolved after surgery without AEDs (Table 1). Thus, we postulated that, for epileptogenic sUIAs with normal preoperative MRI, clipping the aneurysm without damage to the surrounding brain tissue may be enough to resolve this complex issue. In clinical practice, neurosurgeons are now often faced with the dilemma of whether to treat

sUIA with surgical clipping or to manage them with endovascular embolization.^{13, 16}

Considering the subclinical SAH and irritation of blood products may be the prominent mechanism of seizures, endovascular embolization of epileptogenic sUIAs to prevent further blood leak might be an alternative method to treat. However, when considering this treatment option in patients with aneurysm related seizures, several factors must be taken into consideration. The aneurysm must be amenable to endovascular coiling from a morphologic and anatomic standpoint.^{4, 6, 9} But, till now, we have no knowledge of a documented case of sUIA associated with epilepsy that has been successfully treated by the use of endovascular embolization. A larger series is needed to get a clearer picture of the effects of such a treatment.

Conclusions:

The seizures caused by sUIAs are most likely related to subclinical hemorrhages. Angiograms may be helpful to identify seizures associated with sUIA in patients with normal conventional MRI scans.. For epileptogenic sUIAs with normal preoperative MRI, clipping the aneurysm without damage to the surrounding brain tissue may be enough to resolve this complex issue.

Conflict of interest

The authors report no conflict of interest concerning the materials or methods used in this study or the findings specified in this paper.

Acknowledgments:

This study was supported by the Key Clinical Specialty Discipline Construction Program

of Fujian Province in China (No. 2012-SLCZD-2), and major project of Fujian provincial department of science and technology (No. 2014YZ0003 and No. 2014YZ01 to D-ZK).

References:

1. Baesa SS, Dang T, Keene DL, Ventureyra EC: Unusual association of intractable temporal lobe seizures and intracranial aneurysms in an adolescent: is it a coincidence? *Pediatr Neurosurg* 28(4):198-203, 1998.
2. Çağavi F, Kalayci M, Unal A, Atasoy HT, Çağavi Z, Açıköz B: Giant unruptured anterior communicating artery aneurysm presenting with seizure. *J Clin Neurosci* 13(3):390-394, 2006.
3. Ellamushi H, Thorne L, Kitchen N: Unruptured cerebral aneurysms causing seizure disorder (report of two cases). *Seizure* 8(5): 310–313, 1999.
4. Gnanalingham KK, Colquhoun I, van Dellen J: Temporal lobe seizures: unusual presentation of a giant unruptured posterior communicating artery aneurysm. *17(4):370-371, 2003.*
5. Hänggi D, Winkler PA, Steiger H-J: Primary Epileptogenic Unruptured Intracranial Aneurysms: Incidence and Effect of Treatment on Epilepsy. *Neurosurgery* 66(6): 1161-1165, 2010.
6. Kamali AW, Cockerell OC, Butlar P: Aneurysms and epilepsy: an increasingly recognised cause. *Seizure* 13(1):40-44, 2004.
7. Kuba R, Krupa P, Okacova L, Rektor I: Unruptured intracranial aneurysm as a cause of

focal epilepsy: an excellent postoperative outcome after intra-arterial treatment. *Epileptic Disord* 6(1):41-44, 2004.

8. Lad SP, Shannon L, Byrne RW: Incidental aneurysms in temporal lobe epilepsy surgery: report of three cases and a review of the literature. *Br J Neurosurg* 26(1): 69–74, 2012.

9. Miele VJ, Bendok BR, Batjer HH: Unruptured aneurysm of the middle cerebral artery presenting with psychomotor seizures: case study and review of the literature. *Epilepsy Behav* 5(3): 420-428, 2004.

10. Roberts DL, Tatini U, Zimmerman RS, Bortz JJ, Sirven JI: Musical hallucinations associated with seizures originating from an intracranial aneurysm. *Mayo Clin Proc* 76(4): 423-426, 2001.

11. Sena JC, Reynier Y, Alliez B: Unruptured intracranial aneurysm presenting with epileptic seizure. *Arq Neuropsiquiatr* 61(3-A):663-667, 2003.

12. Solomon RA, Fink ME, Pile-Spellman J: Surgical management of unruptured intracranial aneurysms. *J Neurosurg* 80(3): 440–446, 1994.

13. Steiner T, Juvela S, Unterberg A, Jung C, Forsting M, Rinkel G; European Stroke Organization: European Stroke Organization guidelines for the management of intracranial aneurysms and subarachnoid haemorrhage. *Cerebrovasc Dis* 35(2):93-112, 2013.

14. Stewart RM, Samson D, Diehl J, Hinton R, Ditmore QM: Unruptured cerebral aneurysms presenting as recurrent transient neurologic deficits. *Neurology* 30(1): 47-51,

1980.

15. Tanaka K, Hirayama K, Hattori H, Matsuoka O, Sakamoto H, Hakuba A, Murata R: A case of cerebral aneurysm associated with complex partial seizures. *Brain Dev* 16(3): 233-237, 1994.

16. Thompson BG, Brown RD Jr, Amin-Hanjani S, Broderick JP, Cockcroft KM, Connolly ES Jr, Duckwiler GR, Harris CC, Howard VJ, Johnston SC, Meyers PM, Molyneux A, Ogilvy CS, Ringer AJ, Torner J; American Heart Association Stroke Council, Council on Cardiovascular and Stroke Nursing, and Council on Epidemiology and Prevention; American Heart Association; American Stroke Association: Guidelines for the Management of Patients With Unruptured Intracranial Aneurysms: A Guideline for Healthcare Professionals From the American Heart Association/American Stroke Association. *Stroke* 46(8): 2368-2400, 2015.

17. Ulahannan TJ: Epileptic seizures due to cerebral artery aneurysm. *J R Soc Med* 91(6): 325, 1998.

18. Whittle IR, Allsop JL, Halmagyi GM: Focal seizures: an unusual presentation of giant intracranial aneurysms. A report of four cases with comments on the natural history and treatment. *Surg Neurol* 24(5):533-540, 1985.

19. Yacubian EM1, Rosemberg S, da Silva HC, Jorge CL, de Oliveira E, de Assis LM: Intractable complex partial seizures associated with posterior cerebral artery giant aneurysm: a case report. *Epilepsia* 35(6):1317-20, 1994.

20. Zambrelli E, Cavallini A, Tosi P, Marcheselli S, Giardini G, Pichiecchio A, Micieli G:

A possible case of unruptured middle cerebral artery aneurysm presenting as epileptic seizures. *Neurol Sci* 24(3): 141–144, 2003.

Figure Legend:

Fig. 1: Neuroimaging findings of case 1. Conventional MRI scans were normal (A, B).

Preoperative CTA revealed a small aneurysm (3mm) located at C1 segment of left internal carotid artery (C, D). Postoperative CT scans were normal (E, F).

Fig. 2: Intraoperative pictures of our cases (A and B for patient 1, C and D for patient 2) to illustrate the angioarchitectures and surrounding structures of the small aneurysms. An, aneurysm; C1, C1 segment of internal carotid artery; ON, optic nerve; ACoA, anterior communicating artery; A1, A1 segment of the anterior cerebral artery; A2, A2 segment of the anterior cerebral artery; FL, frontal lobe.

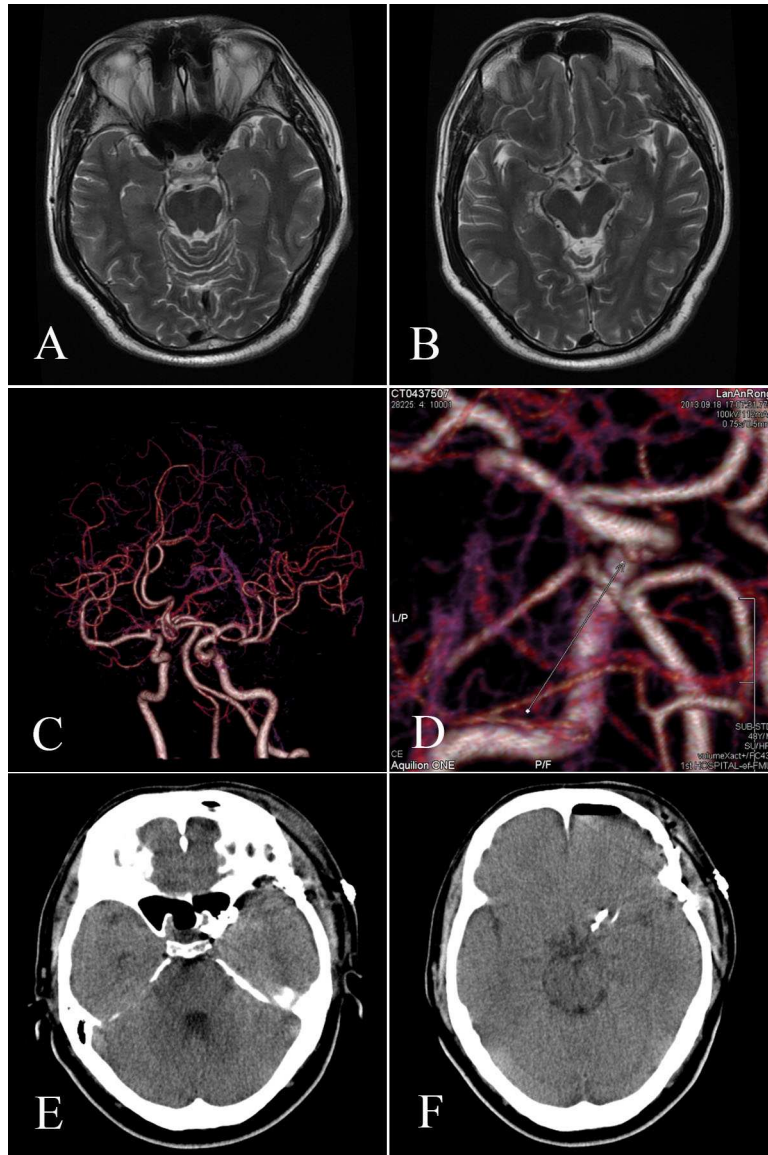
Fig. 3: Neuroimaging findings of case 2. Emergent CT scans showed intracranial hematoma located at anterior longitudinal fissure (A). CTA showed a dilation of the conjunction between the left ACA and the ACoA (B). Preoperative DSA identified the dilation as a small ACoA aneurysm (2mm) (C, D). Postoperative CT and CTA revealed complete obliteration of the aneurysm (E, F).

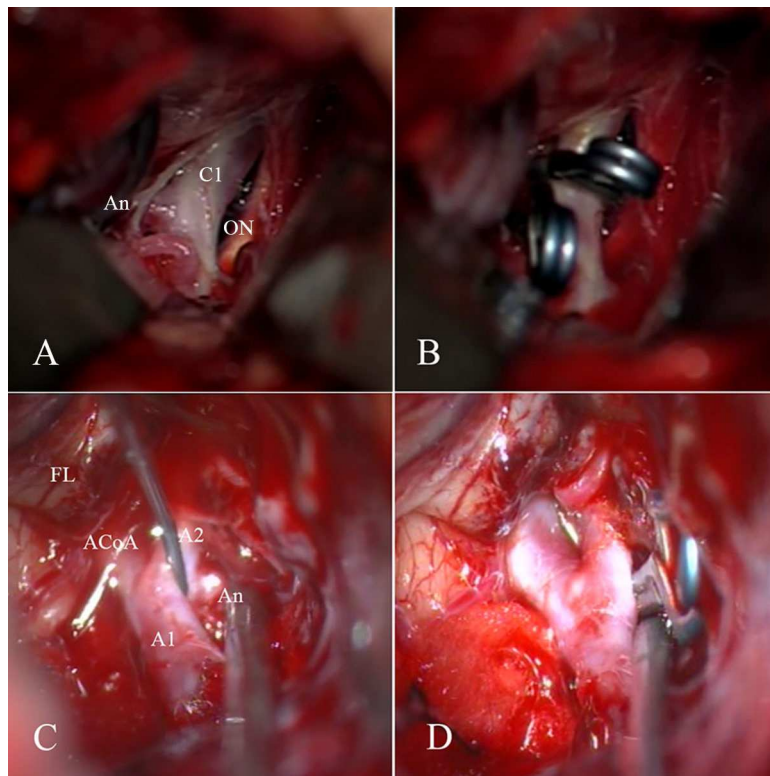
Fig. 4: In this cohort of patients, the aneurysm was situated on the distal ICA (C1 segment) in 2 patients, localized at the ACoA in 1 patients, at the PCoA in 1 patient, and at the PCA in the other one patient.

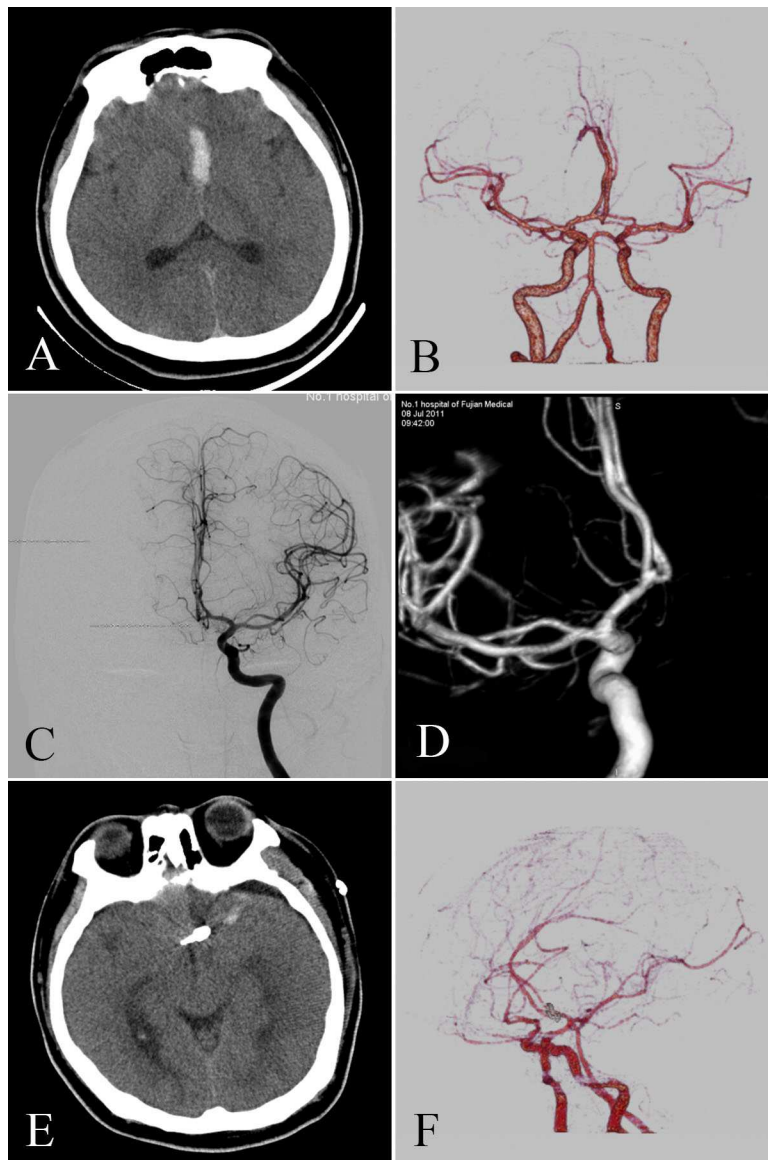
Table 1: Literature review of small unruptured intracranial aneurysms ($\leq 1\text{cm}$) initially presenting with seizures.

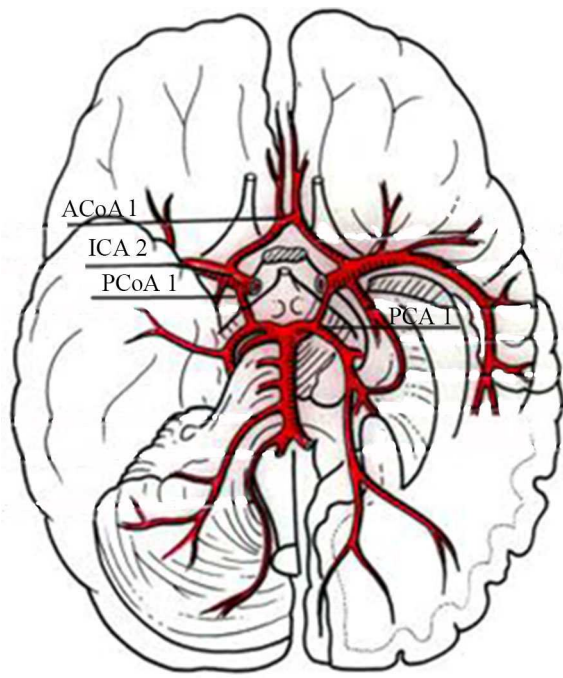
Authors	Year	No	Age (Y)	Sex	Seizure Type (EEG)	DoS	MD or SAH	Location	Size (mm)	DM	Treatment	Epi-focus	Prognosis	Postulated mechanism
This study	2016	1	48	M	CPS (focus)	1 Y	No	R ICA	3	CTA	Clip	Untreat-ed	Resolved	Subclinical hemorrhage
		2	28	M	CPS (focus)	10 Y	SAH	ACoA	2	CTA/DSA	Clip	Untreat-ed	Resolved	Subclinical hemorrhage
Lad SP et al.	2012	3	34	--	CPS (focus)	4 Y	MD	R PCA	5	Intra-op	Clip	Resected	Resolved	Incidental An
Kamali AW et al.	2004	4	50	M	CPS (negative)	3 Y	No	R PCoA	5-6	MRI	Clip	--	Seizure	--
Boberts DL et al.	2001	5	61	F	musical hallucinations (focus)	3 Y	MD	R ICA	5	Thin MRI	Clip	Resected	Resolved	Gliosis

EEG, electroencephalogram; DoS, duration of epileptic symptoms; MD, misdiagnosis; SAH, subarachnoid hemorrhage; DM, diagnostic methods discovered the sUIAs; CTA, computed tomography angiography; DSA, digital subtraction angiography; MRI, magnetic resonance imaging; Epi-focus: epileptogenic focus determined on preoperative EEG; CPS, complex partial seizure; ICA, internal carotid artery; ACoA, anterior communicating artery; PCA, posterior cerebral artery; PCoA, posterior communicating artery; --, not available.









1. We reported 2 patients with small ($\leq 5\text{mm}$) unruptured intracranial aneurysms (sUIA) who initially presented with epilepsy, and reviewed the relevant literature. Epileptogenic sUIAs are uncommon and not systematically described and reviewed until now.
2. Literature review shows angiogram may be necessary to exclude sUIA even in patients with normal conventional MRI before the diagnosis of idiopathic seizure.
3. Our cases indicate that clipping the aneurysm without damage to the surrounding brain tissue may be enough to resolve this complex issue in patients with normal preoperative MRI.

Abbreviations list:

ACA, anterior cerebral artery;

ACoA, anterior communicating artery;

AED, antiepileptic drug;

CPS, complex partial seizure;

CT, computed tomography;

CTA, computed tomography angiography;

DSA, digital subtraction angiography;

EEG, electroencephalography;

ICA, internal carotid artery;

MCA, middle cerebral artery;

MRI, magnetic resonance imaging;

PCA, posterior cerebral artery;

PCoA, posterior communicating artery;

SAH, subarachnoid hemorrhage;

SPS, simple partial seizure;

sUIA, small unruptured intracranial aneurysm;

UIA, unruptured intracranial aneurysm.