

## Positional Occlusion of Vertebral Artery Due to Cervical Spondylosis as Rare Cause of Wake-up Stroke: Report of Two Cases

Hirofumi Nishikawa<sup>1</sup>, Fumitaka Miya<sup>1</sup>, Yotaro Kitano<sup>1</sup>, Genshin Mori<sup>1</sup>, Shigetoshi Shimizu<sup>1</sup>, Hidenori Suzuki<sup>2</sup>

### Key words

- Cervical spondylosis
- Positional occlusion
- Vertebral artery
- Wake-up stroke

### Abbreviations and Acronyms

**CT:** Computed tomography

**ICG:** Indocyanine green

**MR:** Magnetic resonance

**VA:** Vertebral artery

From the <sup>1</sup>Department of Neurosurgery, Ise Red Cross Hospital, Ise; and <sup>2</sup>Department of Neurosurgery, Mie University Hospital, Tsu, Mie, Japan

To whom correspondence should be addressed:

Hirofumi Nishikawa, M.D.

[E-mail: [trygetter10@yahoo.co.jp](mailto:trygetter10@yahoo.co.jp)]

Citation: *World Neurosurg.* (2016).

<http://dx.doi.org/10.1016/j.wneu.2016.11.071>

Journal homepage: [www.WORLDNEUROSURGERY.org](http://www.WORLDNEUROSURGERY.org)

Available online: [www.sciencedirect.com](http://www.sciencedirect.com)

1878-8750/\$ - see front matter © 2016 Elsevier Inc. All rights reserved.

## INTRODUCTION

Bow hunter syndrome is a well-known cause of vertebrobasilar insufficiency associated with neck movement, but stroke owing to cervical spondylosis is uncommon.<sup>1</sup> Two types of vertebral artery (VA) compression by cervical spondylosis were reported: compression from the inside by uncovertebral osteophytes and that from behind by superior articular process osteophytes.<sup>1-7</sup> The exact pathogenesis of ischemic events remains unclear, but repeated ischemic attacks including transient ischemic attacks with or without neck movement may indicate a hemodynamic process. The other pathogenesis includes embolism from the compressed artery.<sup>7-9</sup> We report two rare cases of cervical spondylosis-induced VA compression manifesting as wake-up stroke, and discuss the mechanisms and surgical management.

■ **BACKGROUND:** Positional compression of the vertebral artery (VA) owing to cervical spondylosis is an uncommon cause of stroke. We report two cases of cervical spondylosis causing wake-up stroke, which is extremely rare.

■ **CASE DESCRIPTION:** The first patient was a 78-year-old woman with vertigo and vomiting lasting from waking up. Magnetic resonance imaging (MRI) and angiography documented right cerebellar infarction, and stenosis of the right cervical VA. Dynamic angiography revealed that the right VA was occluded when her neck was extended or rotated to the right. Computed tomography (CT) angiography revealed the right VA compression by the right C5 superior articular process osteophytes. The second patient was a 77-year-old man with dysarthria from waking up. MRI and angiography revealed right cerebellar infarction associated with the right VA stenosis and the left VA occlusion at C5-C6, whose cause was diagnosed as compression caused by bilateral uncovertebral osteophytes on CT angiography. Dynamic angiography showed that neck rotation to the right aggravated the right VA stenosis while recanalizing the left VA. Both patients were treated with a free radical scavenger (edaravone) and heparin, and underwent surgical decompression of VAs 14 or 18 days after onset. No recurrent ischemic events occurred thereafter.

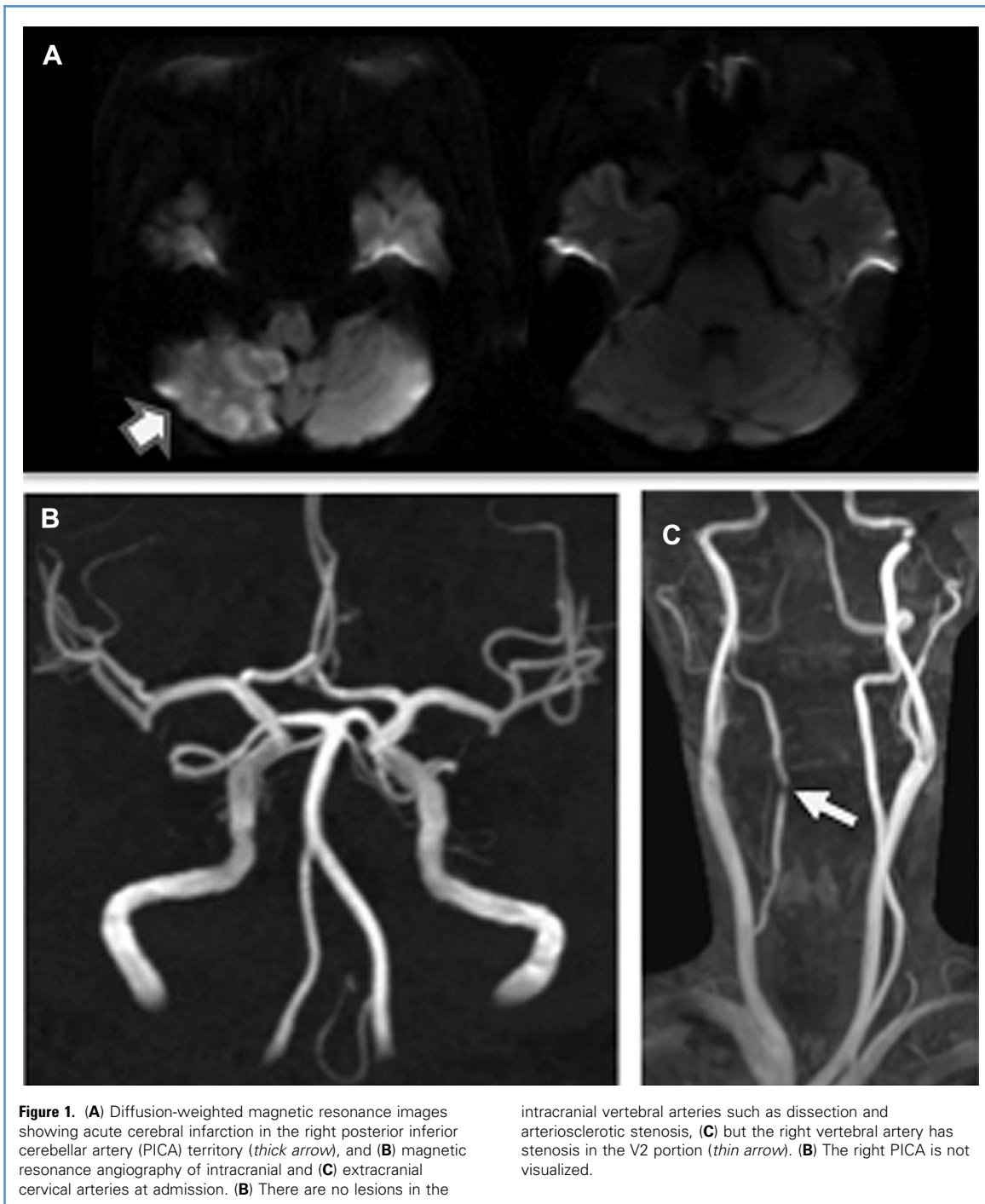
■ **CONCLUSIONS:** Magnetic resonance angiography of extracranial cervical VAs may be useful as an initial screening test for VA compression secondary to cervical spondylosis as a rare cause of wake-up stroke, especially in cases of cerebral infarction in the posterior circulation with no evidences of causative arrhythmia and intracranial lesions.

## CASE REPORT

### Patient 1

A 78-year-old woman with no medical history reported vertigo and vomiting that occurred when she woke up in the morning. The patient was alert and had gaze-evoked horizontal nystagmus. Brain magnetic resonance (MR) images at 5 hours after onset revealed acute infarction in the right posterior inferior cerebellar artery territory, and MR angiography showed stenosis in the midportion of the right cervical VA (Figure 1). Neck rotation and head tilting elicited no symptoms, but neck rotation to the right and extension caused complete occlusion of the right VA at C4-C5 (Figure 2). Computed tomography (CT) angiography disclosed that the cause of VA compression was C5 superior facet osteophytes (Figure 3).

The patient was treated with intravenous infusions of a free radical scavenger—edaravone and heparin. At 18 days after onset, we performed decompression of the right VA through an anterolateral approach. The C4-C5 transverse processes and the anterolateral side of vertebral body were exposed, and venous plexus around the VA was gently coagulated and cut. The C4-C5 anterior roots of the transverse process were unroofed using a high-speed drill and an ultrasonic surgical aspiration and irrigation system (Sonopet Ultrasonic Bone Aspirator; Stryker, Kalamazoo, Michigan, USA). After the unroofing, indocyanine green (ICG) videoangiography showed the VA stenosis. The Sonopet ultrasonic bone aspirator was used to resect the osteophyte of superior articular process compressing VA, which was confirmed with ICG videoangiography.



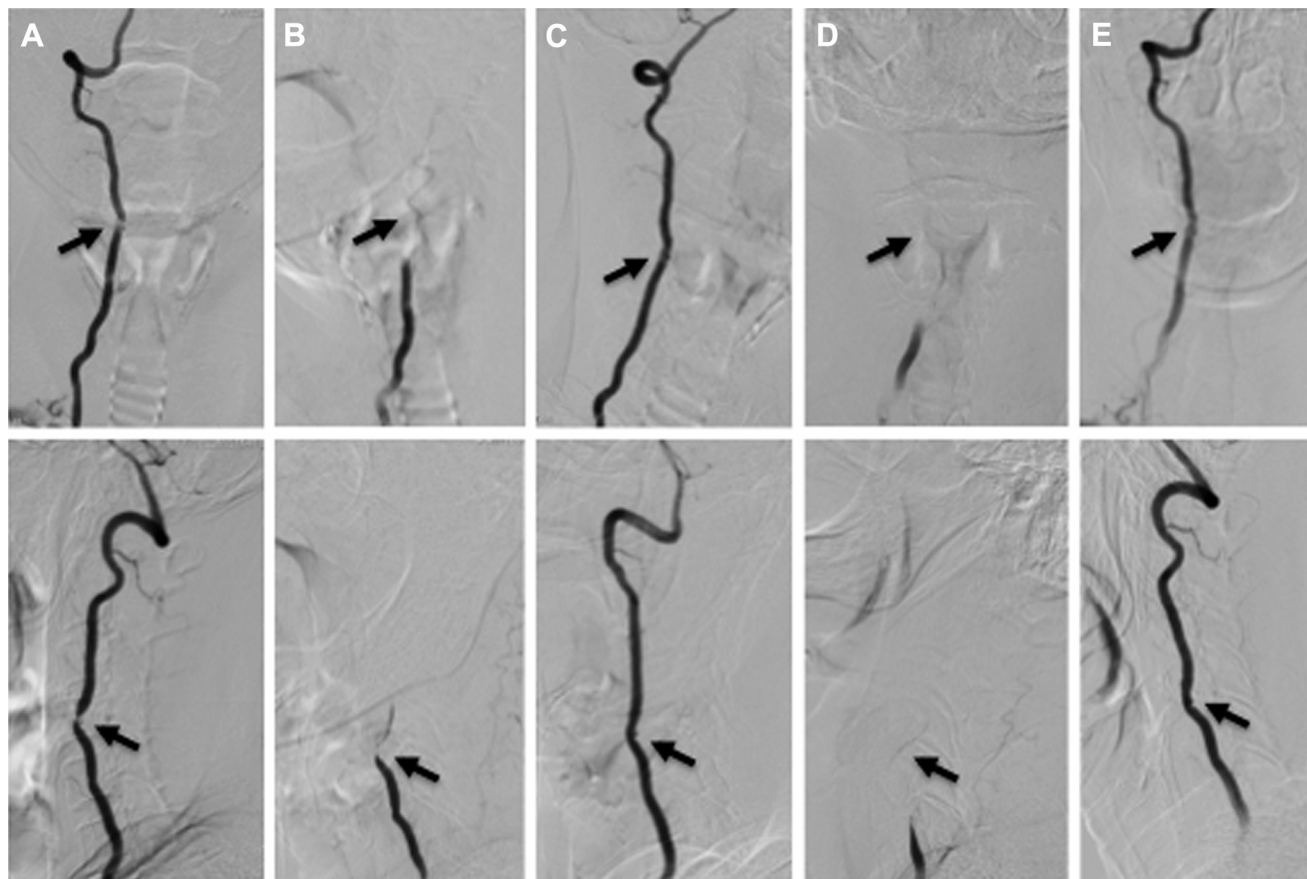
The postoperative course was uneventful. Postoperative CT angiography revealed complete resection of the right C5 superior articular process osteophyte (Figure 4), and angiography confirmed decompression of the right VA at 7 days postoperatively (Figure 5). The patient

returned to her daily activities without limitations 1 month postoperatively.

#### Patient 2

A 77-year-old man exhibited dysarthria that occurred when he woke up in the morning. His medical history included

diabetes mellitus, minor cerebral infarction, and repeated dizziness for the last year. His medication included an antiplatelet clopidogrel. Neurologic examinations revealed dysarthria and a spastic gait. Brain MR images revealed acute infarction in the right superior cerebellar



**Figure 2.** Preoperative dynamic right vertebral angiograms. The *upper row* contains anteroposterior views; the *lower panel* contains lateral views. (A) Stenosis is observed in the right vertebral artery at C4-C5 in a neutral position (*arrow*), which is occluded by neck rotation to the right (B) and

recanalized by neck rotation to the left (C). The right vertebral artery is also occluded with the patient's neck in an extension position (D) and recanalized in a flexion position (E).

artery territory, and MR angiography in a neutral neck position showed no visualization of the left VA and stenosis in the midportion of the right cervical VA (Figure 6). Neck rotation triggered no neurologic symptoms, but angiography demonstrated that the right VA stenosis was aggravated by neck rotation to the right and improved by neck rotation to the left at C5-C6, whereas the left VA was occluded with his neck in a neutral position or rotated to the left, and recanalized by neck rotation to the right. Cervical spine MR images showed canal stenosis and intramedullary degeneration at C5-C6. CT angiography revealed that osteophytes of bilateral C5-C6 uncovertebral joints compressed each VA (Figure 7).

The patient was treated with intravenous infusions of edaravone and heparin plus oral clopidogrel. At 14 days after

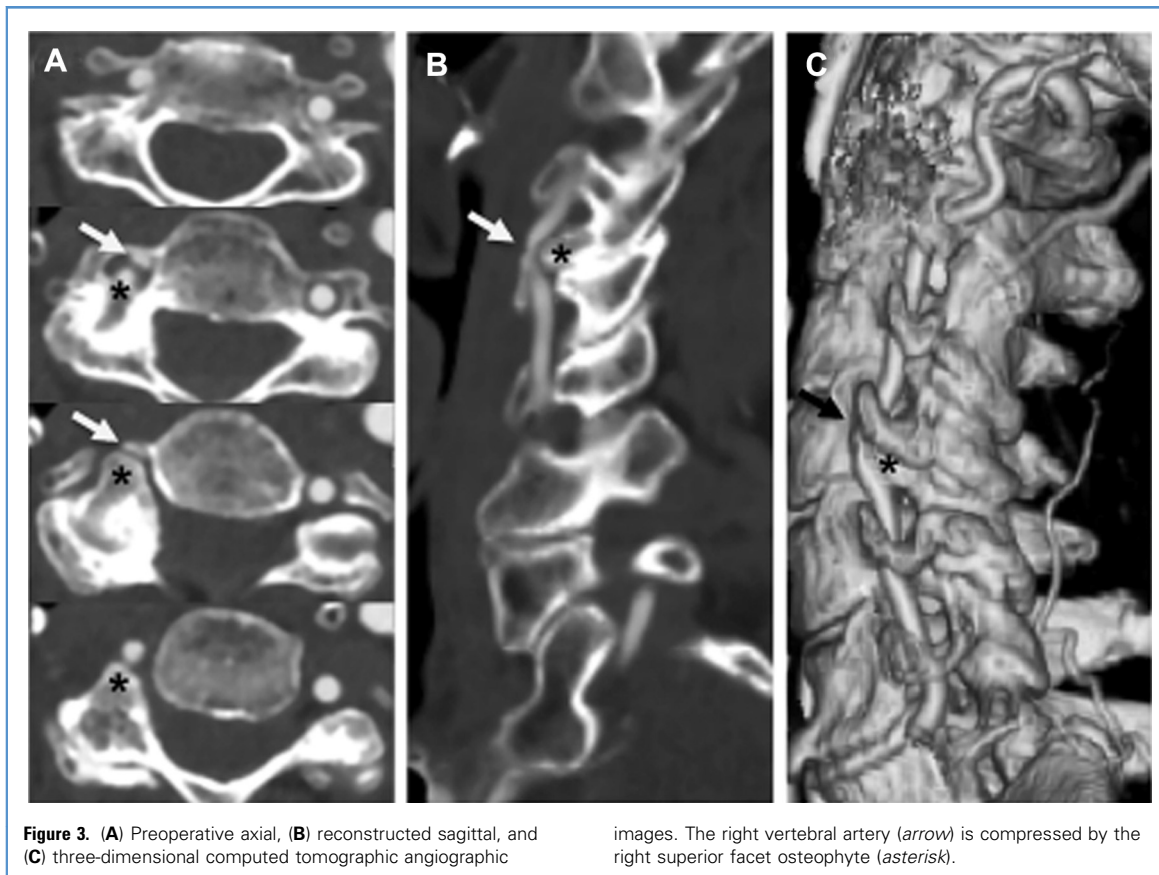
onset, decompression of bilateral VAs and anterior cervical decompression and fusion at C5-C6 were performed using an anterior approach. The wide transverse incision of the skin enabled us to approach bilateral uncovertebral junctions. The bilateral longus colli muscles were dissected laterally to expose the medial aspect of transverse process and the lateral joint of uncinated process. Bilateral C5-C6 anterior roots of transverse process were unroofed, and uncovertebral osteophytes were resected using a high-speed drill and the Sonopet ultrasonic bone aspirator. ICG videoangiography demonstrated the improvement of VA stenosis and blood flow.

The postoperative course was uneventful. Postoperative CT angiographic images 1 day after surgery confirmed resection of uncovertebral osteophytes, and MR

angiography at 7 days after surgery confirmed improvement of blood flow (Figures 8 and 9). The patient was discharged to home with no deficits 1 month after surgery.

## DISCUSSION

VA compression secondary to cervical spondylosis is a well-known but uncommon cause of vertebrobasilar insufficiency and stroke. The literature reported that patients with surgical treatment had a mean age of 55 years old, and the surgical treatment was more likely in men.<sup>1</sup> Transient ischemic attack was the most common primary symptom, accounting for 82%, and the rest was cerebral infarction.<sup>1</sup> Among cerebral infarctions, embolism was a more common mechanism than hemodynamic causes



**Figure 3.** (A) Preoperative axial, (B) reconstructed sagittal, and (C) three-dimensional computed tomographic angiographic

images. The right vertebral artery (arrow) is compressed by the right superior facet osteophyte (asterisk).

were. The causative structure of VA compression was uncovertebral osteophytes (92%), superior articular osteophytes (6%), and osteophytes of transverse foramen (2%).<sup>1</sup> Neck movement to the side ipsilateral to VA compression and neck extension typically induced symptoms and worsened the stenosis on angiography.<sup>1,7</sup> The most commonly involved levels were at C5-C6 (76%) and C4-C5 (18%). Notably, 96% of the patients were reported to have VA stenosis even in a neutral neck position.<sup>1,4,8</sup> Yoshimura et al.<sup>10</sup> reported an exceptional case of bow hunter's stroke because of the uncovertebral C3-C4 joint instability without osteophytes, which showed normal VA flow in a neutral neck position. In the present cases, the onset as wake-up stroke was unusual, although VA stenosis on MR angiography in a neutral position helped us to suggest VA compression caused by cervical spondylosis. MR angiography of extracranial cervical VAs may be useful as an initial screening test for VA compression

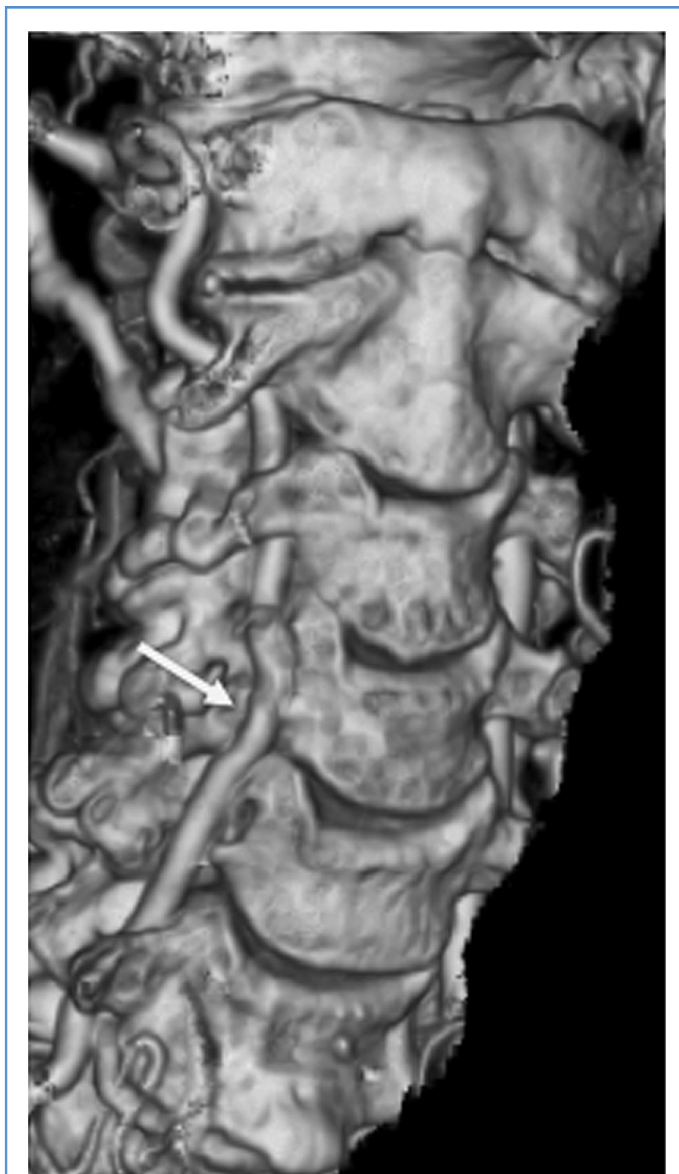secondary to cervical spondylosis, and should be obtained, especially in cases of cerebral infarction in the posterior circulation with no evidence of causative arrhythmia and intracranial lesions, such as VA dissection or arteriosclerotic stenosis. However, as a severe atherosclerotic disease may show similar findings, dynamic vertebral angiography is needed for the definitive diagnosis.

The mechanisms by which cervical spondylosis-induced VA compression causes ischemic events remain unclear. The short duration and frequent recurrences of transient ischemic attacks are consistent with hemodynamic process, which can occur by rotational or positional VA occlusion or severe stenosis in cases with the contralateral VA aplasia or hypoplasia.<sup>11</sup> Other mechanisms include embolic process, whose source was reported to be artery dissection caused by minor injury during neck movement,<sup>9</sup> or fluctuant turbulent blood flow at VA stenosis.<sup>11</sup> To our knowledge, only one case of VA compression owing to a

cervical spinal lesion was reported to manifest as wake-up stroke. The cause of stroke was considered to be embolic by a clot of blood that was formed because of prolonged VA occlusion caused by cervical far lateral disc herniation during sleeping.<sup>12</sup> In our two patients exhibiting wake-up stroke, we found no findings to suspect VA dissection on neuroimaging or during surgery. Therefore, we also supposed that keeping the same neck position associated with VA occlusion during sleeping might result in thrombus formation, and that artery-to-artery embolism might occur when the patients awoke and changed their neck position to recanalize the VA.

The preferred treatment for symptomatic cervical spondylosis-induced VA compression may be decompression surgery for the VA, because it was reported that antiplatelet therapy and other conservative therapies were less effective.<sup>11</sup> Furthermore, even bed rest can cause stroke as in our cases. Regarding surgical strategies, Nagashima<sup>5</sup> reported





**Figure 4.** Postoperative three-dimensional computed tomographic angiography showing sufficient decompression of the right vertebral artery (arrow).

that it is important to resect nonosseous tissues, such as muscle tendon, osseous membrane, and other perivascular fibrous band in addition to removing osteophytes and two anterior roots of transverse processes above and below the VA compression to sufficiently decompress VA. There are three approaches reported: anterior, anterolateral, and posterior approaches.<sup>1,2,4-7,11,13,14</sup> The anterior approach is suitable for resection of

uncovertebral osteophytes usually compressing VA from the medial side, because it provides an excellent operating view for drilling uncovertebral osteophytes and removing the two anterior roots of transverse processes.<sup>2,3,5</sup> On the other hand, when VA is compressed by superior articular osteophytes usually existing behind VA and spinal nerve roots, the anterior approach has some risks for injuries to the VA and spinal nerve roots. Citow

et al.<sup>4</sup> recommended a posterior approach to decompress VA by superior articular osteophytes, although this approach could not decompress the VA at the transverse foramen. Takeuchi et al.<sup>7</sup> reported the usefulness of the Sonopet ultrasonic bone aspirator for the removal of superior articular osteophytes and anterior roots of transverse processes using an anterior approach. We also used the Sonopet ultrasonic bone aspirator and realized the usefulness of it. However, we selected an anterolateral approach to obtain a better operating field and to remove more safely both superior articular osteophytes, which exist behind VA and spinal nerve roots, and anterior roots of transverse processes. The need for bony fusion is conflicting; the outcome of VA decompression without bony fusion is reported to be excellent,<sup>1,3,5</sup> whereas some reports recommend intervertebral fusion techniques.<sup>11,13</sup>

Our surgical strategies decompressing the superior articular osteophytes or uncovertebral osteophytes resulted in the radiologic improvement and the functional recovery in both patients. However, older patients may have other confounders, such as age-related comorbidities or modifiable diseases. Therefore, it may be necessary to study similar cases to determine whether the surgical strategies are effective for stroke caused by VA compression secondary to cervical spondylosis in older patients.

## CONCLUSION

We reported two rare cases of wake-up stroke whose cause was rotational or positional VA occlusion caused by cervical spondylosis. We should pay attention to each patient's neck position to avoid recurrent stroke until surgical treatment is performed using a suitable approach.

## REFERENCES

1. Denis DJ, Shedid D, Shehadeh M, Weil AG, Lanthier S. Cervical spondylosis: a rare and curable cause of vertebrobasilar insufficiency. *Eur Spine J.* 2014;23(Suppl 2):206-213.
2. Bakay L, Leslie EV. Surgical treatment of vertebral artery insufficiency caused by cervical spondylosis. *J Neurosurg.* 1965;23:596-602.
3. Bulsara KR, Velez DA, Villavicencio A. Rotational vertebral artery insufficiency resulting from

- cervical spondylosis: case report and review of the literature. *Surg Neurol.* 2006;65:625-627.
4. Citow JS, Macdonald RL. Posterior decompression of the vertebral artery narrowed by cervical osteophyte: case report. *Surg Neurol.* 1999;51:495-498.
  5. Nagashima C. Surgical treatment of vertebral artery insufficiency caused by cervical spondylosis. *J Neurosurg.* 1970;32:512-521.
  6. Petridis AK, Barth H, Buhl R, Mehdorn HM. Vertebral artery decompression in a patient with rotational occlusion. *Acta Neurochir (Wien).* 2008;150:391-394.
  7. Takeuchi S, Kawaguchi T, Nakatani M, Isu T. Hemorrhagic infarction originating from vertebral artery stenosis caused by an osteophyte at the C5 superior articular process. *Neurol Med Chir.* 2009;49:114-116.
  8. Choi JM, Hong HJ, Chang SK, Oh SH. Cerebellar infarction originating from vertebral artery stenosis caused by a hypertrophied uncovertebral joint. *J Stroke Cerebrovasc.* 2012;21:e907-e909.
  9. Shimizu S, Ishigaki T, Murata H, Kubo Y, Toma N, Morooka Y. Vertebral artery dissection due to a bone anomaly of the superior facet of C6: a rare cause of embolic stroke. *No Shinkei Geka.* 2008;36:725-730.
  10. Yoshimura K, Iwatsuki K, Ishihara M, Onishi Y, Umegaki M, Yoshimine T. Bow hunter's stroke due to instability at the uncovertebral C3/4 joint. *Eur Spine J.* 2011;20(Suppl 2):S266-S270.
  11. Kawaguchi T, Fujita S, Hosoda K, Shibata Y, Iwakura M, Tamaki N. Rotational occlusion of the vertebral artery caused by transverse process hyperrotation and unilateral apophyseal joint subluxation. Case report. *J Neurosurg.* 1997;86:1031-1035.
  12. Okawa M, Amamoto T, Abe H, Yoshimura S, Higashi T, Inoue T. Wake-up stroke in a young woman with rotational vertebral artery occlusion due to far-lateral cervical disc herniation. *J Neurosurg Spine.* 2015;23:166-169.
  13. Miele VJ, France JC, Rosen CL. Subaxial positional vertebral artery occlusion corrected by decompression and fusion. *Spine (Phila Pa 1976).* 2008;33:e366-e370.
  14. Yamaguchi S, Sakata K, Nakayama K, Shigemori M. A case of embolic infarction originating from extracranial vertebral artery stenosis by cervical spondylosis at C5/6: its pathogenesis and surgical treatment. *No Shinkei Geka.* 2003;31:1111-1116.

*Conflict of interest statement: The authors declare that the article content was composed in the absence of any commercial or financial relationships that could be construed as a potential conflict of interest.*

*Received 4 August 2016; accepted 15 November 2016*

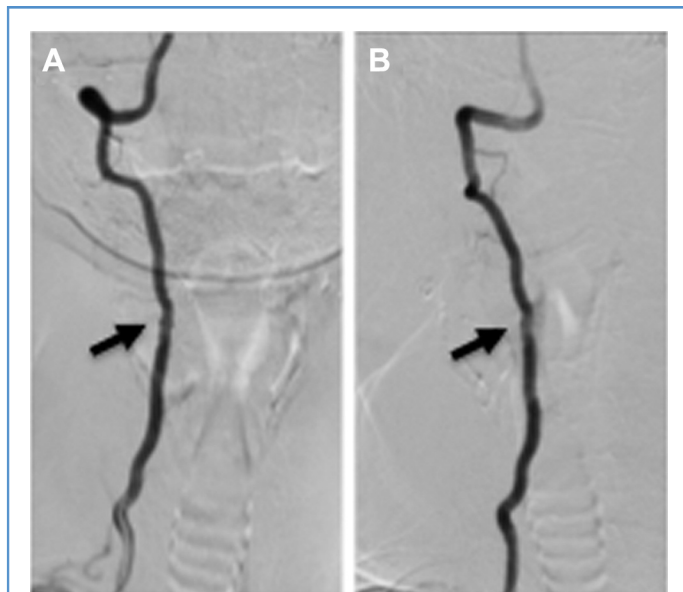
*Citation: World Neurosurg. (2016).*

*<http://dx.doi.org/10.1016/j.wneu.2016.11.071>*

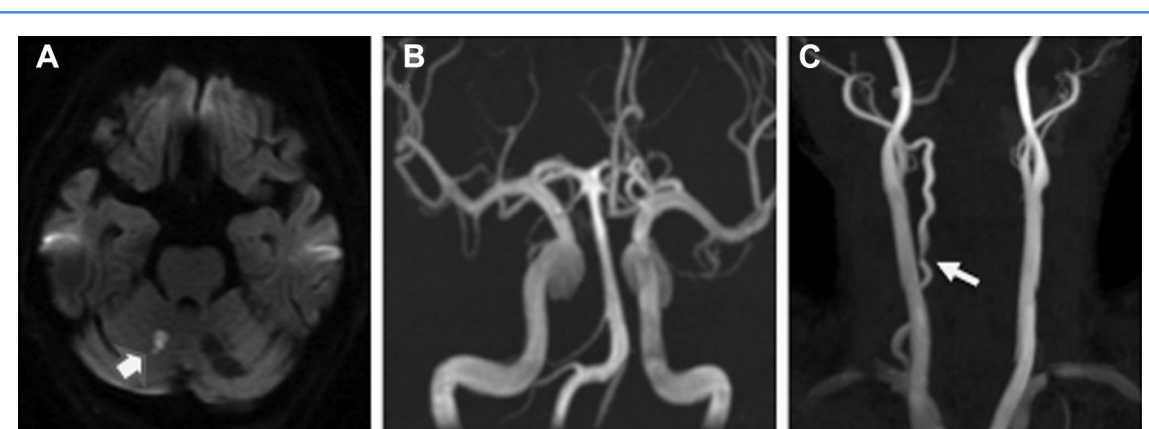
*Journal homepage: [www.WORLDNEUROSURGERY.org](http://www.WORLDNEUROSURGERY.org)*

*Available online: [www.sciencedirect.com](http://www.sciencedirect.com)*

*1878-8750/\$ - see front matter © 2016 Elsevier Inc. All rights reserved.*

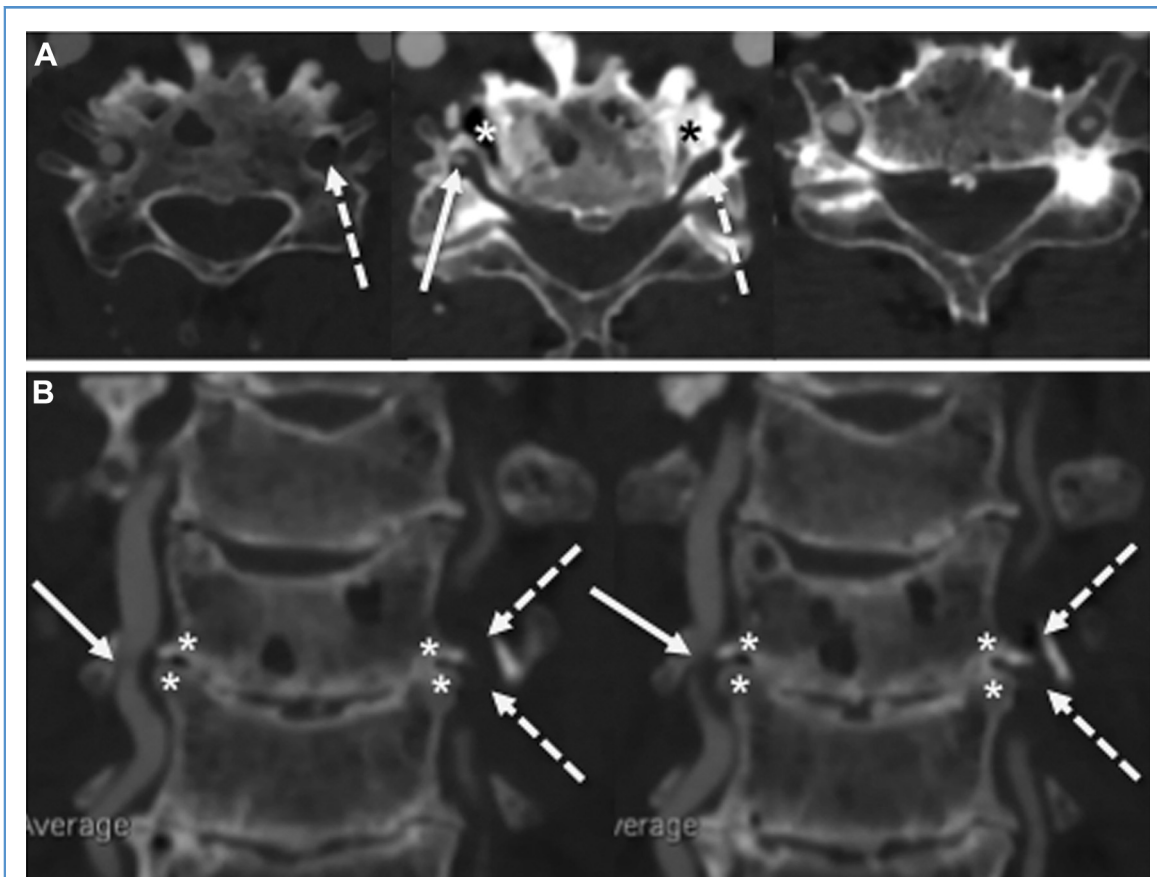


**Figure 5.** Postoperative dynamic right vertebral angiograms showing no stenosis with the patient's neck in a neutral position (A) and by neck rotation to the right (B).



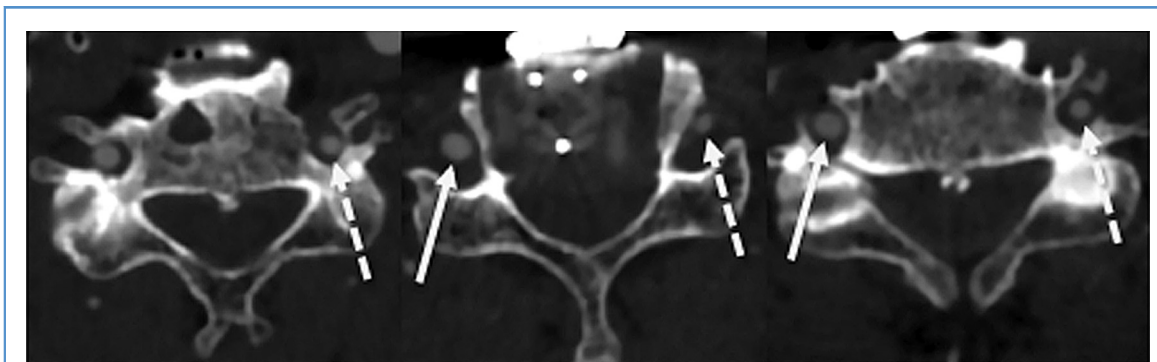
**Figure 6.** (A) Diffusion-weighted magnetic resonance image and magnetic resonance angiography of (B) intracranial and (C) extracranial cervical arteries at admission. Acute cerebral infarction is seen in the right superior cerebellar artery territory (*thick arrow*). There are no causative lesions in the intracranial

vertebrobasilar arteries, such as dissection and arteriosclerotic stenosis. However, in the extracranial portion, stenosis in the V2 portion of the right vertebral artery (*thin arrow*) and occlusion of the left vertebral artery are observed.



**Figure 7.** (A) Preoperative axial and (B) reconstructed coronal computed tomographic angiographic images. Uncovertebral osteophytes (*asterisks*) compress bilateral vertebral arteries at

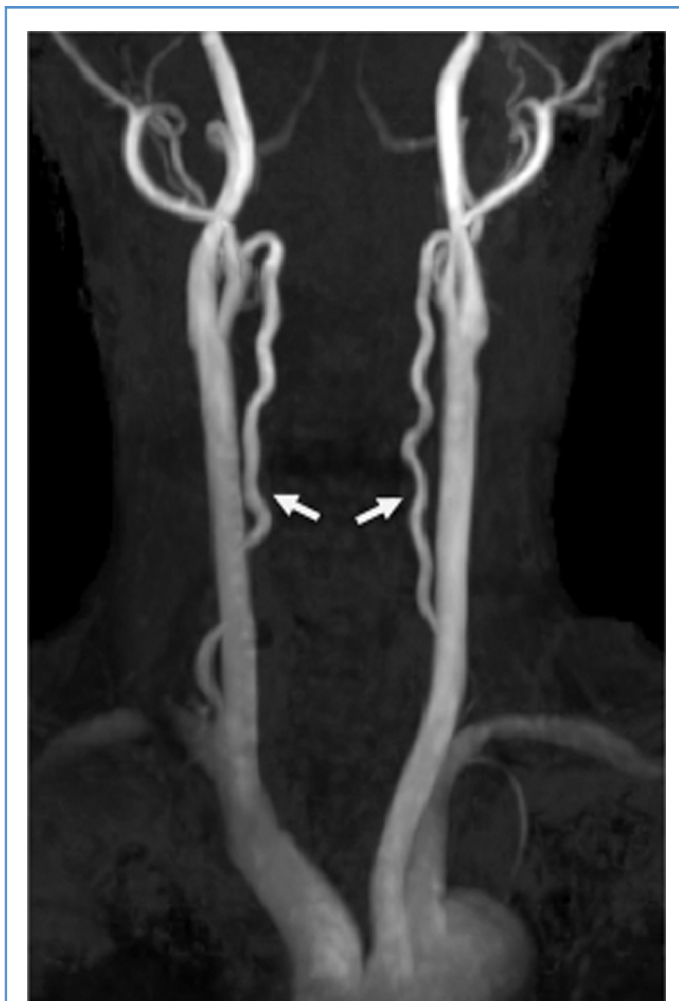C5-C6. The right vertebral artery is stenosed (*arrow*), whereas the left vertebral artery is segmentally invisible (*dotted arrow*).



**Figure 8.** Postoperative axial computed tomographic angiographic images showing enough decompression of

bilateral vertebral arteries at C5-C6 (right vertebral artery, *arrow*; left vertebral artery, *dotted arrow*).





**Figure 9.** Postoperative magnetic resonance angiography showing improved visualization of bilateral cervical vertebral arteries (*arrow*).