

Mesencephalic Hemorrhage —A Report of 3 Cases—

Seol Heui Han, M.D., Jae Kyu Roh, M.D., Ho-jin Myung, M.D.

Department of Neurology, College of Medicine, Seoul National University,

We studied three patients with spontaneous mesencephalic hemorrhages. All presented with some degree of impaired consciousness and abnormal ocular movements. One patient had a convergence-retraction nystagmus with a unilateral hemorrhage confined to the dorsal midbrain. Another patient showed left third nerve palsy due to a unilateral hemorrhage that involved ventral midbrain. The third patient revealed left internuclear ophthalmoplegia with ataxia due to a pinpoint hemorrhage in the tegmentum of the left midbrain. The patients survived and major neurologic deficits recovered, but abnormal ocular movements persisted.

Key Words: *Mesencephalic hemorrhage, Abnormal ocular movements, Impaired consciousness*

INTRODUCTION

Spontaneous mesencephalic hemorrhage is rare (Till, 1984), and this condition has not been well recognized as a distinct clinical entity until recently (Weisberg, 1986). Prior to the availability of the CT, the prognosis of brainstem hemorrhage had been held to be dismal. Since the advent of CT more benign cases have been described. Although the characteristic ocular findings could localize the lesion to the midbrain tegmentum in our cases, there were no useful symptoms or signs which would allow confident separations of small brainstem hemorrhages from ischemic brainstem lesions. Moreover it is critically important to differentiate the hemorrhagic condition from the ischemic processes in the management of the patients with brainstem stroke at the earliest stage. We report the clinical symptoms and CT findings of three patients with primary mesencephalic hemorrhage.

Address for Correspondence: *Seol Heui Han, M.D. Department of Neurology, College of Medicine, Seoul National University, 28 Yunkun-Dong, Chongno-Ku, Seoul 110-744, Korea (7601-2278)*

CASE REPORTS

Case 1

A 40-year-old normotensive alcoholic man suddenly developed a headache and blurring of vision while he was washing his hands. He became drowsy and vomited several times over the next few hours.

On admission, he was slightly lethargic but easily arousable and his blood pressure (BP) was 130/90 mmHg. Physical examination revealed some chronic liver disease stigmata with palpable liver edge (two finger breadth below right costal margin). Neurological examination revealed no definite motor weakness or signs of meningeal irritation. However, pain and thermal sensations were decreased in the left side; face was most densely involved and the arm was slightly more affected than the leg. But the vibratory sensation was intact. Tendon stretch reflexes were normal. Ophthalmologic examination was remarkable in that there were impaired upward gaze and convergence-retraction nystagmus on attempted upward gaze. The horizontal and downward gazes remained intact. Although the light reflex was hardly demonstrable, the near reflex was brisk. Both pupils were small

but isocoric.

The result of coagulation study and blood ammonia level was normal. A computed tomographic (CT) scan performed 4 days later disclosed a small non-enhancing hematoma, approximately 1.5cm in size, in the dorsolateral midbrain at the collicular level on the right side (Fig. 1). During the subsequent week,

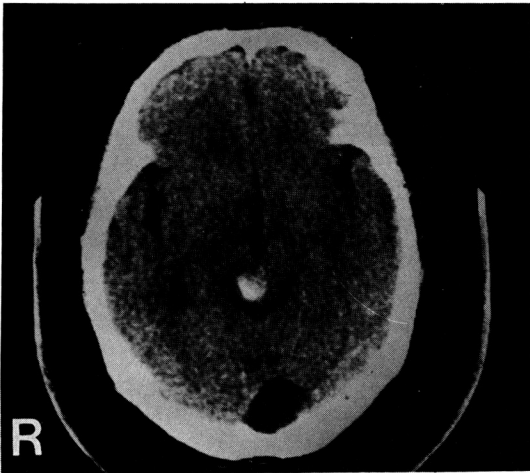

Fig. 1. CT demonstrates an area of hemorrhage in the dorsal midbrain lateralized to the right.

he regained consciousness fully, but the gaze disturbance persisted. CT performed 2 weeks later showed resolution of the hemorrhage.

Case 2

A 38-year-old hypertensive man was hospitalized

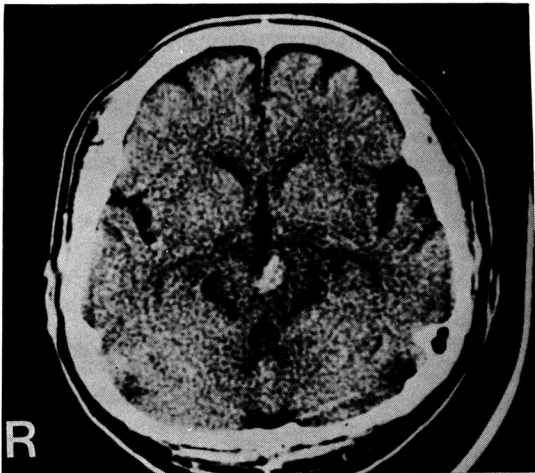


Fig. 2. Unenhanced CT reveals a high-density region in the left tegmentum of midbrain adjacent to the posterior third ventricle.

because of sudden onset of occipital headache and visual disturbance. He had vomited several times but did not complain of dizziness, weakness, or numbness.

On admission, his blood pressure was 150/110mmHg. He was well oriented, and memory was intact. The right pupil was 3mm, the left 6mm; the right pupil was briskly reactive to light, the left, fixed to light and accommodation. Vertical gaze was restricted, more marked on the left side. Although the horizontal gaze of right eye was intact the left eye showed medial gaze limitation and ptotic eyelid. The remainder of neurological examination was unremarkable. CT revealed a high-density area in the mesencephalon at the level of colliculus (Fig. 2). Magnetic Resonance Imaging (MRI) performed 6 days after CT scan disclosed an area of abnormal signal intensity compatible with hemorrhage in the upper midbrain. Four-vessel cerebral angiography revealed no vascular abnormality.

18 days later, CT showed resolution of the hemorrhage. 3 months after onset, the pupillary abnormality was partially recovered.

Case 3

A 49-year-old normotensive man noted an abrupt onset of diplopia, which was preceded by an occipital headache. He then developed unsteady gait and fluctuating somnolence.

On admission, his BP was 110/70mmHg. He was somnolent but easily arousable. Speech was dysarthric. There was no motor or sensory deficit. Ocular examination revealed a typical internuclear ophth-

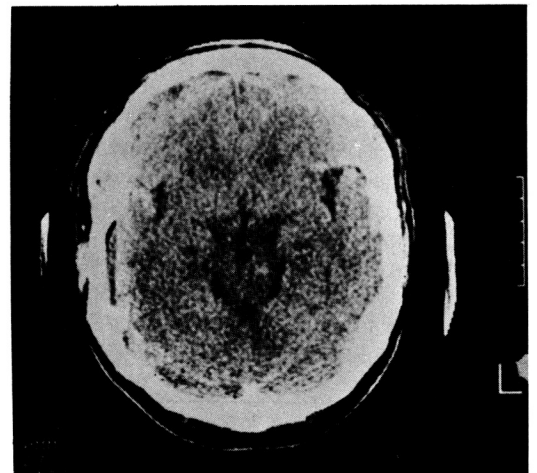


Fig. 3. CT defines a pinpoint left lower tegmental midbrain hemorrhage.

Table 1. Findings in three patients with mesencephalic hemorrhages

Case No	Age/Sex	Cardinal Features	CT	Risk Factor	Angiography	Outcome
1	40/M	Convergence-retraction	Lt. dorsal midbrain	Alcoholic chr. liver Ds	ND	Persisted EOM disturbance
2	38/M	Lt. 3rd N palsy	Rt. upper ventral midbrain	HT	Normal	Partial recovery of pupillary abnormality
3	49/M	INO ataxia	Lt. lower midbrain tegmentum	(?)	ND	Persisted EOM disturbance

INO: internuclear ophthalmoplegia, ND: not done

almoplegia (INO) on the left i.e., adduction of the left eye was not feasible beyond the midline. The abducting right eye showed jerky nystagmus. The convergence remained relatively intact. Pupils were isocoric, briskly reactive to light. Finger to nose and heel-knee-shin testing were definitely ataxic on the left. The gait was wide based and ataxic. The remainder of clinical examination was unremarkable. CT revealed a tiny area of abnormal high density in the left midbrain (Fig. 3). Over the ensuing week, gait ataxia was slightly improved. A second CT scan showed resolution of the hemorrhage.

When seen 6 months after the onset, gait ataxia was almost unnoticeable, but the INO persisted.

DISCUSSION

Spontaneous brainstem hemorrhage occurs most commonly in the pons where the basis pontis and tegmentum are usually involved (Silverstein, 1972). Isolated, non-traumatic mesencephalic hemorrhages have been only infrequently reported (Humphreys, 1978; Durward et al., 1982; Weisberg, 1986; Sand et al. 1986).

Most patients with brainstem hemorrhage have a grave prognosis and usually succumbed to death within the first 24 hours after the acute event (Silverstein, 1972). However, widespread use of CT has led to better recognition of non-fatal, relatively benign cases of brainstem hemorrhage (Drury et al., 1984; Del-Brutto et al., 1987).

All three patients in our series survived. Clinical features and CT findings are summarized in the table. Abnormal ocular movement was one of their salient clinical features. One had typical convergence-retraction nystagmus which was readily elicited by attempted up-gaze. Another showed left third nerve palsy. And the third patient revealed unilateral internuclear ophthalmoplegia (INO) which suggested the

involvement of medial longitudinal fasciculus (MLF). The MLF consists of fibers, many of which carry a conjugate horizontal eye movement command from abducens internuclear neurons to the medial rectus subdivision of the contralateral oculomotor nuclear complex. Lesions of the MLF produce INO. When the lesion is unilateral, the INO is characterized by weakness of the adducting eye to ipsilateral to the lesion and dissociated nystagmus of the abducting eye to the lesion (Crane et al., 1983). The first two patients showed somewhat limited vertical gaze especially on upward direction. These findings could help in localizing the lesion to the midbrain tegmentum (Christoff, 1974). Among the various abnormal ocular movements the convergence-retraction nystagmus is characterized by quick phases that converge and/or retract the eyes and it is usually caused by a lesion near or within the dorsal mesencephalon (Segara and Ojeman, 1961; Gay et al., 1969). It had been concluded from electromyographic data that this distinctive ocular movement results from synchronous innervation and therefore simultaneous contraction of all rectus muscles during each quick phase of nystagmus (Gay et al., 1969).

In addition to the visual disturbances, severe unusual headache of sudden onset with or without vomiting was noted in all patients. The altered level of consciousness such as fluctuating somnolence was thought to be due to the involvement of periaqueductal gray matter by hematoma itself and accompanied edema. But none of the patients showed complete loss of consciousness. In patient 3 who had an INO also showed left-sided limb ataxia. The responsible lesion was thought to be located in the dorsolateral portion of the mesencephalon, which might affect the superior cerebellar peduncle by pressure effect. Because the dentato-rubro-thalamic tract passes via the superior cerebellar peduncle, any lesion near this structure may cause this type of limb ataxia.

The etiology of these mesencephalic hemorrhages was not determined. None had an evidence of trauma or coagulation defects although one patient was alcoholic and had a chronic liver disease. In one patient (Case 2) whose four-vessel angiographic study revealed no tumor stain, aneurysm or vascular malformation, the lesion was thought to be either due to rupture of a cryptic vascular malformation or due to uncontrolled hypertension. Most midbrain vascular malformations occur in dorsal mesencephalon, are eccentric, but may cross the midsagittal line (McCormick et al., 1968; Durward et al., 1982). In our case 2 low field MRI demonstrated distinct hematoma without further information about the nature of the lesion. Recently Gomori et al (1986) demonstrated characteristic appearance of occult cerebral vascular malformations using the high-field MRI. These lesions typically consists of central foci of high-intensity signal, thought to be consistent with subacute or chronic hemorrhage, surrounded by a peripheral zone of low intensity, attributed most frequently due to the paramagnetic effect of hemosiderin deposition. They considered these findings as specific and virtually pathognomonic of cryptic vascular malformation.

The possible alternative causes of mesencephalic hemorrhage are vascular disease consequent upon chronic uncontrolled hypertension, or less likely, from hemorrhage into a pre-existent brainstem tumor. In our cases, except case 2, the patients were normotensive. In general, hypertensive vascular changes are rarely seen in the midbrain. The usual site of microaneurysms within the brainstem is the pons, hence the pons is the major site of spontaneous brainstem hemorrhage. Furthermore follow-up CT scans showed complete resorption of hematoma with no residual abnormal high or low densities and consequently brainstem tumor could be ruled-out. We believe that high-field MRI might have been of great help in elucidating further nature of hemorrhages in our cases.

The clinical course of our patients was characterized by spontaneous improvement. None experienced neurological deterioration or needed surgical intervention. Although some authors reported successful surgical evacuation of mesencephalic hematoma previously (La Torre et al., 1978; Humphreys, 1978), decisions regarding the management of the patient with a mesencephalic hemorrhage should be made after careful evaluation of the clinical condition of the patient. Unless impending brainstem compromise that may result from expanding hematoma or from hydrocephalus develops, treatment of patient with

mesencephalic hemorrhage should be conservative, i.e., supportive care, close clinical observation and management of precipitating factors such as hypertension and coagulation defects, should be in the first place.

In our cases, the clinical outcome was excellent, in that motor strength or coordination had eventually recovered, but ocular problems such as gaze limitation or pupillary abnormality did not resolve completely.

In summary all three patients showed typical mesencephalic localizing signs; upgaze limitation, convergence-retraction nystagmus, sluggish light reflex or INO with or without pupillary abnormality, and some degree of altered consciousness. CT could confirm the hemorrhages in the mesencephalon, and all patients had good recovery with conservative management.

REFERENCES

- Christoff N: *A clinicopathologic study of vertical eye movements. Arch Neurol* 31:1-8, 1974.
- Crane TB, Yee RD, Baloh RW, Hepler RS: *Analysis of characteristic eye movement abnormalities in internuclear ophthalmoplegia. Arch Ophthalmol* 101: 206-210, 1983.
- Del-Brutto OH, Noboa CA, Barinagarrementeria F: *Lateral pontine hemorrhage: Reappraisal of benign cases. Stroke* 18:954-956, 1987.
- Drury I, Whisnant JP, Garraway WM: *Primary intracerebral hemorrhage: Impact of CT on incidence. Neurology* 34:653-657, 1984.
- Durward QJ, Barnett HJM, Barr HWK: *Presentation and management of mesencephalic hematoma. J Neurosurg* 56:123-127, 1982.
- Gay AJ, Brodkey J, Miller JE: *Convergence-retraction nystagmus: An electromyographic study. Arch Ophthalmol* 70:453-458, 1963.
- Gomori JM, Grossman RI, Goldberg HI, Hackney DB, Zimmerman RA, Bilaniuk LT: *Occult cerebral vascular malformations: High-field MR imaging. Radiology* 158: 707-713, 1986.
- Humphreys RP: *Computerized tomographic definition of mesencephalic hematoma with evacuation through pedunculotomy. J Neurosurg* 49:749-752, 1978.
- La Torre E, Delitala A, Sorano V: *Hematoma of the quadrigeminal plate. J Neurosurg* 49: 610-613, 1978.
- McCormick WF, Hardman JM, Boulter TR: *Vascular malformations ("angiomas") of the brain, with special reference to those occurring in the posterior fossa. J Neurosurg* 28:241-251, 1968.

Sand JJ, Biller J, Corbett JJ, Adams HPJr, Dunn V: *Partial mesencephalic hemorrhages*. *Neurology* 36:529-533, 1986

Segara JM and Ojeman RJ: *Convergence nystagmus*. *Neurology* 11:883-893, 1961.

Silverstein A: *Primary pontine hemorrhage*. In: *Vinken PJ, Bruyn GW (eds): Handbook of Clinical Neurology, vol 12*. North: Holland Publishing Co, Amsterdam, pp 37-53,

1972.

Till JS: *Intracerebral hemorrhage*. In: *Toole JF (ed): Cerebrovascular disorders*. Raven Press, New York, pp 288-298, 1984.

Weisberg LA: *Mesencephalic hemorrhages: Clinical and computed tomographic correlations*. *Neurology* 36: 713-716, 1986.