



Case Reports

Adult supratentorial primitive neuroectodermal tumour presenting as intracranial haemorrhage: Case report



Sean P. Black-Tiong^a, Simon J.I. Sandler^a, Sophia Otto^b, Adam J. Wells^{a,*}

^a Department of Neurosurgery, Royal Adelaide Hospital, Adelaide, SA, Australia

^b SA Pathology, Royal Adelaide Hospital, Adelaide, SA, Australia

ARTICLE INFO

Article history:

Received 8 June 2016

Accepted 29 October 2016

Keywords:

Primitive neuroectodermal tumour
Supratentorial
Adult
Intracranial haemorrhage

ABSTRACT

Primitive neuroectodermal tumours (PNET) are highly malignant tumours with an aggressive clinical behaviour. Commonly seen in children, they are uncommon in the adult population, and rare in the supratentorial location. Adult supratentorial PNETs (ST-PNET) typically present with symptoms relating to raised intracranial pressure, seizures, or focal neurological deficits. Presentation with intracranial haemorrhage has been reported only twice before in the literature, one of which was fatal. We report the case of intracranial haemorrhage secondary to ST-PNET in a young adult and her immediate management.

Crown Copyright © 2016 Published by Elsevier Ltd. All rights reserved.

1. Introduction

Primitive neuroectodermal tumours (PNET) are a highly malignant tumour with an aggressive clinical behaviour [1]. They are most commonly seen in children, accounting for 2.5–3% of paediatric CNS tumours, however are exceedingly rare in the adult population and represent less than 0.5% of all intracranial tumours [2]. A supratentorial location (ST-PNET) is well documented in the adult population, with the majority of patients presenting with symptoms and signs attributable to raised intracranial pressure (ICP), seizures, or focal neurological deficit [1,2]. Presentation with intracranial haemorrhage is rare, and has been reported in the literature only twice before, with one case proving fatal [3,4]. We describe the clinical course of a young woman presenting with intracranial haemorrhage secondary to ST-PNET.

2. Case report

A 28-year-old woman of Japanese origin presented with sudden onset headache, vomiting and right sided hemiparesis. She was oriented and obeying commands and had a dilated left pupil. Her speech was slurred. A Computerised Tomography (CT) head scan demonstrated a 5.6 cm left posterior frontal intracerebral haemorrhage with no associated vascular pathology or contrast enhancement (Fig. 1). A craniotomy was performed to evacuate the haematoma, and an area of abnormal tissue was identified at the antero-medial wall of the haematoma cavity which was biopsied

and processed for histopathological analysis. The patient made a good post-operative recovery with improvement in her left sided proximal limb strength to 3/5 power.

Histopathological examination demonstrated a malignant tumour with monotonous small round cell pattern, and round to ovoid nuclei with salt and pepper chromatin and small or inconspicuous nucleoli (Fig. 2). Pseudo-rosettes (Fig. 2A) and true Homer-Wright rosettes (Fig. 2B) were identified. Immunohistochemistry was positive for GFAP, synaptophysin, CD56 nestin, S100 and INI-1, but negative for NeuN, NFP, CD45, HMB45 and desmin. FISH for EWS translocation was negative suggestive of central nervous system PNET rather than intracranial peripheral PNET.

The patient was transferred to a rehabilitation facility for limb strengthening and mobility assistance. A Magnetic Resonance Imaging (MRI) performed on day 7 demonstrated no evidence of residual tumour (Fig. 3), and imaging of the remainder of her neuraxis revealed no spinal disease. She was treated with adjuvant chemo-radiation therapy, initially with 36 Gy cranio-spinal irradiation with an 18 Gy boost to the tumour bed (total 54 Gy over 6 weeks). She subsequently received 6 cycles of lomustine, cisplatin and vincristine therapy. She then elected to return to Japan for ongoing management and rehabilitation.

3. Discussion

Adult ST-PNETs are uncommon tumours with a generally aggressive course despite adjuvant therapy (1). Only two cases of ST-PNET presenting with intracranial haemorrhage have been reported in the literature. Papadopoulos et al. described a 42-year-old man who developed headache and vomiting, then

* Corresponding author at: Department of Neurosurgery, Royal Adelaide Hospital, North Terrace, Adelaide, SA 5000, Australia. Fax: +61 8 8222 5886.

E-mail address: adam.wells@sa.gov.au (A.J. Wells).

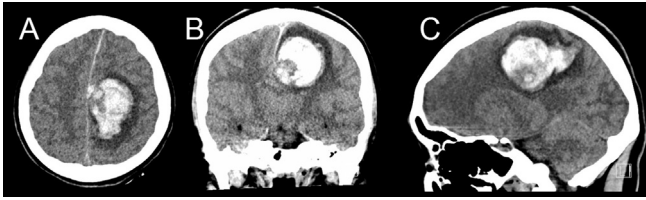


Fig. 1. Pre-operative non-contrast CT scan demonstrating left posterior frontal intracerebral haematoma adjacent to the falx cerebri and with significant local mass effect. A, axial; B, coronal; C, sagittal.

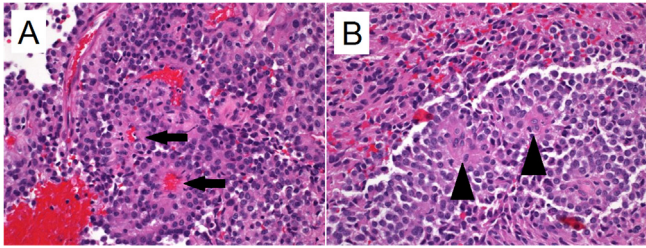


Fig. 2. Photomicroscopy, H&E stain, magnification $\times 40$. Salt and pepper chromatin with small or inconspicuous nucleoli. A, pseudorosette formation (black arrows); B, Homer-Wright rosettes (arrow heads).

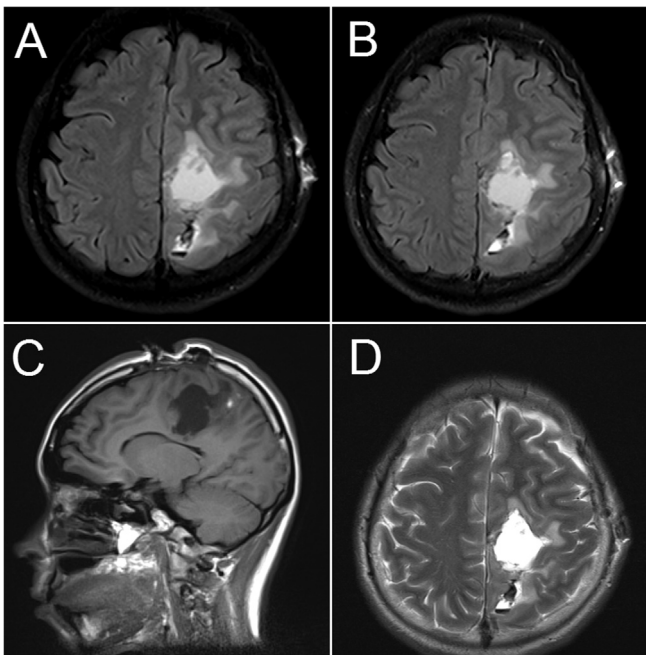


Fig. 3. Post-operative MRI scan. Axial FLAIR sequence pre- (A) and post-contrast (B). C, T1WI sagittal sequence; D, T2WI axial.

presented to hospital comatose (3). CT demonstrated a large right frontal haematoma with perilesional oedema, significant mass effect and tonsillar herniation. Pupils were bilaterally fixed and dilated pre-operatively; a left frontal ventricular drain and right frontal perilesional ICP monitor were inserted, then the patient was returned to the operating theatre for haematoma evacuation and bilateral decompressive craniectomy secondary to raised ICP. Specimens of abnormal peri-haematoma tissue were consistent with PNET on histology. The patient had persistently raised ICP post-operatively and died from multi-organ failure on day 2.

Abuzayed et al. treated a 24-year-old woman who presented with vomiting, brief loss of consciousness and left sided weakness (4). A right frontal intracerebral haematoma with perilesional oedema was demonstrated on CT; she was initially commenced on dexamethasone with improvement of her weakness, then proceeded to craniotomy after an MRI demonstrated contrast enhancement at the periphery of the haematoma, concerning for malignancy. She made a good post-operative recovery without complication. Histopathology confirmed PNET, there was no evidence of spinal seeding on MRI or cerebrospinal fluid analysis, and she was referred for craniospinal irradiation and chemotherapy.

Although a rare presentation of a rare tumour, consideration of underlying malignancy should be given to young adults presenting with intracranial haemorrhage, particularly when abnormal tissue is encountered in the haematoma cavity intra-operatively. Without histological diagnosis a tumour can be overlooked, delaying adjuvant therapy and potentially hastening disease recurrence and shortening overall survival, especially in high grade tumours such as PNET.

References

- [1] Kim DG, Lee DY, Paek SH, et al. Supratentorial primitive neuroectodermal tumors in adults. *J Neurooncol* 2002;60:43–52.
- [2] Louis DN, Ohgaki H, Wiestler OD, et al. The 2007 WHO classification of tumours of the central nervous system. *Acta Neuropathol* 2007;114:97–109.
- [3] Papadopoulos EK, Fountas KN, Brotis AG, et al. A supratentorial primitive neuroectodermal tumor presenting with intracranial hemorrhage in a 42-year-old man: a case report and review of the literature. *J Med Case Rep* 2013;7:86–91.
- [4] Abuzayed B, Khreisat W, Maaiah W, et al. Supratentorial primitive neuroectodermal tumor presenting with intracranial hemorrhage in adult. *J Neurosci Rural Pract* 2014;5:176–9.