

Accepted Manuscript

Successful coil embolization of pediatric carotid cavernous fistula due to ruptured post-traumatic giant internal carotid artery aneurysm

Daisuke Wajima, Ichiro Nakagawa, Hun Soo Park, Shohei Yokoyama, Takeshi Wada, Kimihiko Kichikawa, Hiroyuki Nakase

PII: S1878-8750(16)31285-2

DOI: [10.1016/j.wneu.2016.11.137](https://doi.org/10.1016/j.wneu.2016.11.137)

Reference: WNEU 4947

To appear in: *World Neurosurgery*


Received Date: 5 October 2016

Revised Date: 25 November 2016

Accepted Date: 26 November 2016

Please cite this article as: Wajima D, Nakagawa I, Park HS, Yokoyama S, Wada T, Kichikawa K, Nakase H, Successful coil embolization of pediatric carotid cavernous fistula due to ruptured post-traumatic giant internal carotid artery aneurysm, *World Neurosurgery* (2017), doi: 10.1016/j.wneu.2016.11.137.

This is a PDF file of an unedited manuscript that has been accepted for publication. As a service to our customers we are providing this early version of the manuscript. The manuscript will undergo copyediting, typesetting, and review of the resulting proof before it is published in its final form. Please note that during the production process errors may be discovered which could affect the content, and all legal disclaimers that apply to the journal pertain.



Successful coil embolization of pediatric carotid cavernous fistula due to ruptured post-traumatic giant internal carotid artery aneurysm.

Authors: Daisuke Wajima¹, Ichiro Nakagawa¹, Hun Soo Park¹, Shohei Yokoyama¹, Takeshi Wada², Kimihiko Kichikawa², Hiroyuki Nakase¹

Affiliation:

1: Department of Neurosurgery, Nara Medical University

2: Department of Radiology, Nara Medical University

Corresponding author: Daisuke Wajima M.D, PhD

Affiliation: Department of Neurosurgery, Nara Medical University

Address: Shijo-cho 840, Kashihara, Nara, 634-8522, Japan

E-mail: wajima@naramed-u.ac.jp

Tel: +81-744-22-3051, Fax: +81-744-29-0818

No authors have any grant supports from any groups or companies.

Abstract

Background: The goal of the treatment of direct carotid cavernous fistula (CCF) is to occlude the arteriovenous shunt and to preserve the patency of the concerned internal carotid artery (ICA). However, for the ipsilateral post-traumatic fragile cerebrum, coil embolization plus parent artery occlusion for the high flow direct CCF would be better for the prevention of hyper-perfusion syndrome and the intracranial hemorrhage. We experienced such a case and managed it successfully.

Case Description: A 6-year-old boy was suffered from severe head trauma caused by being hit by a car. He was transferred to our department and diagnosed as left acute subdural hematoma and acute brain swelling. Emergent evacuation of hematoma and external decompression was performed. He was cured for the severe brain swelling in intensive care unit (ICU) for 2 months. Cranioplasty was performed 3 months after the injury. His right hemi-paresis and aphasia were persisted, so he was transferred to a rehabilitation hospital. However, 2 years after the head injury, he was referred to our department for his abducens nerve palsy. He was diagnosed as a symptomatic post-traumatic direct CCF, which was caused by ruptured left cavernous giant ICA aneurysm. The direct CCF was treated with coil embolization of the giant aneurysm and parent artery occlusion.

Conclusions: Coil embolization of the aneurysm and parent artery occlusion for the post-traumatic direct CCF was a good option to manage the abducens nerve palsy and the prevention of post-operative hyperperfusion.

(238 words)

Highlight

- A 8-year-old boy was diagnosed as a symptomatic post-traumatic direct carotid cavernous fistula (CCF), which was caused by ruptured left cavernous giant ICA aneurysm.
- The direct CCF was treated with coil embolization of the giant aneurysm and parent artery occlusion.
- For the ipsilateral post-traumatic fragile cerebrum, coil embolization plus parent artery occlusion for the high flow direct CCF would be better for the prevention of hyper-perfusion syndrome and the intracranial hemorrhage.

Introduction

Carotid cavernous fistula (CCF) in general represent an abnormal communication between the internal and/or external carotid arteries and the cavernous sinus, resulting in venous congestion of the cavernous sinus and the adjacent veins and sinuses¹⁻⁴. The goal of the treatment of direct CCF is to occlude the arteriovenous shunt and to preserve the patency of the concerned internal carotid artery (ICA). When there is insufficient collateral supply from contra-lateral vessels, ICA preservation must be prioritized, and this may be obtainable with endovascular intervention alone⁴. However, we note a recent report about a patient with postoperative lethal intracranial hematoma due to hyper-perfusion syndrome after shunt obliteration of an ICA high-flow fistula with preservation of parent artery flow¹.

Herein we report a case of direct CCF caused by a ruptured post-traumatic left giant ICA aneurysm in a patient who presented with left abducens nerve palsy 2 years after severe head trauma due to being hit by a car. We successfully performed coil embolization with parent artery occlusion (PAO) and the patient's abducens nerve palsy resolved without complications.

Case Report

A 6-year-old boy was suffered from severe head trauma caused by being hit by a car. He was transferred to our department and diagnosed as with left acute subdural hematoma and acute brain swelling (Fig 1-A,B). He was comatose but had no anisocoria, and his vital sign were stable. Emergent evacuation of the hematoma and external decompression was performed. The severe brain swelling resolved after treatment in an intensive care unit (ICU) for 2 months. Cranioplasty was performed 3

months after the injury. His right hemiparesis and aphasia were persisted, and he was transferred to a rehabilitation hospital (Fig 1-C). There were no findings of intracranial aneurysm on computed tomography (CT) of the head at that point.

Two years after the head injury, he was referred to our department for his an abducens nerve palsy. His head CT without contrast showed a large mass in his left middle temporal fossa (Fig 1-D). Three-dimensional CT angiography (3D-CTA) and digital subtraction angiography (DSA) showed a ruptured giant ICA aneurysm and direct arteriovenous fistula draining to superior petrosal sinus (SPS) and basal vein (Fig 1-E, Fig 2-A,B). In addition, left ICA angiogram (ICAG) showed no antegrade flow distal to ICA cavernous portion (Fig 2-A,B). There was no findings of arteriovenous fistulas on left external carotid artery angiograms (ECAG) (Fig 2-C,D). Collateral flow via the anterior communicating artery (A-com A) (Fig 2-E) and posterior communicating artery (P-com A) to the left ICA territory was confirmed (Fig 2-F), and the distance from the distal neck of the aneurysm to the left ophthalmic artery was very short, i.e., less than 10mm. Head magnetic resonance image (MRI) showed left cerebral brain atrophy, and there was a possibility of intracranial hemorrhage due to hyperperfusion after obliteration of the high-flow CCF preserving parent artery flow because the ipsilateral brain was very susceptible to the sudden hemodynamic change. He was diagnosed as a symptomatic post-traumatic direct CCF caused by ruptured of a giant left cavernous ICA aneurysm. We determined that the direct CCF would need to be eliminated for improvement of left abducens nerve palsy.

We planned the coil embolization with parent artery occlusion for the direct CCF due to ruptured giant ICA dissecting aneurysm. Under general anesthesia, a 6-French Destination guiding catheter (TERUMO, Tokyo, Japan) was introduced to left ICA C5

portion via right femoral artery (Fig 3-A). After the introduction of Sceptor C 4mm×10mm balloon catheter (TERUMO, Tokyo, Japan) to the neck of the aneurysm (Fig 3-B), coil embolization of the aneurysm and parent artery occlusion were performed with the double catheter technique with the Excelsior SL-10 STR (Boston Scientific, Massachusetts, USA) and SL-10 pre-shaped 45° (Boston Scientific, Massachusetts, USA) (Fig 3-C). Shunt points of the fistula were observed in the posterior portion of the giant aneurysmal dome. Coil embolization was performed in the aneurysmal dome, not in the part of the cavernous sinus outside the dome. We aimed not only to promote recovery of the abducens nerve function, avoiding direct coil mass compression to the nerve, but also to avoid occluding the drainage route in early phase of treatment for the prevention of intracranial hematoma due to high pressure in the cavernous sinus. Finally, PAO was performed distal to the C5 portion of the ICA, proximal to the orifice of left ophthalmic artery, for the prevention of intracranial hemorrhage due to hyperperfusion syndrome.

Postoperative DSA confirmed complete obliteration of the direct CCF shunts, rough packing for the preservation of abducens nerve near the Dorello's canal (Fig 3-D), and the intact patency of left ophthalmic artery and P-com A (Fig 3-E), and his abducens nerve palsy resolved immediately after the procedure, without any perioperative ischemic or hemorrhagic complications (Fig 3-F,G).

Discussion

According to the Barrow classification, CCFs are subdivided into four different types, depending on flow rates, etiology, and source of feeding vessels. Direct CCF are generally characterized by an abnormal arteriovenous communication between ICA and

the ipsilateral cavernous sinus^{2,3}. Direct CCF are typically due to a severe blunt or penetrating head trauma³. Less frequently, they occur spontaneously in the context of vessel wall connective tissue disease (e. g., Ehlers Danlos syndrome) or after rupture of a preexisting cavernous ICA aneurysm⁴⁻⁶ or as a complication following skull base surgery or endovascular procedures adjacent to the cavernous segment of the ICA (e. g., balloon angioplasty or stent placement)⁷⁻¹¹. In our case, the direct CCF occurred as a result of the rupture of a post-traumatic giant ICA aneurysm, which was unlikely to be the typical direct CCF as the Barrow classification in the point that the duration between the CCF and the head trauma was very long. In addition, pediatric post-traumatic CCF is very rare, with most cases reported in adolescences and older adults¹⁻¹¹. We reviewed three such cases reported in the English literature (Table 1). These cases occurred within 2 months after injury and were managed with transvenous embolization with coils. All cases, including our case, had good outcome. The goal of the treatment of direct CCF is to occlude the arteriovenous shunt and to preserve patency of the concerned ICA; however, in our case, direct CCF occlusion of the arteriovenous shunt as well as PAO were required to avoid intracranial hemorrhage due to sudden hemodynamic stress in the ipsilateral ICA territory, which severely damaged after head trauma. In addition, we performed balloon occlusion test (BOT) with the Sceptor C balloon catheter under the sedation with Precedex[®] infusion and motor evoked potential (MEP) monitoring. No significant MEP wave changes during the BOT. So we decided it was possible to perform PAO for the ruptured post-traumatic aneurysm.

Historically, endovascular treatment strategies via transvenous or transarterial access routes included the use of detachable balloons¹⁵, coils¹⁶⁻¹⁸, covered stents^{19, 20}, and liquid embolic agents^{21, 22}. Silicon detachable balloons were widely used for the

treatment of direct CCF over many years, until their unexpected withdrawal from the market in 2004. However, there is one report of a detachable balloon that was inadequate for the treatment of CCF due to the rupture of a giant aneurysm, similar to our case²³. Today, detachable coils are frequently used. The complication rates of endovascular embolization for CCF were different on various centers. Other authors showed that permanent complication of cerebral infarction is less than 2%¹⁸. Permanent cranial nerve palsy after the procedure occurred in 0-5%¹⁵. Death also was reported at 1.8 to 3%¹⁸. The advantage of endovascular intervention was the possible preservation of the internal carotid artery which was approximately 70% of cases¹⁸.

The standard treatment protocol for direct CCF is to occlude the fistula and preserve the ICA. However, one review reported four cases with cerebral hyperperfusion syndrome due to blood flow rerouting into the cerebral parenchyma during endovascular management in the head and neck region²⁴. Of those cases, one patient died secondary to acute focal edema and delayed intracranial hemorrhage after stent grafting for carotid-jugular fistula, and two patients experienced acute intracerebral hemorrhage after stent grafting with coils for CCF. In our case, the left cerebral hemisphere was considered to be fragile after severe head trauma, and we were concerned about intracerebral hemorrhage due to hyperperfusion syndrome if we chose to treat the direct CCF with preservation of left ICA parent flow. Therefore, we performed shunt obliteration of the direct CCF with PAO without any peri-procedural complications.

The PAO without intra-aneurysmal packing or sinus packing is another treatment option for the direct CCF; however, one author reported the possibility of incomplete shunt obliteration²⁵. For that reason, it may be better to perform both aneurysmal coil embolization and PAO if it is difficult to obtain enough distal part of arterial distance for

PAO only. In the present case, we performed aneurysmal coil embolization including PAO because the distal margin of parent artery was too short to accomplish complete PAO and, in addition, it would be difficult to access the shunt point again, once simple PAO was performed.

Due to the complex anatomy of the cavernous sinus, a transvenous approach to direct CCF harbors the risk of incomplete fistula occlusion and thereby aggravation of venous pressure within the orbital or cortical veins. In addition, new channels to open after outflow occlusion by the transvenous approach, which could increase the risk of intracranial hemorrhage^{23,26}. Moreover, periprocedural protrusion of coil loops in the parent ICA could lead to thromboembolic events or even inadvertent occlusion of the ICA²⁵. In the present case, we selected transarterial approach so as not to occlude the drainage route in early phase of the treatment for the prevention of intracranial hematoma due to the high pressure in the cavernous sinus.

The use of liquid embolic agents such as Histoacryl (B. Braun, Germany), Onyx (Medtronic, United States of America), or others for the treatment of direct CCF involves the injection of these agents into the cavernous sinus. Uncontrolled propagation of the embolic agent, the unintended occlusion of efferent veins, and injury to the cranial nerves in the wall of the cavernous sinus are reported complications^{27,28}.

A long-term outcome study showed the dense packing of the cavernous sinus for CCFs provided reliable regression of acute symptoms after coil embolization of 19 fistulae (13 direct and 9 dural CCFs)¹⁶. Nevertheless, 44% of the patients had persistent cranial nerve deficits with disturbances of oculomotor and visual functions. The authors ascribed these persisting deficits to the underlying fistula size itself and/or the space-occupying effect of the coils, as there was a statistically significant correlation

observed between coil volume and persistent diplopia and cranial nerve paresis¹⁵. To reduce the space-occupying effect of the coils, targeted occlusion of the fistulous compartment of the cavernous sinus became an option. In our case, we carefully performed coil embolization for the giant aneurysm by packing the coils within the aneurysmal dome, being careful not to pack the coils in the posterior part of cavernous sinus outside the dome, which may have compressed directly on the abducens nerve near Dorello's canal. Indeed, PAO without cavernous sinus packing is generally better for the prevention of cranial nerve palsy. However, it was difficult to obtain complete obliteration of the CCF only PAO because of short distal segment for PAO in our case. We believed it would be better to perform PAO with intra-aneurysmal coil embolization for the preservation of cranial nerve functions.

Conclusion

Endovascular intervention has been currently a treatment of choice for direct traumatic CCF because of its high cured rate, ability to preserve the carotid artery, and flexibility in gaining various access points to the fistulous sites. In our case, we performed aneurysm coil embolization with PAO for treatment of a direct CCF caused by the rupture of a post-traumatic ICA giant aneurysm. There was a need for coil embolization within the giant aneurysm for the preservation of abducens nerve and to prevent occlusion of the drainage route in the early phase of treatment for the prevention of intracranial hematoma. In addition, coil embolization plus PAO for high-flow direct CCF was better for the prevention of hyperperfusion syndrome and the intracranial hemorrhage in the ipsilateral post-traumatic fragile cerebrum.

References

1. Mondel PK, Udare AS, Anand S, Kulkarni AV, Kapadia FN, Modhe JM, Limaye US. Cerebral hyperperfusion syndrome after endovascular reconstruction of carotid artery in high-flow carotid-jugular fistula. *Cardiovasc Intervent Radiol.*2014;37(5):1369-75
2. Lewis AI, Tomsick TA, Tew JM Jr. Management of 100 consecutive direct carotid-cavernous fistulas: results of treatment with detachable balloons. *Neurosurgery.*1995;36(2):239-244
3. Naesens R, Mestdagh C, Breemers M, Defreyne L. Direct carotid-cavernous fistula: a case report and review of the literature. *Bull Soc Belge Ophtalmol.* 2006;(299):43-54
4. Gemmete JJ, Ansari SA, Gandhi D. Endovascular treatment of carotid cavernous fistulas. *Neuroimaging Clin N Am.*2009;19:241–55
5. Nakagawa I, Park HS, Wada T, Takayama K, Nakagawa H, Kichikawa K, Nakase H. A novel approach to the treatment of a direct carotid-cavernous fistula in a patient with Ehlers-Danlos syndrome type IV. *J Neurointerv Surg.*2016;8(1):e2
6. van Rooij WJ, Sluzewski M, Beute GN. Ruptured cavernous sinus aneurysms causing carotid cavernous fistula: incidence, clinical presentation, treatment, and outcome. *AJNR Am J Neuroradiol.*2006;27:185–9
7. Kalia JS, Niu T, Zaidat OO. The use of a covered stent graft for obliteration of high-flow carotid cavernous fistula presenting with life-threatening epistaxis. *J Neurointervent Surg.*2009;1:142–5
8. Pedersen R, Troost B, Schramm V. Carotid-cavernous sinus fistula after external ethmoid-sphenoid surgery. Clinical course and management. *Arch Otolaryngol.*

- 1981;107:307–9
9. Takahashi M, Killeffer F, Wilson G. Iatrogenic carotid cavernous fistula (case report). *J Neurosurg.* 1969;30:498–500
 10. Park HR, Yoon SM, Shim JJ, Bae HG, Yun IG. Iatrogenic carotid cavernous fistula after stent assisted coil embolization of posterior communicating artery aneurysm. *J Cerebrovasc Endovasc Neurosurg.* 2015;17:43–8
 11. Yoon WK, Kim YW, Kim SR, Park IS, Kim SD, Baik MW. Transarterial coil embolization of a carotid-cavernous fistula which occurred during stent angioplasty. *Acta Neurochir.* 2009;151:849–53
 12. Yang Y, Kapasi M, Abdeen N, Dos Santos MP, O'Connor MD. Traumatic carotid cavernous fistula in a pediatric patient. *Can J Ophthalmol.* 2015;50(4):318-21.
 13. Paiva WS, de Andrade AF, Beer-Furlan A, Neville IS, Noleto GS, Bernardo LS, Caldas JG, Teixeira MJ. Traumatic carotid-cavernous fistula at the anterior ascending segment of the internal carotid artery in a pediatric patient. *Childs Nerv Syst.* 2013;29(12):2287-90.
 14. Pawar N, Ramakrishnan R, Maheshwari D, Ravindran M. Acute abducens nerve palsy as a presenting feature in carotid-cavernous fistula in a 6-year-old girl. *GMS Ophthalmol Cases.* 2013;3:Doc03.
 15. Xu XQ, Liu S, Zu QQ, Zhao LB, Xia JG, Zhou CG, Zhou WZ, Shi HB. Follow-up of 58 traumatic carotid-cavernous fistulas after endovascular detachable-balloon embolization at a single centre. *J Clin Neurol.* 2013;9:83–90
 16. Bink A, Goller K, Luchtenberg M, Neumann-Haefelin T, Dützmänn S, Zanella F, Berkefeld J, du Mesnil de Rochemont R. Long-term outcome after coil embolization of cavernous sinus arteriovenous fistulas. *AJNR Am J Neuroradiol.*

- 2010;31:1216–21
17. Luo C, Teng M, Lin C, Yen D, Chang F, Chang C. Transarterial embolization of traumatic carotid-cavernous fistulae by Guglielmi detachable coils. A seven-year experience. *Interv Neuroradiol.*2008;2:5–8
 18. De Renzis A, Nappini S, Consoli A, Renieri L, Limbucci N, Rosi A, Vignoli C, Pellicano G, Magiafico S. Balloon-assisted coiling of the cavernous sinus to treat direct carotid cavernous fistula. A single center experience of 13 consecutive patients. *Interv Neuroradiol.*2013;19:344–52
 19. Briganti F, Tortora F, Marseglia M, Napoli M, Cirillo L. Covered stent implantation for the treatment of direct carotid-cavernous fistula and its mid-term follow-up. *Interv Neuroradiol.*2009;15:185–90
 20. Li K, Dho YD, Kim KM, Kang HS, Kim JE, Hand MH. Covered stents for the endovascular treatment of a direct carotid cavernous fistula: Single center experiences with 10 cases. *J Korean Neurosurg Soc.*2014;57:12–8
 21. Barber SM, Rangel-Castilla L, Zhang YJ, Klucznik R, Diaz O. Midand long-term outcomes of carotid-cavernous fistula endovascular management with Onyx and n-BCA: experience of a single tertiary center. *J Neurointervent Surg.*2014;7:762–9
 22. Luo CB, Teng MM, Chang FC, Chang CY. Trans-arterial balloon-assisted n-butyl-2-cyanoacrylate embolization of direct carotid cavernous fistulas. *AJNR Am J Neuroradiol.*2006;27:1535–40
 23. Goto K, Hieshima GB, Higashida RT et al. Treatment of direct carotid cavernous sinus fistulae-Variou therapeutic approaches and results in 148 cases. *Acta Radiologica.*1986;369:576-579
 24. Mondel PK, Udare AS, Anand S, Kulkarni AV, Kapadia FN, Modhe JM, Limaye US.

- Cerebral hyperperfusion syndrome after endovascular reconstruction of carotid artery in high-flow carotid-jugular fistula. *Cardiovasc Intervent Radiol.* 2014;37(5):1369-75
25. Chi CT, Nguyen D, Duc VT, Chau HH, Son VT. Direct traumatic carotid cavernous fistula: angiographic classification and treatment strategies. Study of 172 cases. *Interv Neuroradiol.* 2014;20(4):461-75
26. Nakagawa I, Wada T, Nakagawa H, Hironaka Y, Kichikawa K, Nakase H. A rare brainstem hemorrhage during transvenous embolization of a cavernous dural arteriovenous fistula. *J Clin Neurosci.* 2012;19(4):589-92
27. Elhammady MS, Wolfe SQ, Farhat H, Moftakhar R, Aziz-Sultan MA. Onyx embolization of carotid-cavernous fistulas. *J Neurosurg.* 2010;112:589–94
28. Zenteno M, Santos-Franco J, Rodriguez-Parra V, Balderrama J, Alburto-Murrieta Y, Vega-Montesinos S, Lee A. Management of direct carotid-cavernous sinus fistulas with the use of ethylenevinyl alcohol (Onyx) only: preliminary results. *J Neurosurg.* 2010;112:595–602

Figure legends

Fig 1. The patient's initial non-contrast computed tomography (CT) of the head showed left acute subdural hematoma and acute brain swelling (Fig 1-A: axial view, B: coronal view). Head CT 3 months after head trauma, showing atrophy of the left brain (Fig 1-C). Head CT 2 years after head trauma showed a large mass in his left temporal middle fossa (Fig 1-D). Three-dimensional CT angiography (3D-CTA) showed a dissecting large internal carotid artery (ICA) aneurysm (Fig 1-E).

Fig 2. Left carotid artery angiogram (CAG) showed a dissecting large internal carotid artery (ICA) aneurysm and arteriovenous shunt draining to superior petrosal sinus (SPS) and basal vein, which was diagnosed as the direct CCF secondary to rupture of a giant ICA aneurysm (Fig 2-A: anterior-posterior (AP) view, B: lateral (Lat) view). Left external CAG showing no arterial-venous shunts (Fig 2-C: AP view, D: Lat view). Right CAG showing good circulation to the left ICA region via anterior communicating artery (A-com A) (Fig 2-E) Left vertebral angiogram showing good collateral flow to the left ICA region via left posterior communicating artery (Fig 2-F).

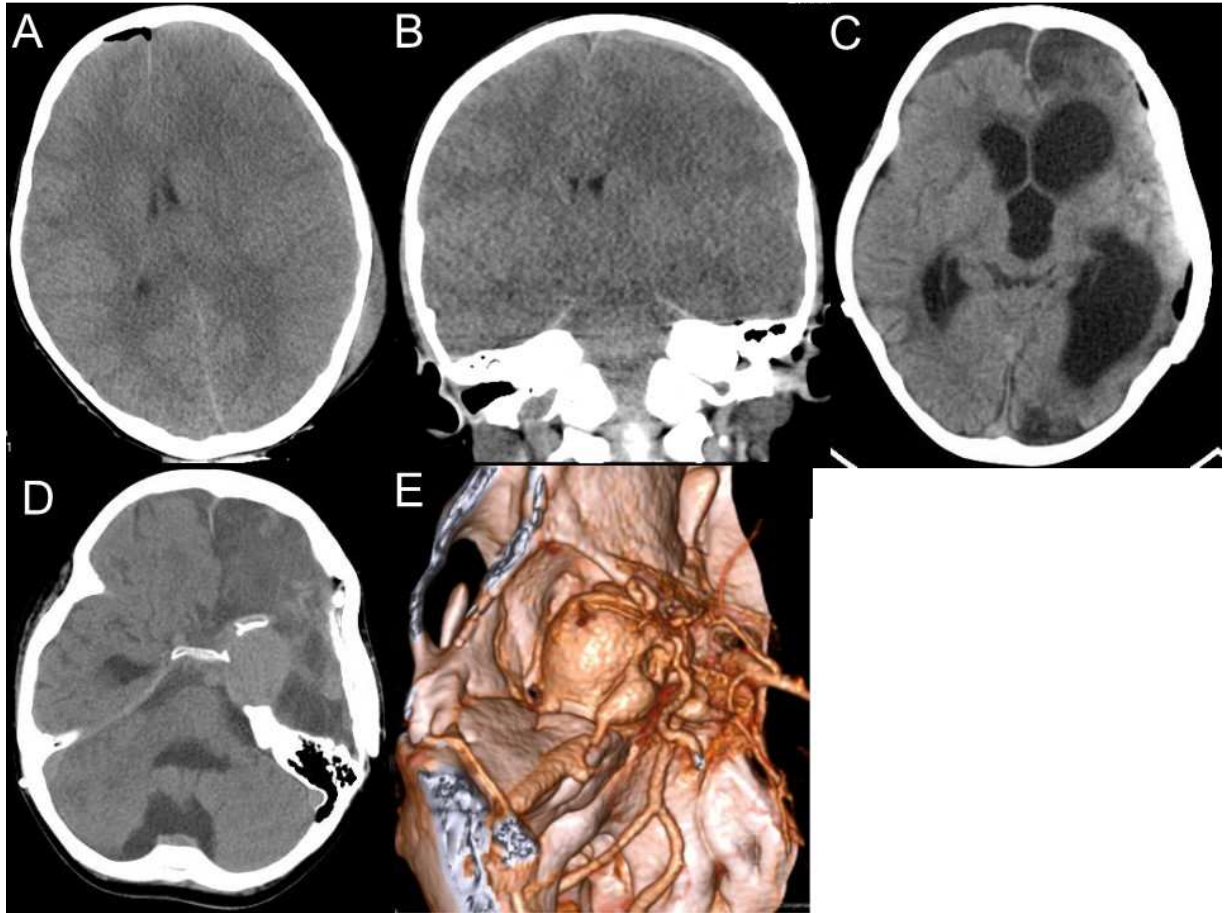
Fig 3. A 6-French F_r Destination guiding catheter (TERUMO, Tokyo, Japan) was introduced to the C5 portion of the left ICA (Fig 3-A). After the introduction of a Sceptor C 4mm×10mm balloon catheter (TERUMO, Tokyo, Japan) into the neck of the aneurysm (Fig 3-B), coil embolization of the aneurysm and parent artery occlusion are performed by double catheter technique with an Excelsior SL-10 STR (Boston Scientific, Massachusetts, USA) and SL-10 pre-shaped 45° (Boston Scientific, Massachusetts, USA) (Fig 3-C). Complete obliteration of the direct CCF shunts, rough packing for the

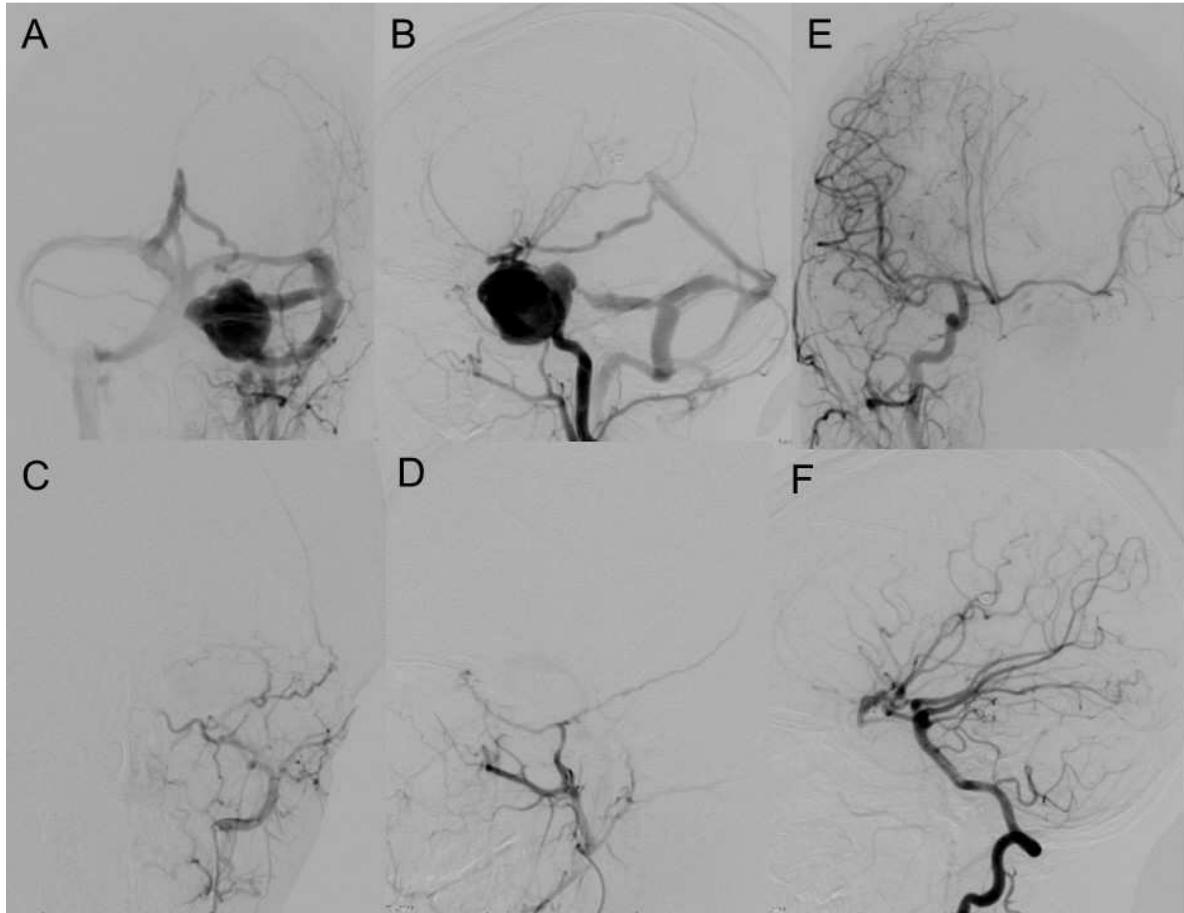
preservation of abducens nerve near Dorello's canal (black arrow, Fig 3-D), and preservation of right ophthalmic artery patency are confirmed with postoperative DSA (Fig 3-E); postoperative right CAG showing good collateral flow via A-com A to the left ICA region (Fig 3-F); postoperative brain magnetic resonance imaging showing no new lesions (Fig 3-G).

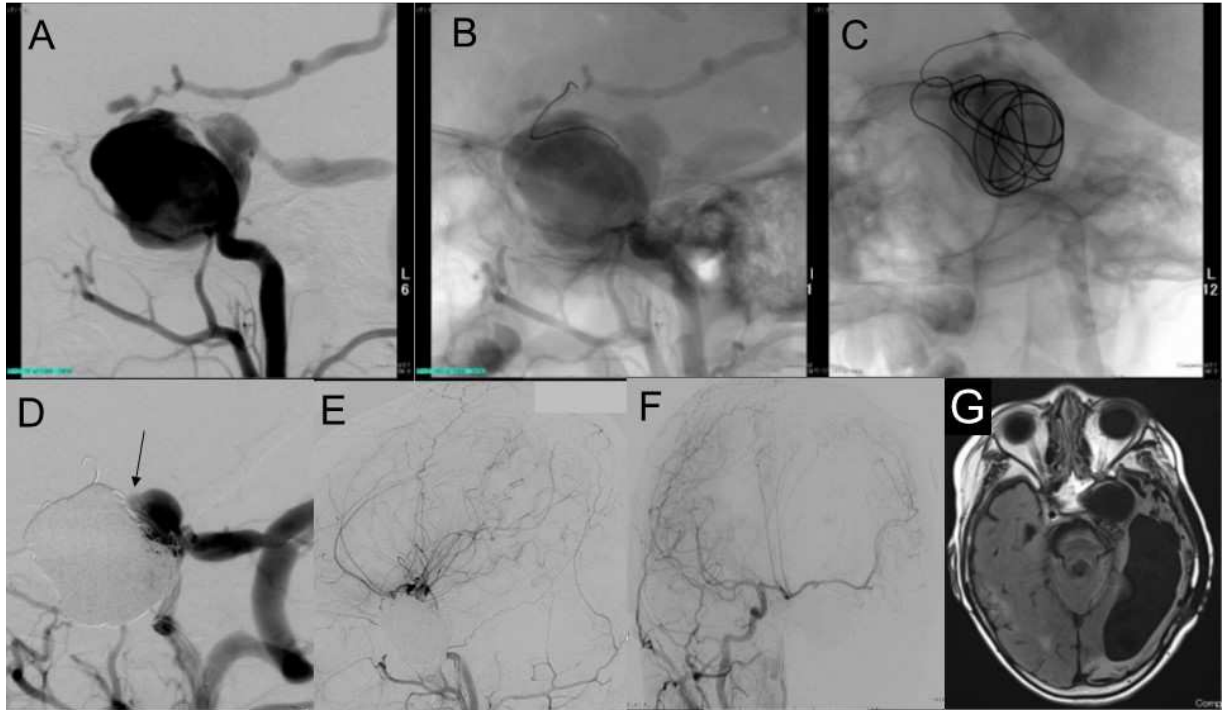
Table 1. Reported cases of pediatric post-traumatic CCF

Author	Age	Sex	Symptoms	Duration post-trauma	Management	Outcome
Yang Y et.al ¹²	6	Male	Left eyelid swelling, proptosis, orbital pain, and headache	Simultaneously	TVE with coils	Good
Paiva WS et.al ¹³	10	Male	Right proptosis, amaurosis, conjunctival hyperemia, ophthalmoplegia, absent direct pupillary light reflex, hypoesthesia on the territories of V1 and V2 branches of the trigeminal nerve	47 days	TVE with coils	Good
Pawar N et.al ¹⁴	6	Female	Right proptosis, chemosis	10 days	TVE with coils	Good
Present case	6	Male	Left abducent palsy	2 years	Aneurysm coil embolization with PAO	Good

CCF: Carotid cavernous fistula, TVE: transvenous embolization, PAO: parent artery occlusion







ACCI

Abbreviations

carotid cavernous fistula (CCF)

internal carotid artery (ICA)

intensive care unit (ICU)

parent artery occlusion (PAO)

computed tomography (CT)

three-dimensional CT angiography (3D-CTA)

superior petrosal sinus (SPS)

ICA angiogram (ICAG)

external carotid artery angiograms (ECAG)

anterior communicating artery (A-com A)

magnetic resonance image (MRI)

balloon occlusion test (BOT)

motor evoked potential (MEP)

transvenous embolization (TVE)