

Sequential PET studies in neuro-Behcet's syndrome

K. Mineura¹, T. Sasajima¹, M. Kowada¹, F. Shishido², K. Uemura², and K. Nagata³

¹Neurosurgical Service, Akita University Hospital, ²Department of Radiology and Nuclear Medicine, and ³Department of Neurology, Research Institute for Brain and Blood Vessels-Akita, Akita 010, Japan

Summary. A case of neuro-Behcet's syndrome is presented with sequential positron emission tomography (PET) studies. Regional cerebral blood flow (rCBF) and oxygen consumption (rCMRO₂) were decreased in the brain lesion; however, on follow-up studies 3 months after steroid therapy rCBF and rCMRO₂ had increased in the lesion, which demonstrated the reversibility of this disease. Such monitored improvement may accurately reflect the early stage of the disease and its response to steroid therapy.

Key words: Neuro-Behcet's syndrome – Positron emission tomography (PET) – Cerebral blood flow – Oxygen metabolism – Steroids

Introduction

Neuro-Behcet's syndrome occurs in 10%–30% of patients with Behcet's syndrome [1, 10]. In computed tomography (CT) scans, lesions involving the central nervous system (CNS) are seen as low-density areas (LDAs). Magnetic resonance imaging (MRI) has proved effective in visualizing brain-stem lesions [3, 8], but there have been no reports of positron emission tomography (PET) findings in this syndrome. We recently studied a patient with neuro-Behcet's syndrome who presented with hemiparesis. Studies of cerebral blood flow and metabolism were performed using the PET technique both while the patient's condition was worse and during remission induced by steroid therapy.

Case report

The patient was a 53-year-old housewife who had suffered, since 1976, from recurrent aphthae of the oral cavity, ulcerations of the genital area and an erythema nodosum-like rash of the legs. Four years later, she developed uveitis and was diagnosed as having Behcet's syndrome. In 1983, she underwent bilateral trabeculectomy for glaucoma and cataracts. On 6 September 1987, she noticed loss of strength of the left arm and leg and was admitted to the Department of Neurology at Research Institute for Brain and Blood Vessels. CT showed an LDA in the right thalamus. On 5 October her hemiparesis worsened and she was transferred to the Neurosurgical Service of Akita University Hospital.

Her consciousness was normal, but visual acuity was poor (left 0.4; right 0.02) and both pupils showed deformities due

to the previous ocular surgery. There was a left hemiparesis including the face, and dysarthria. Deep reflexes on the left side were hyperactive and Hoffmann's and Wartenberg's signs were positive on the left. The white blood cell count was 10,000/mm³ with 78% segmented neutrophils, 7% band forms and 9% lymphocytes. The erythrocyte sedimentation rate was 80 mm/h. Immunoglobulin A was slightly elevated (386 mg/dl, normal range 70–350). Cerebrospinal fluid examination revealed an opening pressure of 105 mm H₂O, with 83/3 cells/mm³ (89% lymphocytes and 11% polymorphonuclear leucocytes). Total protein was 15 mg/dl and glucose 105 mg/dl.

In the CT scans (Fig. 1) on admission, the LDA of the right thalamus was enlarged with an associated mass effect extending to the basal ganglia and midbrain. Enhanced lesions were observed near the posterior limb of the internal capsule. Cerebral angiograms showed signs of mass effect referable to the right thalamus, but neither tumour stain nor vessel obstruction were seen.

Based on these findings, the diagnosis of neuro-Behcet's syndrome was made. Dexamethasone (4 mg/day) was initially given, and increased to 8 mg/day on the 5th day. After a total dose of 62 mg during 10 days had been administered, CT and PET scans were carried out.

In the CT scans, the LDA has unchanged in size and extent as compared with the previous CT studies. A high-resolution Headtome III apparatus [5] was employed for the PET study using C¹⁵O₂, C¹⁵O and ¹⁵O₂ as tracers; regional cerebral blood flow (rCBF), blood volume (rCBV), oxygen extraction fraction (rOEF) and oxygen consumption (rCMRO₂) were measured using the ¹⁵O-steady state model [2]. In the LDA in the right thalamus seen in CT scans, rCBF was 37.7 ml/100 ml per minute, rCBV 2.6 ml/100 ml, rOEF 0.27 and rCMRO₂ 1.32 ml/100 ml per minute. All of these values were distinctly lower than the corresponding values in the left thalamus (rCBF 43.6 ml/100 ml per minute, rCBV 3.7 ml/100 ml, rOEF 0.42, rCMRO₂ 2.40 ml/100 ml per minute). The rCBF and rCMRO₂ were decreased in the right temporal lobe and left cerebellum, leading to notable lateral asymmetries. In comparison with the values of normal volunteers [11], the rCMRO₂ decrease exceeded the 95% confidence limit of the mean values at the midbrain, temporal lobe and contralateral centrum semiovale (Table 1, Fig. 2). These findings suggested widespread disease.

The left hemiparesis gradually improved starting on the 7th day after steroid administration. The dose was then decreased in steps and halted after a total dosage of 128 mg during 1 month had been given. CT scans obtained after a total dose of 92 mg showed contraction of the LDA in the thalamus

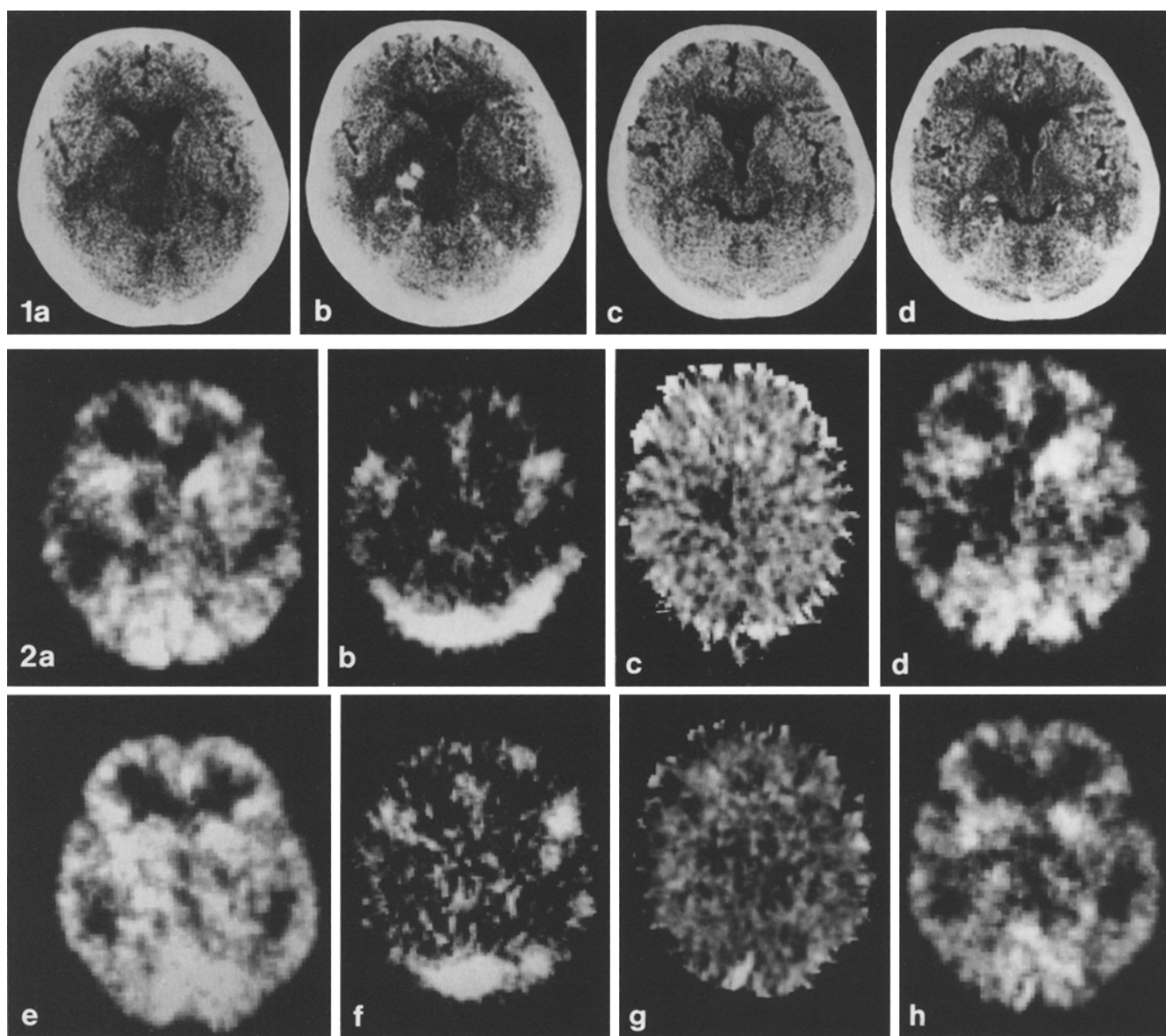


Fig. 1. CT scans on admission (**a, b**) showed a low-density area (LDA) of the right thalamus, extending to the basal ganglia and midbrain with enhancing lesions in the vicinity of the posterior limb of the internal capsule. The LDA and the enhancing lesions disappeared 3 months after completion of steroid therapy (**c, d**). (Left: Plain CT; right: enhanced CT)

Fig. 2. PET scans after a total dose of 62 mg dexamethasone (**a–d**) revealed low rCBF, rCBV, rOEF, rCMRO₂ in the LDA of the right thalamus seen in CT scans. Follow-up PET scans 3 months later (**e–h**) disclosed increases in rCBF and rCMRO₂ in the thalamic lesion. Increases were also seen in the right temporal lobe and basal ganglia, resulting in a decrease of rOEF. (Left to right: rCBF, rCBV, rOEF and rCMRO₂ images)

and alleviation of the mass effect. The degree of enhancement was now mild and was confined to the posterior internal capsule. CT scans 7 days after the completion of steroid therapy showed further reduction in the LDA and improvement in the mass effect. On 7 December she was discharged with almost complete recovery of her left-sided hemiparesis.

PET was also performed at follow-up 3 months after the completion of steroid therapy. rCBF (65.7 ml/100 ml per minute), rCBV (4.9 ml/100 ml), rOEF (0.29) and rCMRO₂ (2.90 ml/100 ml per minute) had now increased in the thalamic lesion as compared with the previous PET scans (Table 1, Fig. 2). Moreover, increases in rCBF and rCMRO₂ were now seen in the right temporal lobe and contralateral centrum semiovale, reflecting an improvement in multiple lesions together with a decrease in size of the thalamic lesion. The laterality effect at the temporal lobe and cerebellum had nearly disappeared. CT scans at this time showed disappearance of the LDA of the thalamus (Fig. 1).

Clearly, in our patient, the CNS lesions were reversible after steroid therapy. The patient currently has no residual symptoms and leads a normal life.

Discussion

Neurological symptoms in Behcet's syndrome often develop after abnormalities of other internal organs. In some in-

Table 1. Regional circulation and oxygen metabolism in a neuro-Behtet case during and after steroids treatment

Regions	CBF (ml/100 ml/min)		CBV (ml/100 ml)		OEF		CMRO ₂ (ml/100 ml/min)	
	During	After	During	After	During	After	During	After
Thalamus								
lesion	37.7 (48.9, SD 11.4)	65.7	2.6 (3.4, SD 0.8)	4.9	0.27 (0.41, SD 0.07)	0.29	1.32 ^b (3.52, SD 0.71)	2.90
lt	43.6 (50.8, SD 9.3)	61.7	3.7 (4.9, SD 1.2)	3.9	0.42 (0.39, SD 0.06)	0.28	2.40 ^b (3.54, SD 0.47)	2.65
Brain stem								
pons	33.1 (45.5, SD 9.9)	51.6	5.6 ^a (3.4, SD 0.7)	4.5	0.44 (0.38, SD 0.06)	0.26	1.93 (3.08, SD 0.70)	2.00
midbrain	38.6 (43.5, SD 7.6)	47.8	4.1 (4.0, SD 0.7)	4.7	0.36 (0.39, SD 0.07)	0.24 ^b	1.83 ^b (2.95, SD 0.54)	1.77 ^b
Cerebellum								
rt	45.4 (51.8, SD 8.9)	62.8	3.6 (6.2, SD 1.6)	8.0	0.48 (0.43, SD 0.06)	0.32	2.82 (3.97, SD 0.73)	3.10
lt	39.9 (52.2, SD 9.7)	61.3	3.5 (4.0, SD 1.3)	5.1	0.49 (0.43, SD 0.06)	0.31	2.64 (3.99, SD 0.71)	2.97
Temporal (superior temporal gyrus)								
rt	33.8 (44.6, SD 9.1)	49.7	3.5 ^b (5.3, SD 0.8)	4.1	0.46 (0.42, SD 0.06)	0.33	2.08 ^b (3.51, SD 0.57)	2.52
lt	41.1 (48.5, SD 9.7)	56.2	3.5 ^b (5.0, SD 0.7)	4.2	0.51 (0.43, SD 0.06)	0.30 ^b	2.80 (3.66, SD 0.52)	2.61
Centrum semiovale								
rt	27.1 (21.9, SD 4.8)	31.3	1.5 (2.0, SD 0.3)	2.0	0.38 (0.41, SD 0.09)	0.33	1.34 (1.53, SD 0.21)	2.52
lt	17.9 (21.9, SD 5.5)	28.2	2.4 (2.2, SD 0.6)	2.0	0.42 (0.40, SD 0.08)	0.33	0.97 ^b (1.51, SD 0.25)	1.46

^a, ^b Decreased and increased, respectively, exceeding the 95% confidence limit of the mean values of the volunteers

Figures in parentheses denote the mean values and SD of 22 normal volunteers aged 26–64 years old

rt: Right; lt: left

stances, however, when the onset is primarily in the CNS, the differential diagnosis from multiple sclerosis and disseminated myelitis can be difficult [6, 7]. The present case was diagnosed as Behcet's syndrome in the light of the history of recurrent aphthous ulcers of the oral cavity, erythema nodosum, uveitis and genital ulcerations. Neurological symptoms first appeared 11 years after onset. The diagnosis of neuro-Behtet's syndrome was confirmed by the cerebrospinal fluid findings, by CT and by the response of the brain lesions to steroid therapy.

Inaba and Shimizu [4] reported that 16 of their 22 patients with neuro-Behtet's syndrome showed abnormalities in the CT scans. Eleven had LDAs of the basal ganglia or thalamus, 11 cerebral atrophy and 4 brain-stem atrophy. Eight of the 11 cases with cerebral atrophy were chronic cases studied more than 3 years after the neurological onset. Acute cases with a relatively short period from onset showed changes in CT findings in accord with the aggravation and remission of neurological symptoms. Transient enhancement and mass effect were seen in the period of aggravation.

The present patient experienced the rapid onset of CNS symptoms and CT findings typical of this syndrome. The CT appearances of enhancement and mass effect during aggravation resembled those of brain tumours, brain abscess or cerebrovascular damage. The differential diagnosis was clarified by the clinical course and by serial improvements in the CT scans over time.

With regard to the mechanism of contrast enhancement in CT scans, an exudative inflammation in the small vessels causes secondary deficits in the blood-brain barrier, resulting in extravasation of contrast medium [9]. In our patient, clinical symptoms and CT findings improved following steroid therapy, suggesting that the steroids suppressed the vascular changes and restored the functional integrity of the blood-brain barrier.

We have found no previous reports of cerebral blood flow and metabolism based on PET scans in neuro-Behtet's syndrome. In the present patient, rCBF and rCMRO₂ were decreased in the brain lesion; however, their values exceeded the thresholds at which tissue damage is irreversible in cerebrovascular diseases. Because the deficits in both rCBF and rCMRO₂ were reversible, the disease may have still been in an early stage. On follow-up studies 3 months later rCBF and rCMRO₂ had increased at the lesion, again demonstrating the reversibility of this disease. Such improvements may accurately reflect the early stage of the disease and its response to steroid therapy.

In autopsy studies, the CNS lesions of neuro-Behtet's syndrome occur most frequently in the brain-stem, basal ganglia and thalamus; most cortical lesions involve the temporal lobe, and primary lesions are rarest in the cerebellum [4]. In our patient's PET scans, metabolism was decreased in the brain stem, temporal lobe and contralateral centrum semiovale, in

addition to the primary thalamic lesion. Our diagnosis of neuro-Behcet's syndrome was favoured by the evidence of diffuse, multiple lesions, in close agreement with the sites of predilection for CNS lesions in autopsy cases. The decreased blood flow and metabolism in the right temporal lobe and left cerebellum were more suggestive of a transneuronal remote effect of the right thalamic and midbrain lesions, given the usual pathological findings of neuro-Behcet's syndrome.

Neuro-Behcet's syndrome typically progresses through multiple lesions into an irreversible pathological condition with recurrent exacerbations and remissions. PET studies provide a useful way of understanding the haemocirculatory and metabolic aspects of this disease and to monitor its clinical status and therapeutic response.

References

1. Cahjek T, Fainaru M (1975) Behcet's disease. Report of 41 cases and a review of the literature. *Medicine (Baltimore)* 54:179-196
2. Frackowiak RSJ, Lenzi GL, Jones T, Heather JD (1980) Quantitative measurement of regional cerebral blood flow and oxygen metabolism in man using ^{15}O and positron emission tomography: theory, procedure, and normal values. *J Comput Assist Tomogr* 4:727-736
3. Fukuyama H, Kameyama M, Nabatame H, Takemura M, Nishimura K, Fujisawa I, Torizuka K (1987) Magnetic resonance images of neuro-Behcet syndrome show precise brain stem lesions. Report of a case. *Acta Neurol Scand* 75:70-73
4. Inaba G, Shimizu T (1980) Computed tomography (CT) and EEG in neuro-Behcet's syndrome (in Japanese). *Clin EEG* 22:243-253
5. Kanno I, Miura S, Yamamoto S, Iida H, Murakami M, Takahashi K, Uemura K (1985) Design and evaluation of a positron emission tomograph: Headtome III. *J Comput Assist Tomogr* 9:931-939
6. Kozin F, Haughton V, Bernhard GC (1977) Neuro-Behcet disease. Two cases and neuroradiologic findings. *Neurology* 27:1148-1152
7. Motomura S, Tabira T, Kuroiwa Y (1980) A clinical comparative study of multiple sclerosis and neuro-Behcet's syndrome. *J Neurol Neurosurg Psychiatry* 43:210-213
8. Willeit J, Schmutzhard E, Aichner F, Mayr U, Weber F, Gerstenbrand F (1986) CT and MR imaging in neuro-Behcet disease. *J Comput Assist Tomogr* 10:313-315
9. Williams AL, Haughton VM, Saxena VK, Albers WA (1979) Computed tomography in Behcet disease. *Radiology* 131:403-404
10. Wolf SM, Schotland DL, Phillips LL (1965) Involvement of nervous system in Behcet's syndrome. *Arch Neurol* 12:315-325
11. Yamaguchi T, Kanno I, Uemura K, Shishido F, Inugami A, Ogawa T, Murakami M, Suzuki K (1986) Reduction in regional cerebral metabolic rate of oxygen during human aging. *Stroke* 17:1220-1228

Received February 8, 1988 / Received in revised form April 7, 1989 / Accepted April 26, 1989