

Acute hemichorea due to infarction in the corona radiata

F. Barinagarrementeria, F. Vega, and O.H. DelBrutto

Stroke Clinic, Division of Neurology, Instituto Nacional de Neurologia y Neurocirugia, Insurgentes Sur 3877, 14410 Mexico 22, D.F.

Summary. A 66-year-old hypertensive man presented with acute hemichorea. Magnetic resonance imaging disclosed an infarct, confined to the contralateral corona radiata, that interrupted excitatory corticostriate fibres. The movement disorder may have been caused by subcortical lesion without direct involvement of the basal ganglia.

Key words: Hemichorea – Subcortical infarction – Movement disorder – Lacunar syndrome

Introduction

Acute hemichorea is a relatively uncommon disorder of movement that usually follows an ischaemic [3, 4, 7] or haemorrhagic [8] lesion in the contralateral caudate nucleus or putamen [2], thalamus [4], or subthalamic nucleus [8]. Lesions outside these structures have also been described in patients with hemichorea [1, 4, 5]; however, the cause-and-effect relationship of this association is not fully understood. We report a patient with acute hemichorea caused by infarction in the contralateral corona radiata.

Case report

A 66-year-old, right-handed, hypertensive man was examined 5 days after the acute onset of involuntary movements of his

Offprint requests to: F. Barinagarrementeria

left limbs. On admission, his blood pressure was 160/100 mmHg and the findings of a general physical examination were normal. Neurological examination revealed constant, involuntary, irregular, purposeless, asymmetrical and non-rhythmic movements of the left arm and leg. The patient was alert and oriented, and there was no motor or sensory deficit. Computed tomography (CT) showed an ill-defined small area of low attenuation in the right corona radiata. Magnetic resonance imaging (MRI) revealed periventricular hyperintensity (T2-weighted) and an infarct in the right corona radiata that did not extend to the caudate nucleus or putamen (Fig. 1). The patient was treated with haloperidol (10 mg/day in three divided doses) with marked improvement. The dose of haloperidol was gradually tapered over the following weeks and the findings of a neurological examination 6 months after the onset of symptoms were normal.

Discussion

The syndrome of hemichorea is usually considered to be caused by a lacunar infarction in the contralateral basal ganglia or related structures [6]. In such cases, the hyperkinesia appears when an intact globus pallidus is isolated from inhibitory influences exerted by the striatum or subthalamic nucleus. This isolation is secondary to a lesion that destroys those nuclei or that interrupts their efferent fibres to the pallidum [3, 5].

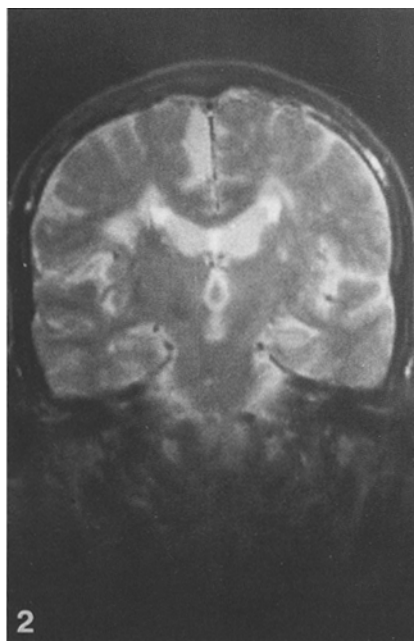
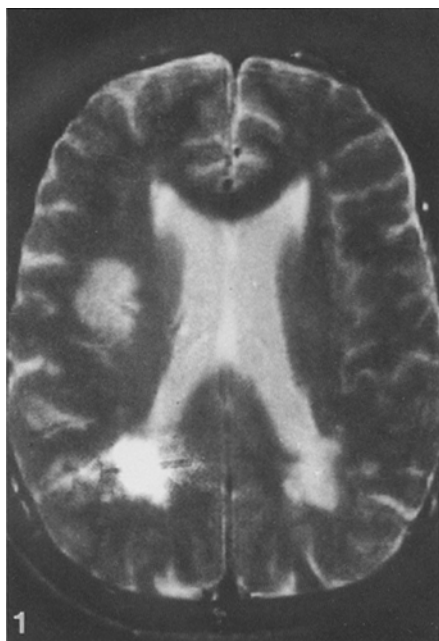


Fig. 1. T2-weighted (TR 2000/TE 50) magnetic resonance imaging showing an infarct in the right corona radiata

Fig. 2. Coronal T2-weighted (TR 2000/TE 50) magnetic resonance imaging showing the extension of the infarct in the patients

Our patient had hemichorea due to an infarct in the contralateral corona radiata and that did not extend into the basal ganglia (Fig. 1). It is possible that the interruption of corticostriate fibres accounted for the movement disorder. Under normal conditions, corticostriate fibres carry excitatory stimuli to neurons in the caudate nucleus and putamen [9]; such stimuli facilitate the activation of striatal neurons which, in turn, exert inhibitory influences on the pallidum. An interruption in the corticostriate pathway diminishes the rate of firing of striatal neurons, liberating the pallidum from striatal inhibition and causing the abnormal movements of hemichorea. As our patient is still alive, we have no pathological correlations. However, MRI showed an infarct in the contralateral corona radiata without evidence of basal ganglia lesion.

In reviewing the literature, we have found several cases of acute hemichorea due to lesions outside the basal ganglia. However, in no instance was the interruption of corticostriate fibers considered to be the cause of the movement disorder [4, 5]. Saris [7] described a patient with acute hemichorea and an infarct in the contralateral corona radiata and body of the caudate nucleus shown by CT; while the author stated that the lesion in the caudate nucleus was the cause of the hemichorea, we think that a mechanism similar to that suggested here could be another explanation for some, at least, of the clinical manifestations.

We therefore postulate that any lesion, superficial or deep, that interrupts the cortico-striato-pallidal-thalamo-cortical feed-

back loop may be a potential cause of hemichorea, providing the globus pallidus and its efferent fibres remain intact.

References

1. Gioino GG, Dierssen G, Cooper IS (1966) The effect of subcortical lesions on production and alleviation of hemiballistic or hemichoreic movements. *J Neurol Sci* 3: 10-36
2. Jones HR, Baker RA, Kott HS (1985) Hypertensive putaminal hemorrhage presenting with hemichorea. *Stroke* 16: 130-131
3. Kase CS, Mulsby GO, DeJuan E, Mohr JP (1981) Hemichorea-hemiballismus and lacunar infarction in the basal ganglia. *Neurology* 31: 452-455
4. Martin JP (1957) Hemichorea (Hemiballismus) without lesions in the corpus luyisii. *Brain* 80: 1-10
5. Martin JP (1968) Choreatic syndromes. In: Vinken PJ, Bruyn GW (eds) *Handbook of clinical neurology*, vol 6. North-Holland, Amsterdam, pp 435-439
6. Orgogozo JM, Bogousslavsky J (1989) Lacunar syndromes. In: Vinken PJ, Bruyn GW, Klawans HL (eds) *Handbook of clinical neurology*, revised series. North-Holland, Amsterdam (in press)
7. Saris S (1983) Chorea caused by caudate infarction. *Arch Neurol* 40: 590-591
8. Thurel MMR, Grenier J (1947) Hémichoréé avec hémiballisme: hémorragie limitée au corps de luyis du coté opposé. *Rev Neurol (Paris)* 79: 502
9. Young AB, Penney JB (1984) Neurochemical anatomy of movement disorders. *Neurol Clin* 2: 417-433

Received February 2, 1989 / Received in revised form April 27, 1989 / Accepted May 3, 1989