



Contents lists available at ScienceDirect

American Journal of Emergency Medicine

journal homepage: www.elsevier.com/locate/ajem

Akinetic mutism revealing an ischemic stroke

Saad Zidouh ^{*}, Said Jidane, Ahmed Belkouch, Hicham Bakkali, Lahcen Belyamani

Emergency Department Military Hospital Mohammed V, Faculty of Medicine and Pharmacy Rabat and Mohammed V University Rabat 6203, Morocco

ARTICLE INFO

Article history:

Received 13 October 2016

Received in revised form 31 October 2016

Accepted 1 November 2016

Available online xxxxx

ABSTRACT

We describe a 44-year-old man who developed akinetic mutism following a cerebrovascular accident involving his left middle cerebral artery. We discuss this rare condition and its unusual clinical picture.

© 2016 Elsevier Inc. All rights reserved.

1. Introduction

Akinetic mutism is a clinical syndrome with both neurological and psychiatric symptoms. Medical imaging has an important role: it confirms a suspected diagnosis. We report a case of ischemic stroke with a psychiatric presentation.

2. Observation

A 44 years old single man, right-handed, with no medical history was brought by his colleague to the emergency department. He found him at home, silent and motionless. As the patient is living alone, the time to onset of symptoms cannot be specified. Physical examination found a conscious patient, apathetic, akinetic, in aphasia with right hemiparesis listed at 2/5 at lower limbs and 1/5 at upper limbs. The Babinski sign was positive on the right foot. The patient did not respond to visual or auditory or verbal commands. Cardiovascular examination revealed an irregular rhythm associated to a B1 boom at the mitral valve and a diastolic murmur. Blood pressure was at 132/80 mm Hg.

A cerebral CT scan objectified an ischemic stroke in the territory of the left middle cerebral artery (MCA) with a mass effect on the ipsilateral ventricle, without any signs of commitment (Fig. 1A & B). The electrocardiogram (ECG) found a heart rate at 90 c/min with atrial fibrillation and a complete right bundle branch block. A chest X-ray has noted a bilateral hilar overload without cardiomegaly. Echocardiography objectified a tight mitral stenosis with a surface of about 1 cm². The ejection fraction was estimated at 45%, and pulmonary hypertension to 37 mm Hg.

The patient was hospitalized in the cardiac intensive care unit where he received Salicylates, Enoxaparin and Simvastatin. The evolution was marked by the occurrence of hemorrhagic infarction found at the

control CT scan realized after 72 h. Total resolution of the hemorrhagic infarction was obtained 10 days after.

The clinical outcome was favorable with partial recovery of speech and complete recovery of motor deficit at 30 days. The patient was discharged under medical and psychological treatment and was scheduled for mitral valve replacement surgery.

3. Discussion

Akinetic mutism refers to a syndrome characterized by a significant reduction of about all motor functions including facial expressions, gestures and verbal flow. There is a considerable variation in the clinical presentation of this type of patient. This variation corresponds more to a cerebral localization of lesions than the causal disease itself [1]. Akinetic mutism can be diagnosed wrongly as depression, delirium tremens or Looked-in-syndrome [2]. In our case, as if our patient is living alone, is silent and have a lack of interest, those symptoms could pass for depression.

Although depression is a common problem of patients suffering from stroke, akinetic mutism as a state of avolition in which the patient does not desire to think, to speak or to move [3], it can be presented as a blunting of expressions, apathy and speech disorder. So it is important to distinguish the two diagnoses because the treatment is radically different [2].

This perfectly describes the clinical picture encountered as well as in our case and in literature. In terms of stroke, responsible of mutism, unilateral lesions are rare. They may touch as well as anterior cerebral artery, thalamic or mesencephalic territory and even the internal capsule [4-5,6]. However in our case, ischemic stroke was unilateral.

Pharmacological treatment may include dopaminergic agents such as Bromocriptine, Levodopa or Pergolide. These agents are the cause of spectacular clinical improvements [7]. Non-pharmacological treatment includes an intense rehabilitation, with modification of the patient's environment to stimulate and increase his interest. Cognitive and behavioral therapies are also suggested [8].

^{*} Corresponding author.

E-mail address: sazi26@hotmail.fr (S. Zidouh).

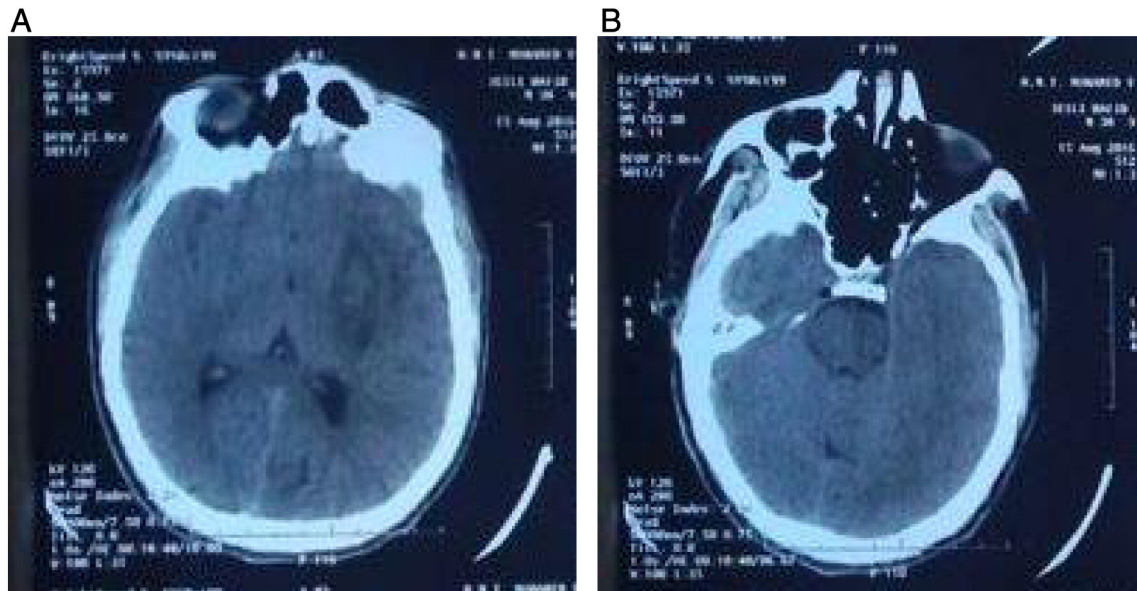


Fig. 1. Ischemic stroke at the left middle cerebral artery (MCA) “A” with a mass effect on the ipsilateral ventricle “B”.

Our patient benefited from rehabilitation measures, and anticoagulant therapy for ischemic stroke. This enabled a partial recovery of his deficit.

4. Conclusion

Akinetic mutism discovered in a patient without psychiatric history poses a problem of border between the psychiatric and neurological origin. Given the rarity of this disease, and a few randomized studies available on the subject, imagery remains the angular point for diagnostic orientation in these situations, in which the therapeutic management must pass by psychological rehabilitation.

References

[1] Cairns H, Oldfield HC, Pennybaker JB, Whineridge D. Akinetic mutism with an epidermoid cyst of the third ventricle. *Brain* 1941;34:273–90.

- [2] Nagaratnam N, Nagaratnam K, Ng K, Dui P. Akinetic mutism following stroke. *J Clin Neurosci* 2004;11(1):25–30.
- [3] Lim YC, Ding CSL, Kong K. Akinetic mutism after right internal watershed infarction. *Singap Med J* 2007;48(5):466.
- [4] Meador KJ, Watson RT, Bowers D, Heilman KM. Hypometria with hemispatial and limb motor neglect. *Brain* 1986;109:293–305.
- [5] Damasio AR, Vandstensen GW. Structure and function of the supplementary motor area. *Neurology* 1980;30:300–59.
- [6] Benoke R, Rothwell JC, Duk JRP, et al. Performance of simultaneous motor acts in normal subjects and in patients with Parkinson's disease. *Brain* 1986;46:1024–7.
- [7] Marin RS, Wilkosz PA. Disorders of diminished motivation. *J Head Trauma Rehabil* 2005;20:377–88.
- [8] Psarros T, Zouros A, Coimbra C. Bromocriptine-responsive akinetic mutism following endoscopy for ventricular neurocysticercosis. Case report and review of the literature. *J Neurosurg* 2003;99:397–400.