

Thalamic hemorrhage in a 4-year-old child induced by nephro-vascular hypertension

E. Bianchi¹, S. Savasta¹, F. Torcetta¹, M. Solmi¹, G. Beluffi² and T. M. Gajno³

¹ Pediatrics Clinic of the University of Pavia,

² Department of Radiodiagnosis, Section of Pediatric Radiology, IRCCS Policlinico "S. Matteo", Pavia, and

³ Department of Neuroradiology, Ospedale "Regina Margherita", Turin, Italy

Abstract. A child affected by cardiomyopathy from the age of 12 months suddenly manifested right hemiparesis and dysarthria at the age of 48/12 years. Emergency brain CT showed a hemorrhage in progress in the left thalamic area. A severe form of hypertension was concomitant and resisted all pharmacological treatment. Retrograde transfemoral aortography pointed out an atrophy of the right renal artery. This finding, together with the high renin and aldosterone values, indicated a nephrogenic hypertension causing both the cardiomyopathy found at 12 months of age and the endocranial hemorrhage. Right nephrectomy led to normalization of blood pressure.

Parenchymatous brain hemorrhage attributed to hypertension is very rare in infancy [1–2].

Intracerebral bleeding occurs with sufficient frequency between the thirties and the seventies: significant risk factors are a history of hypertension, chronic alcoholism, hepatic disease, EKG abnormalities and high hematocrit values [2–6].

Hypertensive hemorrhage in adults distributes as follows: putamen 53%, thalamus 13%, pons 5%, cerebellum 10%, other sites 10%. No data are available for children [4].

This case report describes a thalamic hemorrhage which occurred in a 4-year-old child due to hypertension. Clinical aspects and radiologic, biochemical and therapeutic features are discussed.

Case report and clinical course

C.L., a male patient, was hospitalized in another Hospital at 12 months of age due to a cyanotic crisis. Endocardial fibroelastosis was diagnosed on that occasion (Fig. 1). A later surgery visit found him to have an arterial pressure of 140/100 mm Hg which was not investigated further. The child came to our observation in December 1984, at the age of 48/12 years, due to the sudden onset of a right hemiparesis with difficulty in speech.

When he was hospitalized his general conditions were compromised: the child was pale, his heart rate was 80 beats/minute, with a 3/6 systolic murmur irradiating towards the carotid and evident pulsation in the jugular region. The child presented right hemiparesis, his rotular and cubital tendon reflexes were weak on the right side and polykinetic on the left; he was unable to protrude his tongue, his speech was impaired and he suffered from paresis of the VII cranial nerve on the right; arterial pressure was 220/90 mm Hg. Routine hematochemical tests yielded normal results, and so did creatinin clearance and VMA. ECG pointed out left ventricular hypertrophy. The fundus oculi showed pale and slightly fading papilla in the right eye and refracting spots at the rear pole. An EEG showed generalized 1.5–2.5 c/s waves of considerable amplitude, interrupted by sporadic saw-tooth waves. Brain CT showed a left parieto-thalamic intraparenchymal hematoma with a slight perifocal edema and slight mass effect on the ventricles (Fig. 3). A subsequent check of the fundus oculi confirmed the papillary edema, especially on the left, a retinopathy with a star-shaped macular mark and, in the right eye, a round atrophic area in the macular region. A carotid angiography was performed, with negative results as to congenital vascular malformations.

In view of the regular persistence of high arterial pressure values, renin and aldosterone were administered during hospitalization, respectively at dosages of 19.1 ng/ml/h (n.v. 0.2–2) and 55.8 pg/ml (n.v. 5–17). Renal echography showed a normal-size left kidney and a right kidney of approximately 6 cm. Retrograde transfemoral aortography (Fig. 4) allowed us to achieve a precise diagnosis, as it pointed out a congenital atrophy of the right renal

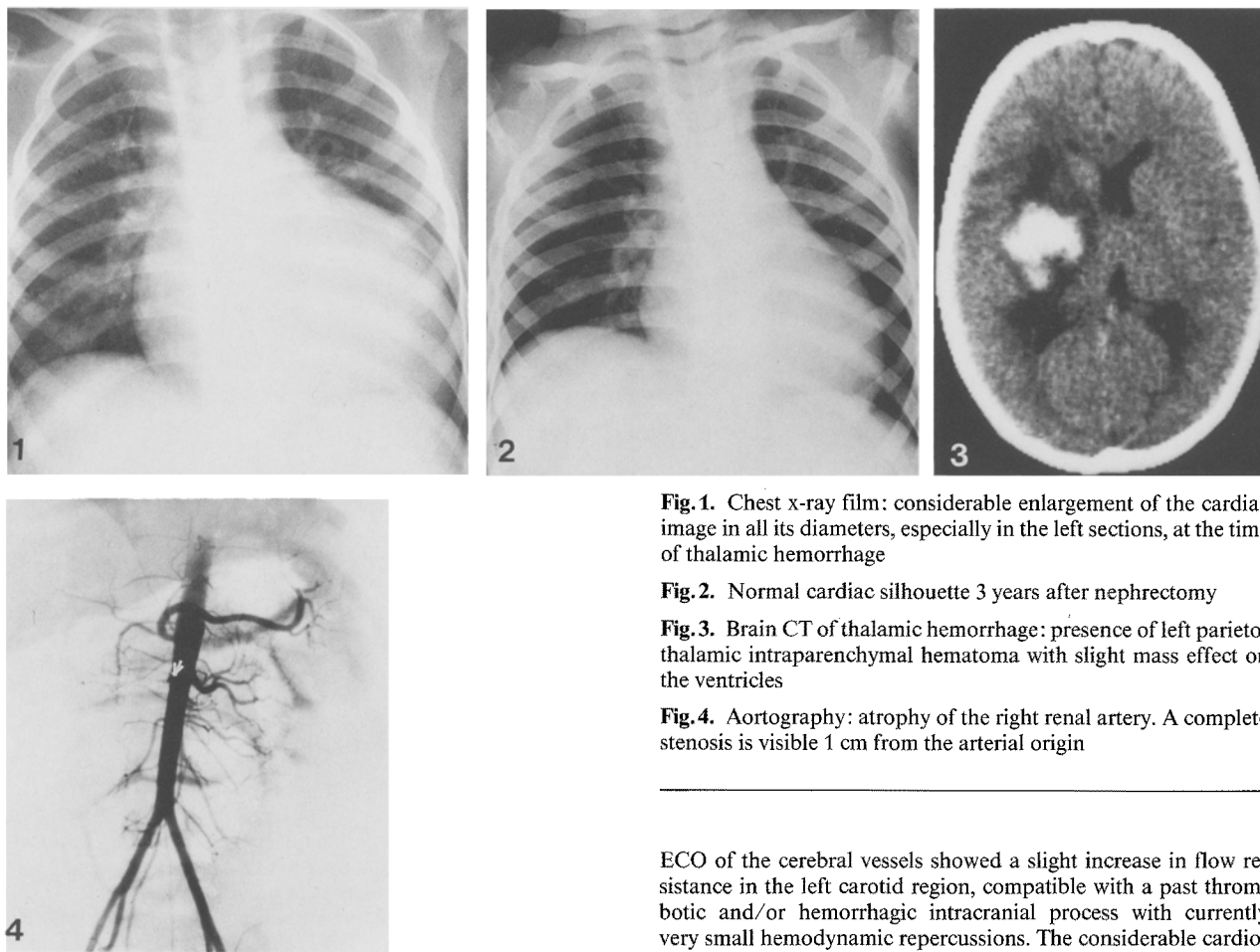


Fig. 1. Chest x-ray film: considerable enlargement of the cardiac image in all its diameters, especially in the left sections, at the time of thalamic hemorrhage

Fig. 2. Normal cardiac silhouette 3 years after nephrectomy

Fig. 3. Brain CT of thalamic hemorrhage: presence of left parieto-thalamic intraparenchymal hematoma with slight mass effect on the ventricles

Fig. 4. Aortography: atrophy of the right renal artery. A complete stenosis is visible 1 cm from the arterial origin

artery with a normal left renal artery. A completely occluded stenosis was also observed on the right, approximately 1 cm from the origin, with a partial recanalization through a collateral circulation consisting exclusively of the lumbar arteries; the right intraparenchymal branches were thread-like, with a small kidney of approximately 5.5 cm on the right, while the left kidney appeared to have a normal size.

During the first week of hospitalization, arterial pressure values oscillated between 270 and 190 mm Hg. Anti-hypertension therapy was thus started with Diazoxide, Clonidine and Furosemide with no satisfactory results. A therapeutic attempt to lower arterial pressure with sodium nitroprussate was equally unsuccessful; artery pressure in fact remained at values comprised between 220 and 140 mm Hg. After 10 days neurological conditions were unchanged, though the child was more lively, talked and ate. A control brain CT performed on 1.3. 1985 showed a reduction of the compression effect on the ventricular system.

Due to the lack of response to anti-hypertension therapy and of the findings of the retrograde transfemoral angiography, surgical intervention was decided upon. In April 1985 the child underwent right monolateral nephrectomy, and this resolved the hypertension. Approximately one month after surgery, the aldosterone values normalized (9.5 pg/ml) and renin activity decreased considerably (6.2 ng/ml/h); a progressive improvement of the child's general conditions was thus observed together with a partial resolution of the neurological deficit. A follow-up performed 4 years after surgery showed pressure values (105/75 mm Hg), renin, aldosterone and kidney function to be normal. A Doppler

ECO of the cerebral vessels showed a slight increase in flow resistance in the left carotid region, compatible with a past thrombotic and/or hemorrhagic intracranial process with currently very small hemodynamic repercussions. The considerable cardiomegaly which had previously been diagnosed as endocardial fibroelastosis reduced until complete normalization of the cardiac profile was achieved (Fig. 2) and the electrocardiographic signs of left ventricular hypertrophy disappeared.

Discussion

Nephro-vascular hypertension secondary to ischemia of the kidney caused by alterations of the renal artery or of its main branches is one of the main causes of secondary hypertension. This condition can have extrinsic and intrinsic causes; the latter are more frequent in adults and generally consist of stenoses of the renal artery on an atherosclerotic or dysplastic basis. The consequent renal ischemia leads to an increased increment of renin on the part of the juxtaglomerular apparatus, activating the renin-angiotensin system. The reduction of the renal filtrate and of the perfusion pressure furthermore induces a reduction in glomerular filtration, increasing tubular sodium reabsorption and leading to a further increase in the pressure values. In this case, the increased renin and aldosterone values led to investigations of the renal region.

Retrograde transfemoral aortography, a first-choice technique and the first necessary step in order to point out the origin and course of the renal arteries and of any collateral circulations, confirmed the diagnostic suspicion. The test in fact showed congenital atrophy of the right renal artery, with a completely occluded stenosis approximately 1 cm from the origin and a partial recanalization through a collateral circulation exclusively consisting of the lumbar arteries; almost complete functional silence was present at parenchymal level. Overall conditions indicated a congenital form of dysplasia of the right renal artery, on which an occlusive phenomenon had implanted, leading to complete obstruction with an insufficient collateral circulation. This may explain the huge hypertensive cardiomegaly which had led to the diagnosis of endocardial fibroelastosis at the age of 12 months. The neurological deficit can be ascribed to the rupture of a terminal branch of the frontal perforating artery during a violent hypertensive crisis affecting the thalamic region which, as the literature shows, is one of the sites least frequently involved in hypertension-based hemorrhages.

The nephrovascular origin of the hypertension explains the inefficacy of medical therapy. Surgical therapy (right nephrectomy) instead led to a normal-

ization of the pressure, renin and aldosterone values and to a normalization of the cardiac image.

References

1. Drury I, Whisnant JP, Gareway WP (1984) Primary intracerebral hemorrhage. Impact of CT on incidence. *Neurology* 34: 653
2. Reis DJ (1988) The brain and hypertension. *Arch Neurol* 45: 180
3. Brott T, Thalinger K, Hertzberg V (1986) Hypertension as a risk factor for spontaneous intracerebral hemorrhage. *Stroke* 17: 1078
4. Ojeman RG, Mohr JP (1986) Hypertensive brain haemorrhage. *Clin Neurosurg* 23: 220
5. Rauscroff J, Derby B, Kirchoff I (1971) Spontaneous intracerebral haemorrhage. *Clin Neurosurg* 18: 247
6. Calandre C, Arnal C, Fernandez Ortega J, Bermejo F, Felgeroso B, Del Ser T, Vallejo A (1986) Risk factors for spontaneous cerebral hematomas. Case-control study. *Stroke* 17: 1126

Received: 20 December 1988; accepted: 29 December 1988

Prof. E. Bianchi
Pediatrics Clinic of the University of Pavia
IRCCS Policlinico "S. Matteo"
I-27100 Pavia PV
Italy

Literature in pediatric radiology (continued from p.512)

American Journal of Roentgenology (Baltimore)

- Voiding cystourethrography as a predictor of reflux nephropathy in children with urinary-tract infection: Hellström, M. et al. (Dept. of Rad., Sahlgren's Hosp., S-41345 Gothenburg, Sweden) **152**, 801 (1989)
- MR imaging of coronary artery aneurysms in a child with Kawasaki disease. Bisset III, G. S. et al. (Dept. of Rad., Children's Hosp. Med. Center, Elland and Bethesda Aves., Cincinnati, OH 45229-2899, USA) **152**, 805 (1989)
- MR imaging of the criss-cross heart. Link, K. M. et al. (Dept. of Rad., The Bowman Gray School of Med., Wake Forest Univ., 300 S. Hawthorne Rd., Winston-Salem, NC 27103, USA) **152**, 809 (1989)
- MR imaging in the tethered spinal cord syndrome. Raghavan, N. et al. (Dept. of Rad., Section of Neurorad., L-371, Univ., 505 Parnassus Ave., San Francisco, CA 94143, USA) **152**, 843 (1989)
- MR imaging determination of the location of the normal conus medullaris throughout childhood. Wilson, D. A., Prince, J. R. (Magnetic Resonance Center, Med. Center, 940 NE 13th St., P.O. Box 26307, Oklahoma City, OK 73126, USA) **152**, 1029 (1989)
- Imaging of infants and children with AIDS. Haney, P. J. et al. (Dept. of Diagn. Rad., Univ. Med. System/Hosp., 22 S. Greene St., Baltimore, MD 21201, USA) **152**, 1033 (1989)
- Blunt renal and ureteral trauma in childhood: CT patterns of fluid collections. Siegel, M. J., Balfe, D. M. (The Edward Mallinckrodt Inst. of Rad., Washington Univ. School of Med., 510 S. Kingshighway Blvd., St. Louis, MO 63110, USA) **152**, 1043 (1989)
- Closed spinal dysraphism: analysis of clinical, radiological, and surgical findings in 104 consecutive patients. Scatliff, J. H. et al. (Dept. of Rad., Univ. School of Med., Chapel Hill, NC 27599, USA) **152**, 1049 (1989)
- Absolute intracranial blood-flow velocities evaluated by duplex Doppler sonography in asymptomatic preterm and term neonates. Horgan, J. G., et al. (Dept. of Rad., Univ. Health Sciences Center, 4200 E. Ninth Ave., Denver, CO 80262, USA) **152**, 1059 (1989)
- Color Doppler imaging of intracranial vessels in the neonate. Wong, W. S.

- et al. (Dept. of Rad., Huntington Memorial Hosp., 100 Congress St., Pasadena, CA 91105, USA) **152**, 1065 (1989)
- Hypermagnesemia: a cause of abnormal metaphyses in the neonate. Cumming, W. A., Thomas, V. J. (Dept. of Rad. and Ped., Shands Hosp., Univ., Gainesville, FL 32605, USA) **152**, 1071 (1989)
- MR imaging of the abdomen in children. Boechat, M. I., Kangaroo, H. (Kangaroo, H., Dept. of Rad. Sciences, Univ., School of Med., Los Angeles, CA 90024-17221, USA) **152**, 1245 (1989)
- Hypercalciuric Bartter syndrome: resolution of nephrocalcinosis with indomethacin. Matsumoto, J. et al. (Dept. of Rad., Children's Hosp. Med. Center and Univ. College of Med., Elland & Bethesda Aves., Cincinnati, OH 45229-2899, USA) **152**, 1251 (1989)
- Juvenile pilocytic astrocytomas: CT and MR characteristics. Lee, Y.-Y. et al. (Div. of Diagn. Imaging, Dept. of Diagn. Rad., The Univ., M. D. Anderson Cancer Center, 1515 Holcombe Blvd., Houston, TX 77030, USA) **152**, 1263 (1989)
- Pediatric radiology case of the day: case 1: duodenal duplication. Case 2: congenital hepatic fibrosis with saccular dilatation of the intrahepatic bile ducts and infantile polycystic kidneys. Case 3: oncogenic rickets (Feuerstein and Mims syndrome with resistant rickets). Case 4: diffuse infiltrating lipomatosis. McAlister, W. H., Siegel, M. J. (Siegel, M. J., Mallinckrodt Inst. of Rad., Washington Univ. School of Med., 510 S. Kingshighway Blvd., St. Louis, MO 63110, USA) **152**, 1328 (1989)

Archives of Surgery (Chicago)

- Diagnostic pneumoperitoneum in the pediatric patient with a unilateral inguinal hernia. Timberlake, G. A. et al. (Clinical Invest. Dept., Naval Hosp., San Diego, CA 92134-5000, USA) **124**, 721 (1989)

Canadian Association of Radiologists (Montreal)

- Calcification of axillary lymph nodes following BCG vaccination. Burdeny, D. A. et al. (Reed, M. H., Dept. of Rad., Children's Hosp., 840 Sherbrook St., Winnipeg, Manitoba, Canada R3A 1M4) **40**, 92 (1989)

(continued on p.519)