

Case Report

Cardioembolic Stroke in Primary Oxalosis With Cardiac Involvement

Giuseppe Di Pasquale, MD, Mariangela Ribani, MD, Alvaro Andreoli, MD,
Gian Angelo Zampa, MD, and Giuseppe Pinelli, MD

Primary oxalosis is a rare disorder of oxalate metabolism, characterized by nephrocalcinosis, nephrolithiasis, and extrarenal deposition of calcium oxalate in several tissues, including the heart. We report the case of a 34-year-old man with sudden right hemiparesis and aphasia from the occlusion of the left middle cerebral artery. Clinical features and the results of laboratory investigations led to the diagnosis of primary oxalosis. Two-dimensional echocardiography disclosed the presence of massive intracardiac calcifications compatible with deposition of calcium oxalate. The absence of other causes of stroke strengthened a cause-and-effect relation between cardiac oxalosis and cerebral infarction. Consequently, cardiac oxalosis should be considered among possible occult cardiac sources of cerebral embolism. (*Stroke* 1989;20:1403–1406)

Primary oxalosis is a rare hereditary error of metabolism due to increased endogenous production of oxalate. The disease is characterized by increased urinary oxalate excretion, recurrent nephrocalcinosis, and nephrolithiasis, with associated extrarenal deposition of calcium oxalate.^{1–5} Deposits can involve many tissues including the heart, and conduction disturbances or tachyarrhythmias are the main clinical manifestations of cardiac involvement.^{6–10} Primary oxalosis usually manifests in childhood with hematuria or renal stones and progresses to renal insufficiency and death before or during early adulthood. Onset of symptoms in adulthood is very rare.

We report the case of a young man with primary oxalosis who had cardiac deposits of calcium oxalate and in whom a cardioembolic stroke was the initial presentation of cardiac involvement. To our knowledge, no similar cases have been reported.

Case Report

A 34-year-old man was admitted 2 days after the acute onset of right hemiparesis and aphasia. He had a history of renal colic at age 8 years and a duodenal ulcer treated with cimetidine at age 24

years. Three sisters had nephrolithiasis. No risk factors for atherosclerosis were evident.

Cardiac physical examination was normal; systemic blood pressure was 130/80 mm Hg. Electrocardiography showed nonspecific ventricular repolarization abnormalities. Chest roentgenography showed a broad calcific shadow inside the cardiac silhouette. Computed tomography of the brain revealed a left frontotemporal infarction. Left carotid angiography, performed on admission, showed occlusion of a frontal branch of the middle cerebral artery, in the absence of proximal atherosclerotic lesions (Figure 1). Results of carotid echotomography were normal. Two-dimensional echocardiography (ATL MK 300 IC, phased-array sector scanner) showed heavy diffuse calcifications inside the left ventricle, with involvement of the interventricular septum and the papillary muscles. Moderate thickening of the left ventricular walls was also evident (Figures 2 and 3). Several 24-hour Holter recordings revealed only sporadic supraventricular premature contractions.

Results of laboratory investigations, including parathyroid hormone radioimmunoassay, serum and urinary calcium, phosphate, and uric acid, were normal. Renal function and serial samples of blood pH were normal. The urinary oxalic acid excretion was 64.7 mg/24 hr (normal range, 13–30 mg/24 hr). During hospitalization, the patient had an attack of renal colic on the right side associated with the passing of a calcium oxalate calculus. Echography of the kidneys revealed numerous bilateral calculi with scattered deposits of crystalline material. Thoracic and abdominal computed tomography confirmed the presence of intracardiac calcifications

From the Divisions of Cardiology (G.D.P., M.R., G.P.) and Neurosurgery (A.A.), Bellaria Hospital and the Endocrinology Unit (G.A.Z.), Department of Medicine, Maggiore Hospital, Bologna, Italy.

Supported by CRS Research Grant 336/85 from Regione Emilia-Romagna, Italy.

Address for correspondence: Giuseppe Di Pasquale, MD, Divisione di Cardiologia, Ospedale Bellaria, Via Altura 3, 40139 Bologna, Italy.

Received April 5, 1989; accepted May 2, 1989.

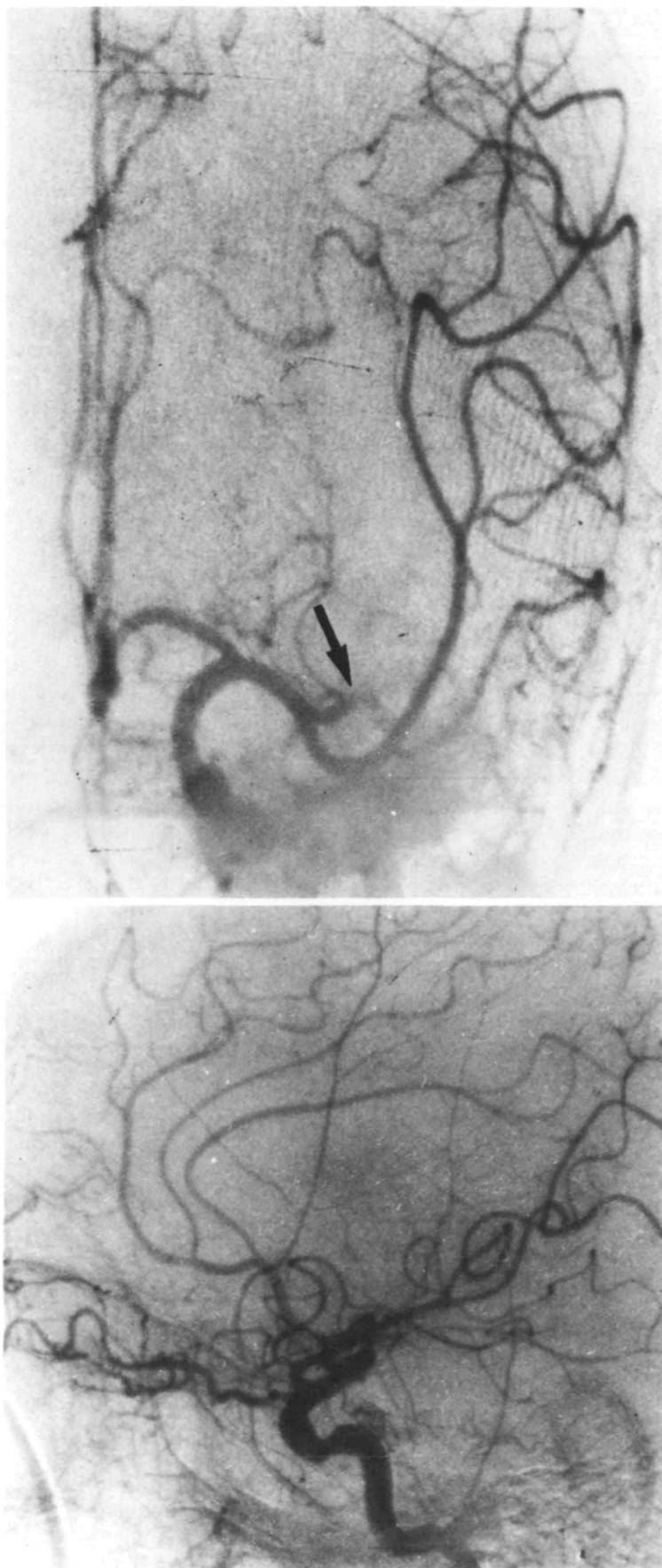


FIGURE 1. *Left carotid angiograms in anteroposterior (top) and lateral (bottom) views demonstrating occlusion of main branch of middle cerebral artery (arrow).*

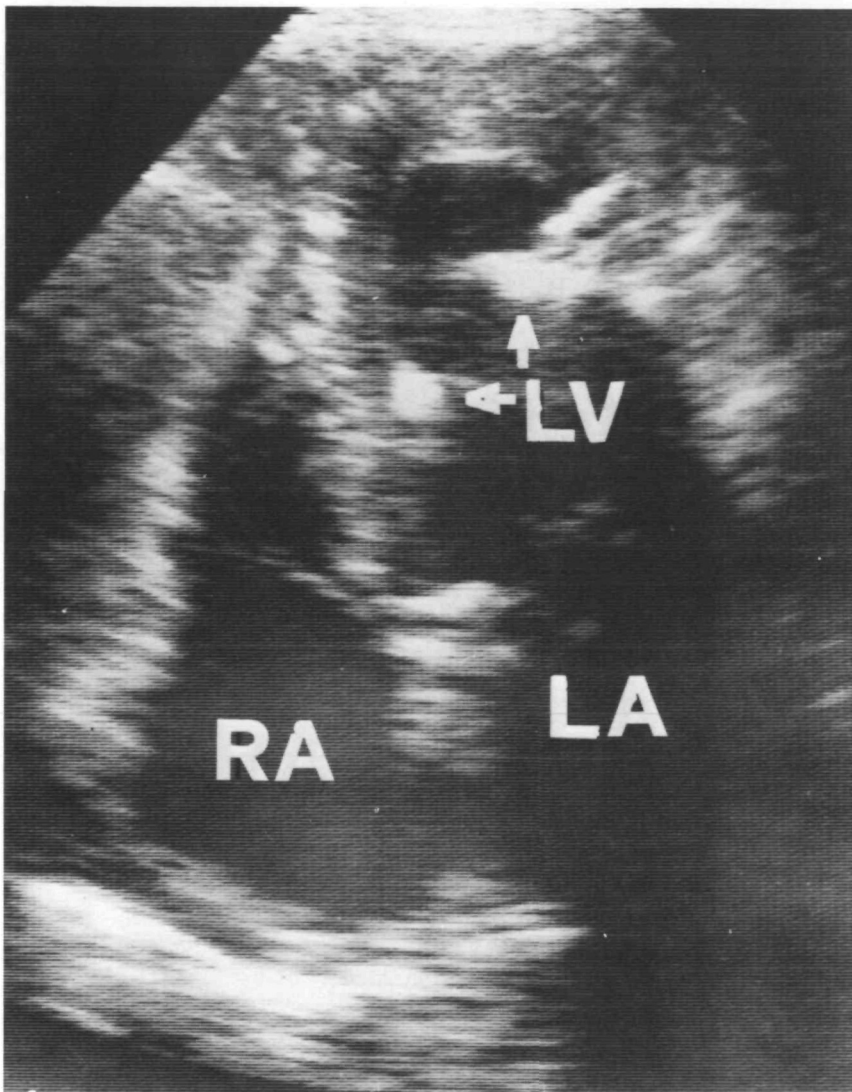


FIGURE 2. Two-dimensional echocardiogram from apical four-chamber view showing heavy calcifications at level of papillary muscles (arrows). RA, right atrium; LA, left atrium; LV, left ventricle.

and bilateral caliceal and intraparenchymal calcifications of the kidneys; a calcification of the colon was also evident. Both echograms and a computed tomogram of the parathyroids were normal. The patient was discharged moderately disabled under treatment with antiplatelet drugs and pyridoxine.

Discussion

The clinical and laboratory features of our patient are characteristic of primary oxalosis. He had recurrent nephrolithiasis and calcium oxalate calculi, as did three siblings. He also had nephrocalcinosis and extrarenal deposition of material presumed to be calcium oxalate in several tissues, including the heart. The presumptive diagnosis of primary oxalosis is also supported by the evidence of high urinary excretion of oxalic acid in the absence of abnormalities of laboratory investigations, including serum calcium, pH, and renal function indexes, or any other cause of secondary hyperoxaluria.

A causal relation between deposits of calcium in the left ventricle and stroke is suggested by clinical

and radiographic findings. The clinical features suggesting embolization include the abrupt onset of maximal neurologic deficit in an active young man without atherosclerotic risk factors. The angiographic features that reinforce the diagnosis of cardiogenic embolism are the occlusion of a branch of the middle cerebral artery in the absence of atherosclerotic lesions proximal to the occlusion.

In previous reports, the clinical signs of cardiac involvement secondary to oxalosis were conduction disturbances, probably related to deposits in the conduction system, and tachyarrhythmias.⁶⁻¹⁰ Our patient was studied by several 24-hour Holter recordings and never showed the phenomena of cardiac block or arrhythmias. Moreover, he never had symptoms such as dizziness or syncope suggestive of brady-tachyarrhythmias. An origin of stroke related to cardiac arrhythmias was therefore unlikely in this case. It is conceivable that the mechanism of stroke was the dislodgement of fragments of calcium oxalate from the heart. In fact, calcific cerebral embolization is a well-known complication in

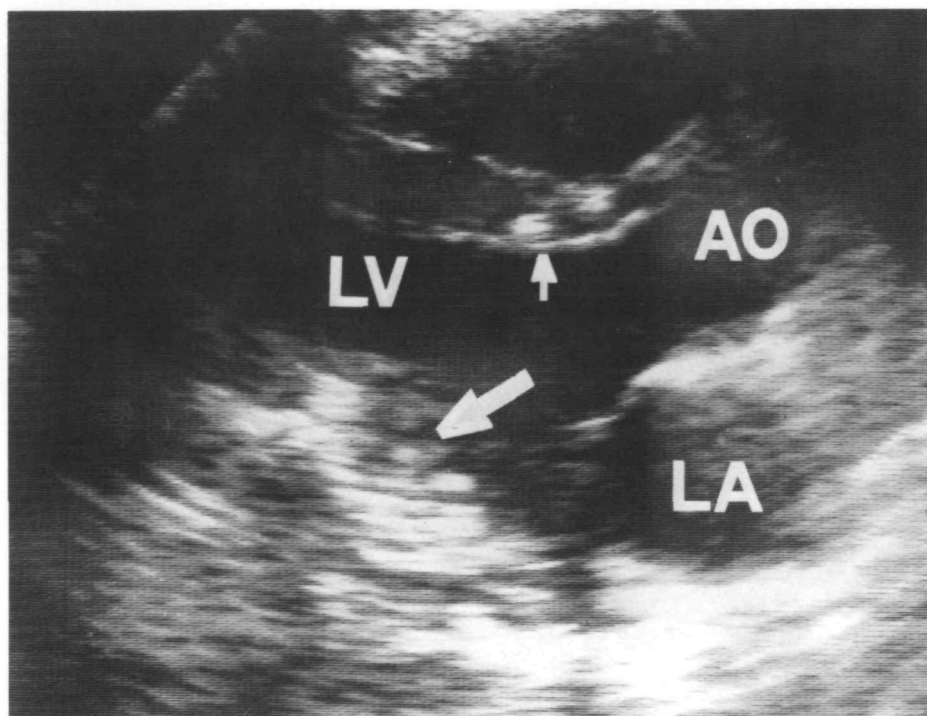


FIGURE 3. Two-dimensional echocardiogram from parasternal long-axis view showing heavy calcifications inside left ventricle, with involvement of interventricular septum and posterior wall (arrows). AO, aorta; LA, left atrium; LV, left ventricle.

other calcific cardiac lesions such as mitral anulus calcification and calcific aortic stenosis.

In conclusion, cardiac oxalosis should be taken into account as a rare occult cardiac source of cerebral embolism. The cardiac involvement in patients with primary oxalosis can be totally silent unless arrhythmias manifest. Our observation, therefore, suggests the need to perform two-dimensional echocardiography in every patient with unexplained stroke to detect possible occult cardiac abnormalities.

References

1. Wyngaarden JB, Elder TD: Primary hyperoxaluria and oxalosis, in Stanbury JB, Wyngaarden JB, Fredrickson DS (eds): *The Metabolic Basis of Inherited Disease*. New York, McGraw-Hill Book Co, 1966, p 189
2. Williams HE, Smith LH Jr: Disorders of oxalate metabolism. *Am J Med* 1968;45:715-722
3. McLaurin AW, Beisel WR, McCormick GJ, Scalettar R, Herman RH: Primary hyperoxaluria. *Ann Intern Med* 1961; 55:70-76
4. Stauffer M: Oxalosis: Report of a case with a review of the literature and discussion of the pathogenesis. *N Engl J Med* 1960;263:386-391
5. Boquist L, Lindqvist B, Östberg Y, Steen L: Primary oxalosis. *Am J Med* 1973;54:673-681
6. Slama R, Josso F, Antoine B: Manifestations myocardique de l'oxalose. *Arch Mal Coeur* 1960;53:917-929
7. Coltart DJ, Hudson R: Primary oxalosis of the heart: A cause of heart block. *Br Heart J* 1971;33:315-319
8. West RR, Salyer WR, Hutchins GM: Adult-onset primary oxalosis with complete heart block. *Johns Hopkins Med J* 1973;133:195-199
9. Tonkin AM, Moud HG, Mathew TH, Sloman JG: Primary oxalosis with myocardial involvement and heart block. *Med J Aust* 1976;1:873-876
10. Massie BM, Bharati S, Scheinman MM, Lev M, Desai J, Rubeson E, Schmidt W: Primary oxalosis with panconduction cardiac disease: Electrophysiologic and anatomic correlation. *Circulation* 1981;64:845-852

KEY WORDS • calcium oxalate • cardiovascular disorders • echocardiography