

CASE REPORT

Missing the point: self-inflicted traumatic brain injury in psychosis

Phelan E Maruca-Sullivan,¹ Matthew N Goldenberg,¹ David C Cone,² Justine Ciarleglio²

¹Department of Psychiatry, Yale University, New Haven, Connecticut, USA

²Department of Emergency Medicine, Yale University, New Haven, Connecticut, USA

Correspondence to

Dr Phelan E Maruca-Sullivan, phelan.maruca@yale.edu

Accepted 2 December 2016

SUMMARY

A 36-year-old man was brought to the emergency department by emergency medical services after being found acting unusually at a gas station with blood on his head and clothing. He presented acutely psychotic and reported that he had a pen in his head. Medical evaluation was notable for a superficial puncture wound to the right temple, and he was medically cleared for psychiatric evaluation. After he developed nausea and headache later that evening, the CT scan revealed a temporal bone fracture, pneumocephalus, intraparenchymal haemorrhage and the presence of a metal pen tip lodged in the brain parenchyma. The full nature of the injury went undiscovered in the emergency department for 16 hours due to the superficial appearance of the injury and his acute psychosis with prominent delusional thought content and disorganisation. He underwent craniotomy with removal of the pen and subsequent hospitalisation for intravenous antibiotics, followed by a prolonged psychiatric hospitalisation for psychosis.

was, though he later told emergency department (ED) staff that he was trying to make his way from Boston to New York. The transporting paramedics reported to ED staff that the patient had eloped from a psychiatric facility.

In the ED, the patient was initially evaluated by a physician's associate and a supervising physician. He reported that he had stabbed himself in the head with a pen. His physical examination was notable for superficial puncture sites to the right temple with a small haematoma but no bony tenderness, crepitus, step-offs or jaw misalignment suggestive of significant penetrating trauma. He denied visual symptoms, nausea or vomiting, neck pain, rhinorrhoea, trismus, or headache. An ocular examination was benign. He was alert and oriented to person and hospital with no cranial nerve deficits. Medical staff noted the patient to be paranoid, stating "they are out there to get me, you don't see them" and refusing medication of any kind for fear he would "get hooked on it". Given the apparent superficial nature of his injury, otherwise unremarkable physical examination, and the lack of any additional criteria for imaging of the patient's brain, he was given medical clearance and was transferred to the psychiatric emergency room for further evaluation and treatment of his mental status.

While in the psychiatric ED the patient was evaluated by a psychiatrist. The patient reported that he had driven from out of state "to get away from the way [his] life is right now". When asked specifically about the stabbing and potential suicidal intent, he stated "I guess, I'm not sure". He was vague in his history saying only that "something is not right". He continued to assert occasionally that he had a pen in his head but was inconsistent in his reporting about having stabbed himself. At first he told staff that he had bent over in his car and the pen 'ended up in his head', then later said he stabbed himself multiple times and could feel the pen in his head. He intermittently expressed frustration about no one doing anything about the pen in his head, but would quickly move on to other topics. He believed that people he did not know were attempting to get him in trouble with the police and accused his family of plotting against him as well. He expressed significant guilt for benign activities like asking strangers for directions and described hopelessness about being able to escape his situation. As in the medical ED, he was again found to be fully oriented with no cranial nerve deficits. His concern about being followed was thought to be a paranoid delusion, and he displayed no insight into his psychotic symptoms.

BACKGROUND

This case highlights the difficulty inherent in evaluating and treating the medical symptoms of certain psychiatric patients. Physicians, especially those not trained in psychiatry, face considerable challenges in determining the reliability of information obtained from psychiatric patients. Our patient's delusional and disorganised mental status contributed to a delay in the diagnosis and treatment of a potentially life-threatening injury. The case raises important questions about how best to evaluate and assess medical symptoms by psychiatric patients.

CASE PRESENTATION

Our patient is a 36-year-old man previously unknown to our health system who was brought to the hospital by emergency medical services on an involuntary police paper requesting medical examination. Police had found the patient at a gas station, acting erratically and throwing things in the trash, with blood on his head and clothing. He told the police that people were after him and said he had thrown his wallet and cell phone out of his car window while driving. Police and the paramedics noted minor swelling on the right side of his face, and the patient acknowledged having stabbed himself in the head with a pen, which he told police was still in his head. The police report states that the patient did not seem to know where he



CrossMark

To cite: Maruca-Sullivan PE, Goldenberg MN, Cone DC, et al. *BMJ Case Rep* Published online: [please include Day Month Year] doi:10.1136/bcr-2016-216767

As part of his psychiatric examination, collateral information was obtained from his mother via phone. According to her, the patient had been seen in another hospital for anxiety 2 days prior to this presentation. He was kept overnight and referred to a partial hospitalisation programme but did not follow-up. Neither she nor the patient was able to provide further information about this visit, and records from that hospital were not immediately available to ED staff. His family had not seen him since his discharge from that hospital and had been worried about his whereabouts. She described him as increasingly paranoid over the preceding several months starting in the fall of 2015 when he had been involved in a traffic stop during which he had refused to give police his identification. He had continued to ruminate about this incident since that time and was frequently concerned that unknown persons were following him and that they and his family were working with the police to harass him.

His mother reported that the patient had been diagnosed with Attention Deficit Hyperactivity Disorder (ADHD) as a child but had no other formal diagnoses or treatment except for the aforementioned recent hospital visit. He had not received medication during that hospitalisation and had never before taken psychiatric medication. He had no history of substance abuse and no known medical problems. He did have a family history of bipolar disorder. A urine toxicology screen was negative.

Given the patient's delusional thought content and disorganised behaviour, he was given a diagnosis of an unspecified psychotic disorder and was placed on an involuntary psychiatric commitment for inpatient hospitalisation. A more specific diagnosis was not possible in the ED given the patient's level of disorganisation and limited collateral information. The differential included a primary psychotic disorder (schizophrenia, schizophreniform disorder, schizoaffective disorder), a mood disorder with psychotic features, substance-induced psychosis or psychosis secondary to another medical condition. He remained in the ED awaiting inpatient psychiatric hospitalisation and was offered antipsychotic medication, which he refused.

About 16 hours after initial presentation to the ED, the patient reported nausea and vomited once. Given these new symptoms and his self-inflicted head injury, CT scan was ordered which revealed fracture of the anterior right middle cranial fossa with associated pneumocephalus, intraparenchymal haemorrhage and a foreign body consistent with a broken pen tip lodged in the right temporal lobe (figures 1 and 2).

INVESTIGATIONS

During his initial presentation to the ED, the patient underwent a physical examination but no imaging studies were performed. After he developed nausea and vomiting in the psychiatric ED, the following studies were obtained:

CT of the head without intravenous contrast:

Penetrating foreign object most consistent with a broken pen as detailed, extending through the anterior right middle cranial fossa with associated pneumocephalus and intraparenchymal haemorrhage in the right temporal lobe. Evaluation for intracranial vascular injury is limited on this non-contrast examination. CT angiography (CTA) is recommended for further evaluation.

CTA of the head with and without intravenous contrast:

1. When compared with the concurrent non-contrast head CT examination at 0500 hours, slightly enlarged intraparenchymal haemorrhage along the trauma tract extending within the right temporal lobe with associated pneumocephalus as well as unchanged metallic foreign body with

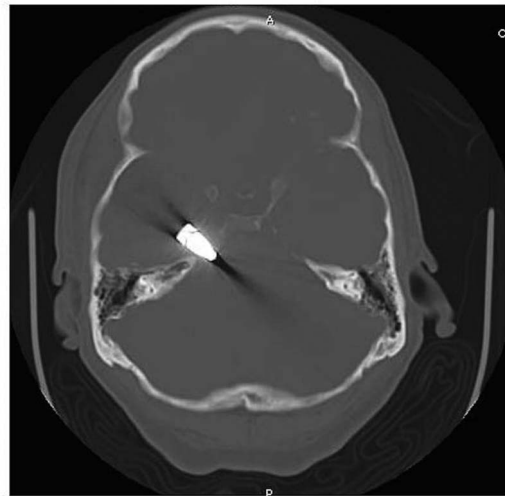


Figure 1 CT images showing penetrating foreign object consistent with a 2 cm broken pen tip and 4.1 cm radiolucent object extending through the anterior right middle cranial fossa and into the right temporal lobe parenchyma with associated pneumocephalus and intraparenchymal haemorrhage.

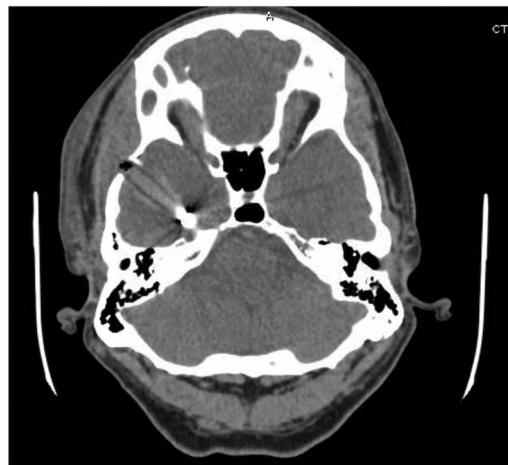

Figure 2 CT images showing penetrating foreign object consistent with a 2 cm broken pen tip and 4.1 cm radiolucent object extending through the anterior right middle cranial fossa and into the right temporal lobe parenchyma with associated pneumocephalus and intraparenchymal haemorrhage.

the tip just above the right petrous apex. Metallic streak artefact limits complete evaluation of the surrounding tissue; however, there is suspect mildly displaced fracture of the petrous apex. No evidence of arterial intracranial vascular injury.

2. No vascular occlusion, haemodynamically significant stenosis, saccular aneurysm, dissection or vascular malformation of the intracranial arterial circulation.

Angiography:

1. Foreign body noted in region of right petrous apex.
2. No apparent arterial injury.

DIFFERENTIAL DIAGNOSIS

Schizophrenia, bipolar disorder with psychotic features, schizoaffective disorder, schizophreniform disorder, delusional disorder, psychotic disorder secondary to a medical condition,

substance-induced psychotic disorder, unspecified schizophrenia spectrum disorder

TREATMENT

The patient was transferred back to the medical ED where he was seen by a neurosurgeon, and was started on antibiotics. The patient underwent urgent craniotomy for removal of the foreign body. He was hospitalised for further evaluation and treatment of his injury. He was followed by the psychiatry consult service and started antipsychotic medication, including haloperidol. Once medically stable, he was transferred to the psychiatric hospital for additional treatment of his psychosis. Further observation and collateral information revealed a history of irritable mood, decreased sleep, distractibility and impulsivity in addition to his psychotic symptoms. This, along with his family history, led to a diagnosis of bipolar disorder with psychotic features and the team added valproic acid to the patient's medication regimen.

OUTCOME AND FOLLOW-UP

During his hospitalisation the patient's psychotic symptoms slowly but progressively improved. He became more appropriate and significantly less paranoid. His insight into his symptoms improved greatly, and he was eventually able to appreciate that he had a mental illness. He expressed motivation for ongoing treatment and medication adherence. He was discharged home after psychiatric hospitalisation (about 1 month after his initial presentation/injury) to his family's care with outpatient psychiatric follow-up.

Of note, the patient in this case did describe during his psychiatric hospitalisation feeling for some years that his thinking was not quite right and had sought mental health treatment on at least five occasions in the past 10 years. Each time he was unable to obtain an evaluation or establish regular care. He cited long wait times, insurance issues, lack of available providers and feeling unsure of where to continue looking. Though the ED would have been available to this patient at any time, his account highlights the difficulties some patients face attempting to navigate a labyrinthine outpatient system of mental healthcare.

DISCUSSION

With the deinstitutionalisation of psychiatric care in recent decades, the demand on outpatient, community-based and ED services has increased dramatically. Appropriate psychiatric care in the ED requires collaboration between emergency medicine, psychiatry, nursing, hospital administration and others. A standard practice is for psychiatric patients to receive medical clearance from emergency medicine prior to psychiatric interventions. Medical clearance of psychiatric patients has been an area of extensive study and can be a complicated process.

Medical clearance is a necessary step in the care of psychiatric patients to ensure that an organic process requiring medical treatment is not the underlying cause of a behavioural or psychiatric disturbance. This practice also ensures that no concurrent medical illnesses preclude safe and appropriate transfer to a psychiatric facility.¹ Several studies have demonstrated that routine laboratory or radiographic studies are of little benefit, costly and unlikely to provide further diagnostic clarity or alter the course of treatment.²⁻⁵ American College of Emergency Physicians guidelines for medical clearance of psychiatric patients thus recommend against routine screening and include only a thorough history and physical examination.⁶ The ideal scenario is that each patient's evaluation in the ED will be individually tailored

and that more detailed evaluation including laboratory or radiographic studies will be ordered only when required, for instance, in those with abnormal vital signs, substance abuse, new or unusual onset of psychiatric symptoms, concurrent medical symptoms, and the elderly.⁵⁻⁷

Unfortunately, several studies have found that the medical evaluation of psychiatric patients in the ED may not always meet this expectation. In a recent retrospective study, only 52% of psychiatric patients had a full set of vital signs documented during their medical evaluations in the ED, and complete central nervous system evaluations were documented in only 3.6% of patients age 18-30, 23.7% of patients age 30-50 and 11.8% of patients over 50 years of age.⁸ An earlier retrospective study reviewed charts of 64 patients inappropriately transferred to a psychiatric facility with unrecognised medical emergencies. Their findings suggest that the greatest oversights in care were failure to perform a mental status examination (100% of patients) or a complete physical examination (43.8% of patients), and failure to obtain indicated laboratory or radiological studies (34.4% of patients). Less often, patients had abnormal vital signs that were not addressed (7.8% of patients) or were in need of neuroimaging that was not obtained (3.1% of patients).⁹

The case presented here serves to highlight one example of a near-miss occurring at least in part because of concurrent mental illness. Although the patient reported having a pen in his head on several occasions during his visit, physicians did not find that self-report reliable, in part because it was such an unusual symptom, the physical examination did not seem consistent with such a traumatic event and the patient had a disorganised thought process and delusional thought content. This case highlights the complexity inherent in evaluating patients with psychiatric illness, but there is little available literature examining the specific interpersonal challenges or specific psychiatric symptoms that correlate with poor outcomes. Several studies have demonstrated worse outcomes for general medical issues in psychiatric patients and lower rates of preventative interventions in this population. For instance, one study showed that hospitalised patients with concurrent diagnoses of schizophrenia or bipolar disorder are significantly less likely than matched, non-psychiatrically ill controls to be diagnosed, to receive recommended treatment, or to receive counselling for medical conditions such as diabetes, hypertension, hyperlipidaemia, obesity and tobacco use disorders.¹⁰ The study does not comment on the underlying cause but suggests a difference in the doctor-patient interaction.

Our case raises questions about how best to optimise and improve medical assessment and evaluation of psychiatric patients with active psychotic symptoms. Indeed, psychiatric patients may struggle to effectively describe their symptoms and providers not specifically trained in treating the mentally ill may struggle to obtain a thorough history or complete physical examination in this population. Therefore, for psychiatric patients with concurrent medical symptoms, it may be appropriate in some cases to broaden the differential and to be more exhaustive in a search for medical comorbidities. In certain cases, more inclusive standards and lower thresholds for ordering studies may be required than for non-psychiatric patients presenting with similar symptoms but the ability to more clearly describe their symptoms.

It is also likely that the concept of 'medical clearance' itself may be an imprecise term and cause some confusion among providers. Some physicians may use it to indicate that there is no active medical condition, others to indicate that the current

Reminder of important clinical lesson

medical issues are stable, others to indicate only that the patient's medical issues are unlikely to be contributing to the current psychiatric symptoms, and still others to indicate that though a medical aetiology is likely, it is no longer in need of active treatment.^{11 12} The term may also inadvertently compartmentalise care in a way that prevents opportunities for non-psychiatric providers to improve their skills in the evaluation of psychiatric patients and for psychiatrists to retain and expand on their skills in evaluating for organic aetiologies and managing medical comorbidities in the emergency setting.¹³

Learning points

- ▶ Medical clearance of psychiatric patients in the emergency setting can be a complicated process involving the collaboration of several specialties.
- ▶ Patients with certain psychiatric symptoms including psychosis can seem unreliable to medical staff in their reporting of symptoms.
- ▶ Current guidelines for medical clearance of psychiatric patients in the emergency setting are narrow, recommending only a physical examination and thorough history.
- ▶ Some psychiatric patients may warrant more extensive evaluations and physicians may need to keep a broad differential diagnosis in order to avoid overlooking serious medical comorbidities, the reporting of which may be confounded by concurrent psychiatric illness.
- ▶ The concept of 'medical clearance' itself can have multiple definitions that vary widely and may be a source of confusion among providers.

Contributors All authors were involved in direct patient care and clinical decision-making for this case as well as the decision to pursue publication. PEM-S

wrote the original manuscript with assistance in drafting from MNG and critical revision by MNG, DCC and JC. All authors gave final approval of the manuscript for publication.

Competing interests None declared.

Patient consent Obtained.

Provenance and peer review Not commissioned; externally peer reviewed.

REFERENCES

- 1 Zun LS. Evidence-based evaluation of psychiatric patients. *J Emerg Med* 2005;28:35–9.
- 2 Parmar P, Goolsby CA, Udompanyanan K, *et al*. Value of mandatory screening studies in emergency department patients cleared for psychiatric admission. *West J Emerg Med* 2012;13:388–93.
- 3 Amin M, Wang J. Routine laboratory testing to evaluate for medical illness in psychiatric patients in the emergency department is largely unrevealing. *West J Emerg Med* 2009;10:97.
- 4 Kroll DS, Smallwood J, Chang G. Drug screens for psychiatric patients in the emergency department: evaluation and recommendations. *Psychosomatics* 2013;54:60–6.
- 5 Janiak BD, Atteberry S. Medical clearance of the psychiatric patient in the emergency department. *J Emerg Med* 2012;43:866–70.
- 6 Lukens TW, Wolf SJ, Edlow JA, *et al*. Clinical policy: critical issues in the diagnosis and management of the adult psychiatric patient in the emergency department. *Ann Emerg Med* 2006;47:79–99.
- 7 Gregory RJ, Nihalani ND, Rodriguez E. Medical screening in the emergency department for psychiatric admissions: a procedural analysis. *Gen Hosp Psychiatry* 2004;26:405–10.
- 8 Szpakowicz M, Herd A. "Medically cleared": how well are patients with psychiatric presentations examined by emergency physicians? *J Emerg Med* 2008;35:369–72.
- 9 Reeves RR, Pendarvis EJ, Kimble R. Unrecognized medical emergencies admitted to psychiatric units. *Am J Emerg Med* 2000;18:390–3.
- 10 Briskman I, Bar G, Boaz M, *et al*. Impact of co-morbid mental illness on the diagnosis and management of patients hospitalized for medical conditions in a general hospital. *Int J Psychiatry Med* 2012;43:339–48.
- 11 Zun LS. Pitfalls in the care of the psychiatric patient in the emergency department. *J Emerg Med* 2012;43:829–35.
- 12 Tucci V, Siever K, Matorin A, *et al*. Down the rabbit hole: emergency department medical clearance of patients with psychiatric or behavioral emergencies. *Emerg Med Clin North Am* 2015;33:721–37.
- 13 Weissberg MP. Emergency room medical clearance: an educational problem. *Am J Psychiatry* 1979;136:787–9.

Copyright 2016 BMJ Publishing Group. All rights reserved. For permission to reuse any of this content visit <http://group.bmj.com/group/rights-licensing/permissions>. BMJ Case Report Fellows may re-use this article for personal use and teaching without any further permission.

Become a Fellow of BMJ Case Reports today and you can:

- ▶ Submit as many cases as you like
- ▶ Enjoy fast sympathetic peer review and rapid publication of accepted articles
- ▶ Access all the published articles
- ▶ Re-use any of the published material for personal use and teaching without further permission

For information on Institutional Fellowships contact consortiasales@bmjgroup.com

Visit casereports.bmj.com for more articles like this and to become a Fellow