

Posterior hippocampal stroke presenting with transient global amnesia

Federica Naldi, Simone Baiardi, Maria Guarino, Luca Spinardi, Fabio Cirignotta & Andrea Stracciari

To cite this article: Federica Naldi, Simone Baiardi, Maria Guarino, Luca Spinardi, Fabio Cirignotta & Andrea Stracciari (2016): Posterior hippocampal stroke presenting with transient global amnesia, *Neurocase*, DOI: [10.1080/13554794.2016.1270329](https://doi.org/10.1080/13554794.2016.1270329)

To link to this article: <http://dx.doi.org/10.1080/13554794.2016.1270329>



Published online: 22 Dec 2016.



Submit your article to this journal [↗](#)



Article views: 4



View related articles [↗](#)



View Crossmark data [↗](#)

Posterior hippocampal stroke presenting with transient global amnesia

Federica Naldi^{a*}, Simone Baiardi^{a,b*}, Maria Guarino^a, Luca Spinardi^c, Fabio Cirignotta^{a,b} and Andrea Stracciari^a

^aNeurology Unit, S. Orsola-Malpighi University Hospital, Bologna, Italy; ^bDepartment of Biomedical and Neuromotor Sciences, University of Bologna, Bologna, Italy; ^cDiagnostic and Interventional Neuroradiology Unit, S. Orsola-Malpighi Hospital, Bologna, Italy

ABSTRACT

The acute onset of isolated amnesia is an intriguing challenge for neurologist, because the lack of associated signs can be misleading for diagnosis. The most common cause is transient global amnesia (TGA), a benign condition, but rarely it results from abuse of substance/alcohol or cerebrovascular diseases. In the latter, the brain region involved is the hippocampus. We describe a patient with presenting symptoms of TGA, but affected by an ischemic hippocampal stroke. The computed tomography angiography helped the etiologic diagnosis showing an hemodynamic stenosis of the posterior P2P segment. Interestingly, neuropsychological features were consistent with those found in patients suffering TGA.

ARTICLE HISTORY

Received 25 February 2016
Accepted 5 December 2016

KEYWORDS

Stroke; hippocampus;
global transient amnesia;
neuropsychology;
neuroimaging

Introduction

Transient global amnesia (TGA) is a clinical syndrome characterized by sudden onset of transient anterograde and retrograde amnesia of variable extension, without consciousness impairment or other cognitive disturbances (Arena & Rabinstein, 2015). Patients usually exhibit stereotyped behavior, such as asking the same question over and over again, in the absence of consciousness disorders and remarkable neurological deficits. The symptoms resolve within 24 h and recurrence is rare (Arena & Rabinstein, 2015).

The pathophysiology of TGA is still not completely understood and several etiological factors have been proposed including vascular origin, epileptic or migrainous mechanisms, venous congestion, and psychological disturbances, but pathogenic hypotheses are still a matter of debate (Bartsch & Deuschl, 2010). Moreover, the occurrence of TGA-like episodes has been observed after the intake of several substances (alcohol, benzodiazepines, marijuana) (Stracciari, Guarino, Crespi, & Pazzaglia, 1999).

The diagnosis is still clinical, according to Caplan and Hodges criteria (Caplan, 1985; Hodges & Warlow, 1990).

While isolated TGA is considered a benign syndrome, it may be the presenting symptom of a serious underlying condition. Therefore, beyond an accurate clinical evaluation, patients with TGA should undergo comprehensive diagnostic testing including computed tomography (CT) of the brain and electroencephalography in the emergency department setting. When the symptoms last more than 24 h and there are no confirmatory tests, magnetic resonance imaging of the brain with diffusion-weighted imaging (MRI-DWI) sequences, oxygenation status, serum electrolytes, glucose, and a toxicology screen should be performed. A comprehensive cardiac evaluation including electrocardiogram and echocardiography, lipid panel and vascular studies (magnetic resonance

angiography, CT angiography, carotid duplex ultrasonography, and transcranial Doppler ultrasonography) should be considered in patients with vascular risk factors.

Here we describe the case of a patient who clinically presented with an episode of typical TGA but with an unusual duration (more than 24 h), which proved to be due to ischemic stroke in the posterior hippocampus.

Case report

An 82-year-old female presented with acute onset of amnesia, mild confusion, perplexity, perseveration, and disorientation in space and time. She had a medical history relevant for hypertension and the concomitant medications were benazepril (10 mg/day) and hydrochlorothiazide (12.5 mg/day).

At the time of first observation, 6 h after the onset of the symptoms, her blood pressure was 170/80 mmHg and heart rate was 85 bpm. Neurological examination revealed short-term verbal memory impairment as well as a retrograde amnesia extending to the day prior to the initial onset of the symptoms, without focal neurological signs or deficits. Her daughter confirmed the absence of consciousness impairment and excluded other cognitive disturbances other than amnesia. During the amnesic phase, an electroencephalogram was unremarkable, particularly, epileptic abnormalities were ruled out. Non-enhanced CT of the brain revealed hypo-density of the right posterior hippocampus suggestive of acute ischemic stroke. The diagnosis was confirmed by a subsequent brain MRI, which displayed signal alteration involving the hippocampus and the para-hippocampal gyrus of the right hemisphere, associated with signs of chronic vascular encephalopathy (Figure 1(a,b)). The CT angiography documented a fetal origin of right posterior cerebral artery (PCA) with a focal, hemodynamic stenosis of the posterior P2P segment (also known as ambient segment) (Figure 1(c,d)).

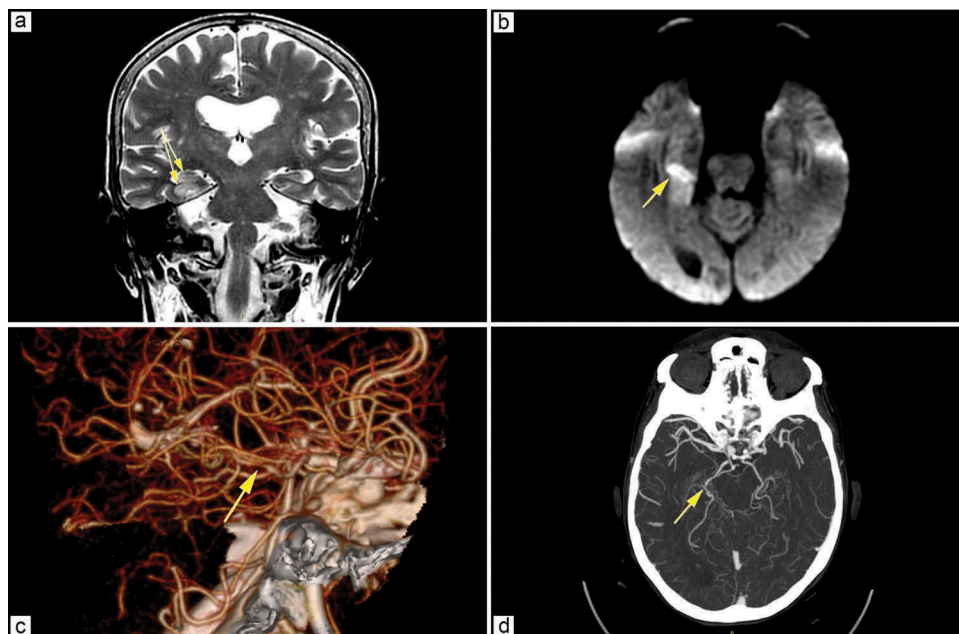


Figure 1. Brain MRI displays signal hyperintensity of right hippocampus and para-hippocampus on Fluid Attenuated Inversion Recovery (a) and DWI (b) sequences (see yellow arrows). A focal stenosis (about 3 mm) of the P2P segment of right posterior cerebral artery is documented by CT angiography [3-D (c) and Maximum Intensity Projection (d) reconstruction; yellow arrows].

The memory defect receded after 48 h and left a blank for the acute episode. Neuropsychological assessment, performed 12 days after the disease onset, revealed only the impairment in the delayed verbal memory recall at Rey Auditory Verbal Learning Test (Table 1). Work-up investigating the embolic etiology of the event, which included electrocardiogram monitoring for occult atrial fibrillation and echocardiography, was noncontributory. The patient was discharged with an antiplatelet (acetylsalicylic acid 100 mg/day) and antihypertensive treatment, without residual neurological deficits. At the 1-month follow-up, the patient was neurologically normal.

Discussion

Ischemic stroke may rarely present with TGA. Cases of “ischemic” TGA have been reported with lesions on the unilateral or bilateral hippocampus (Bhai, Biffi, Bakhadirov, & Prasad, 2014; Carota, Lysandropoulos, & Calabrese, 2012; Connelly, Chen, & Kwan, 2015; Kostić et al., 2015; Marinkovic, Lyytinen, Valanne, Niinikuru, & Pekkonen, 2012; Nishiyori, Nishida, Shioda, Suda, & Kato, 2014; Ott & Saver, 1993) and less frequently in the splenium of the corpus callosum (Saito, Rimura, Minematsu, Shiraishi, & Nakajima, 2003), in the fornix (Gupta, Kantor, Tung, Zhang, & Albers, 2015), in the cingulate

Table 1. Neuropsychological assessment performed after 12 days from the disease onset. The only abnormal test involves the long-term verbal memory recall (Rey Auditory Verbal Learning Test).

Test (range)	Raw score	Corrected score ^a	Cutoff	Equivalent score ^b
MMSE (0–30)	27	26.3	25	–
Attention				
-Visual search (0–60)	48	53	31	4
-Stroop test: time in sec	27	12.25	36.92	4
-Errors	0	–	4.24	4
Verbal memory (Rey Auditory Verbal Learning Test)				
-Immediate recall (0–75)	28	38.1	28.53	3
-Delayed recall (0–15)	1	4.3	4.69	0
Language				
-Phonological words fluency (words beginning with F,A,S)	36	41.7	17.35	4
-Verbal semantic fluency	36	42	25	4
-Phrase construction (0–25)	14	18.2	8.72	2
Abstract reasoning				
- Raven's colored progressive matrices (1947) (0–36)	23	27.1	18.96	3
Visual spatial memory				
-Immediate visual memory (0–22)	16	17.9	13.85	2
-Corsi's blocks (0–9)	4	4.5	3.75	3
Praxis				
- Copy of designs (0–12)	12	–	7.18	4

^aScores corrected for age, gender, and schooling.

^bEquivalent score classifies the performance on a five-point scale (range 0–4): 0 corresponds to a performance lower than the one-tailed tolerance limit of population with 95% confidence interval and 4 to a score higher than the median value of the population, while scores 1–3 are intermediate. MMSE - Mini-Mental State Examination.

gyrus (Gallardo-Tur, Romero-Godoy, de la Cruz Cosme, & Arboix, 2014), or in the thalamic penetrating artery territory (Ott & Saver, 1993). The involvement of hippocampal structures is simple to understand in relationship with its pivotal role in memory processing. The prevalence of acute strokes isolated to the hippocampus is 0.03% in a case series of 6,800 patients affected by ischemic stroke (Kumral, Deveci, Erdoğan, & Enustun, 2015).

Because hippocampal vascular supply arise from the PCA, often the hippocampus is involved in larger territorial strokes with clinical consequences derived from involvement of adjacent structures rather than from the hippocampus itself (Kumral et al., 2015). Visual field deficits, weakness, confusion, and altered mental status are common leading clinical signs of hippocampal stroke; therefore, early phase phenotype is different compared to so-called *pure* or *idiopathic* TGA (Kumral et al., 2015; Szabo et al., 2009).

Lesions on the hippocampus could also be found in other disease different from stroke, including epilepsy, limbic encephalitis, and, rarely, also in pure TGA. Because the lesion neuroimaging pattern depends on etiology and there is a high rate of false negative on early CT scans, especially when trying to identify small areas of ischemia such as in the hippocampus (Adler, Warum, & Sapire, 2012; Pearce & Bogousslavsky, 2009), brain MRI could help in the differential diagnosis, when clinical diagnosis is challenging (Forster et al., 2012).

In particular, the DWI sequences with apparent diffusion coefficient mapping on MRI are useful in detection of small ischemic lesions, when the brain changes are not visible in the structural MRI (Enzinger et al., 2008; Holdstock, Mayes, Gong, Roberts, & Kapur, 2005).

Several imaging studies in TGA patients using high-resolution MRI, with optimized parameters, revealed focal, punctuate, hyperintense 1–5-mm lesions of the lateral hippocampus on DWI, in up to 85% of cases (Bartsch & Deuschl, 2010; Forster et al., 2012). The detection of ischemic lesions on DWI is time dependent, with maximum detection time frame within 48–72 h after clinical onset and persistence for 7–10 days, but eventually resolve (Bartsch, Alfke, Deuschl, and Jansen 2007; Scheel, Malkowsky, Klingebiel, Schreiber, & Böhner, 2012).

Szabo (Szabo et al., 2009) in a series of 54 patients with PCA territory stroke with hippocampal involvement recognized four possible patterns of hippocampal ischemic lesions on MRI-DWI: complete, lateral, dorsal, and small circumscribed lesions in the lateral hippocampus, but a relationship between topography and clinical presentation was not found. In all cases described, however, additional ischemic lesions in the posterior circulation were found and symptoms from lesions outside the hippocampus were most common, whereas amnesic deficits were prominent in only one sixth of patients.

Kumral et al. (2015), who focused his research on isolated hippocampal infarcts, described memory dysfunction in all patients ($n = 19$), together with other manifestations according to the site of infarction, including altered consciousness, visual hallucinations, dizziness, dullness, confusion, mood states, and behavioral changes. None of the patients had isolated memory deficits.

Our patient presented with clinical features of TGA as defined by diagnostic criteria, except for the duration of symptoms

(more than 24 h). Neuropsychological features were consistent with those found in patients suffering pure TGA (Gallassi et al., 1993). A lesion in the right hippocampus and para-hippocampal gyrus was detected early. Because of the duration of symptoms (not typical of TGA) and abnormal findings on first brain CT scan, MRI was performed to confirm an ischemic nature of the signal alteration. The mechanism probably involved was a P2P focal stenosis, ipsilateral to the hippocampal lesion. The cardiologic clinical evaluation, the electrocardiogram monitoring for occult atrial fibrillation, and echocardiography were unremarkable, excluding an embolic source.

Usually patients with TGA have no evidence for an increased rate of cerebrovascular risk factors (Enzinger et al., 2008), such as in our case, and the “vascular hypothesis” of TGA could not be stated for all cases.

This case, however, suggests that arterial ischemia could be the etiopathogenetic mechanism underlying also of the *pure* TGA phenotype. Considering the difficulty to make a precise diagnosis within 24 h, arterial imaging in both typical and quite atypical phenotypes could give important information for the early management of patients, especially when an ischemic etiology is confirmed.

Acknowledgment

The authors thank Cecilia Baroncini and Niamh Bernadette Casey who edited the English text.

Disclosure statement

No potential conflict of interest was reported by the authors.

References

- Adler, A. C., Warum, D., & Sapire, J. M. (2012). Transient global amnesia caused by hippocampal infarct: Case report and review of literature. *Clinical Imaging*, 36(5), 584–586. doi:10.1016/j.clinimag.2011.11.022
- Arena, J. E., & Rabinstein, A. A. (2015). Transient global amnesia. *Mayo Clinic Proceedings*, 90(2), 264–272. doi:10.1016/j.mayocp.2014.12.001
- Bartsch, T., Alfke, K., Deuschl, G., & Jansen, O. (2007). Evolution of hippocampal CA-1 diffusion lesions in transient global amnesia. *Annals of Neurology*, 62(5), 475–480. doi:10.1002/ana.21189
- Bartsch, T., & Deuschl, G. (2010). Transient global amnesia: Functional anatomy and clinical implications. *The Lancet Neurology*, 9(2), 205–214. doi:10.1016/S1474-4422(09)70344-8
- Bhai, S., Biffi, A., Bakhadirov, K., & Prasad, S. (2014). Complete anterograde amnesia from simultaneous bilateral hippocampal infarction. *The Neurohospitalist*, 4, 165–166. doi:10.1177/1941874414524795
- Caplan, L. R. (1985). Transient global amnesia. In P. J. Vinken, G. W. Bruyn, & H. Klawans (Eds.), *Handbook of clinical neurology* [revised series] (Vol. 1, pp. 205–218). Frederiks JAM, editors. Clinical neuropsychology. Amsterdam: Elsevier Science.
- Carota, A., Lysandropoulos, A. P., & Calabrese, P. J. (2012). Pure left hippocampal stroke: A transient global amnesia-plus syndrome. *Journal of Neurology*, 259(5), 989–992. doi:10.1007/s00415-011-6296-2
- Connelly, K. L., Chen, X., & Kwan, P. F. (2015). Bilateral hippocampal stroke secondary to acute cocaine intoxication. *Oxford Medical Case Reports*, 3(3), 215–217. doi:10.1093/omcr/omv016
- Enzinger, C., Thimary, F., Kapeller, P., Ropele, S., Schmidt, R., Ebner, F., & Fazekas, F. (2008). Transient global amnesia: Diffusion-weighted imaging lesions and cerebrovascular disease. *Stroke*, 39(8), 2219–2225. doi:10.1161/STROKEAHA.107.508655
- Forster, A., Griebel, M., Gass, M., Kern, R., Hennerici, M. G., & Szabo, K. (2012). Diffusion-weighted imaging for the differential diagnosis of

- disorders affecting the hippocampus. *Cerebrovascular Diseases*, 33(2), 104–115. doi:10.1159/000332036
- Gallardo-Tur, A., Romero-Godoy, J., de la Cruz Cosme, C., & Arboix, A. (2014). Transient global amnesia associated with an acute infarction at the cingulate gyrus. *Case Reports in Neurological Medicine*, 2014 (418180), 1–4. doi:10.1155/2014/418180
- Gallassi, R., Stracciari, A., Morreale, A., Lorusso, S., Rebucci, G. G., & Lugaresi, E. (1993). Transient global amnesia: Neuropsychological findings after single and multiple attacks. *European Neurology*, 33(4), 294–298. doi:10.1159/000116957. Retrieved from <http://www.ncbi.nlm.nih.gov/pubmed>
- Gupta, M., Kantor, M. A., Tung, C. E., Zhang, N., & Albers, G. W. (2015). Transient global amnesia associated with a unilateral infarction of the fornix: Case report and review of the literature. *Frontiers in Neurology*, 5 (291), 1–4. doi:10.3389/fneur.2014.00291
- Hodges, J. R., & Warlow, C. P. (1990). Syndromes of transient amnesia: Towards a classification. A study of 153 cases. *Journal of Neurology, Neurosurgery & Psychiatry*, 53(10), 834–843. doi:10.1136/jnnp.53.10.834 Retrieved from <http://jnnp.bmj.com>
- Holdstock, J. S., Mayes, A. R., Gong, Q. Y., Roberts, N., & Kapur, N. (2005). Item recognition is less impaired than recall and associative recognition in a patient with selective hippocampal damage. *Hippocampus*, 15(2), 203–215. doi:10.1002/(ISSN)1098-1063
- Kostić, S., Pasovski, V., Krsmanović, Z., Bošković, Z., Kostić, D., Jovanovski, A., & Jović-Stošić, J. (2015). Bilateral hippocampal infarction and amnesia: A case report. *Vojnosanitetski Pregled*, 72(6), 545–551. doi:10.2298/VSP140330015K Retrieved from <http://www.ncbi.nlm.nih.gov/pubmed>
- Kumral, E., Deveci, E. E., Erdoğan, C., & Enustun, C. (2015). Isolated hippocampal infarcts: Vascular and neuropsychological findings. *Journal of the Neurological Sciences*, 15(356), 83–89. doi:10.1016/j.jns.2015.06.011
- Marinkovic, I., Lyytinen, J., Valanne, L., Niinikuru, R., & Pekkonen, E. (2012). Bilateral hippocampal infarction as etiology of sudden and prolonged memory loss. *Case Reports in Neurology*, 4(3), 207–211. doi:10.1159/000345564
- Nishiyori, Y., Nishida, M., Shioda, K., Suda, S., & Kato, S. (2014). Unilateral hippocampal infarction associated with an attempted suicide: A case report. *Journal of Medical Case Reports*, 8, 219. doi:10.1186/1752-1947-8-219
- Ott, B. R., & Saver, J. L. (1993). Unilateral amnesic stroke. Six new cases and a review of the literature. *Stroke*, 24(7), 1033–1042. doi:10.1161/01.STR.24.7.1033
- Pearce, J. M., & Bogousslavsky, J. (2009). 'Les ictus amnésiques' and transient global amnesia. *European Neurologic*, 62(3), 188–192. doi:10.1159/000228263
- Saito, K., Rimura, K., Minematsu, K., Shiraishi, A., & Nakajima, M. (2003). Transient global amnesia associated with an acute infarction in the retrosplenium of the corpus callosum. *Journal of the Neurological Sciences*, 210(1–2), 95–97. doi:10.1016/S0022-510X(03)00015-7
- Scheel, M., Malkowsky, C., Klingebiel, R., Schreiber, S. J., & Bohner, G. (2012). Magnetic resonance imaging in transient global amnesia: Lessons learned from 198 cases. *Clinical Neuroradiology*, 22(4), 335–340. doi:10.1007/s00062-012-0140-7
- Stracciari, A., Guarino, M., Crespi, C., & Pazzaglia, P. (1999). Transient amnesia triggered by acute marijuana intoxication. *European Journal of Neurology*, 6(4), 521–523. doi:10.1046/j.1468-1331.1999.640521.x Retrieved from <http://www.ncbi.nlm.nih.gov/pubmed>
- Szabo, K., Forster, A., Jager, T., Kern, R., Griebbe, M., Hennerici, M. G., & Gass, A. (2009). Hippocampal lesion patterns in acute posterior cerebral artery stroke: Clinical and MRI findings. *Stroke*, 40(6), 2042–2045. doi:10.1161/STROKEAHA.108.536144