

Sequential ¹²³I-IMP-SPECT in Acute Infantile Hemiplegia

Yukiyoshi Shirasaka, MD,
Masatoshi Ito, MD, Takehiko Okuno, MD,
Tatsuya Fujii, MD, and
Haruki Mikawa, MD

Sequential ¹²³I-*N*-isopropyl-*p*-iodoamphetamine (IMP) single-photon emission computed tomography (SPECT) was performed in 2 patients with acute infantile hemiplegia. In both patients, low uptake of IMP was detected in the targeted abnormal hemisphere. The ¹²³I-IMP-SPECT findings indicative of a pathologic condition persisted even when the clinical findings and electroencephalographic abnormalities improved. Because of its sensitivity, noninvasiveness, and accurate reflection of the cerebral blood flow distribution, ¹²³I-IMP-SPECT is useful in the examination of acute infantile hemiplegia and in the evaluation of prognosis.

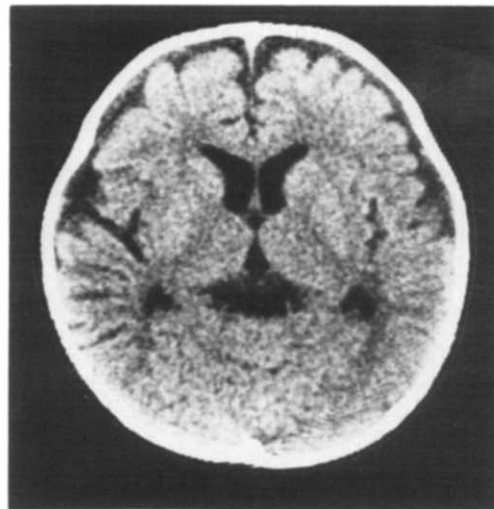Shirasaka Y, Ito M, Okuno T, Fujii T, Mikawa H. Sequential ¹²³I-IMP-SPECT in acute infantile hemiplegia. *Pediatr Neurol* 1989;5:306-10.

Introduction

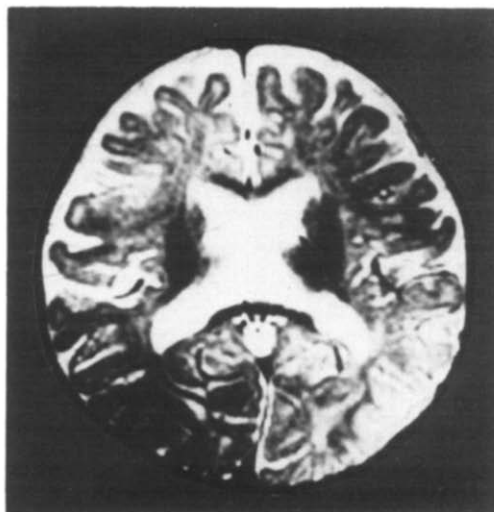
Acute infantile hemiplegia (AIH) is a syndrome in which a healthy child suddenly becomes hemiplegic without any obvious cause [1]. Pathogenetically, this syndrome is presumably associated with vascular abnormalities [2-4]. In the acute phase, several diagnostic methods, such as electroencephalography (EEG) [4], computed tomography (CT) [5], and angiography [2] have been used to examine the hemiplegic condition and establish its cause; however, problems remain because EEG findings usually are not specific enough to determine the cause, CT reveals only morphologic changes, and angiography is too inva-

sive — especially for children — and can reveal only morphologic changes in the vessels.

Recently, ¹²³I-*N*-isopropyl-*p*-iodoamphetamine (IMP) single-photon emission computed tomography (SPECT) has become clinically available [6-8]. This technique provides an accurate 3-dimensional picture of cerebral blood flow (CBF) distribution and is useful in detecting cerebral ischemia in the acute phase [7,9,10].



A



B

Figure 1. Patient 1: (A) CT on admission: symmetric, slight cortical atrophy and slight ventricular dilatation. (B) MRI 15 days after seizures began. T₂-weighted image (TR = 3,000 msec, TE = 80 msec) demonstrates only diffuse, slight atrophy with no signs of infarction or laterality.

From the Department of Pediatrics; Faculty of Medicine; Kyoto University; Kyoto, Japan.

Communications should be addressed to:
Dr. Shirasaka; Department of Pediatrics; Kyoto University;
54 Shogoin Kawahara-cho; Sakyo-ku, Kyoto 606, Japan.
Received May 31, 1989; accepted August 14, 1989.

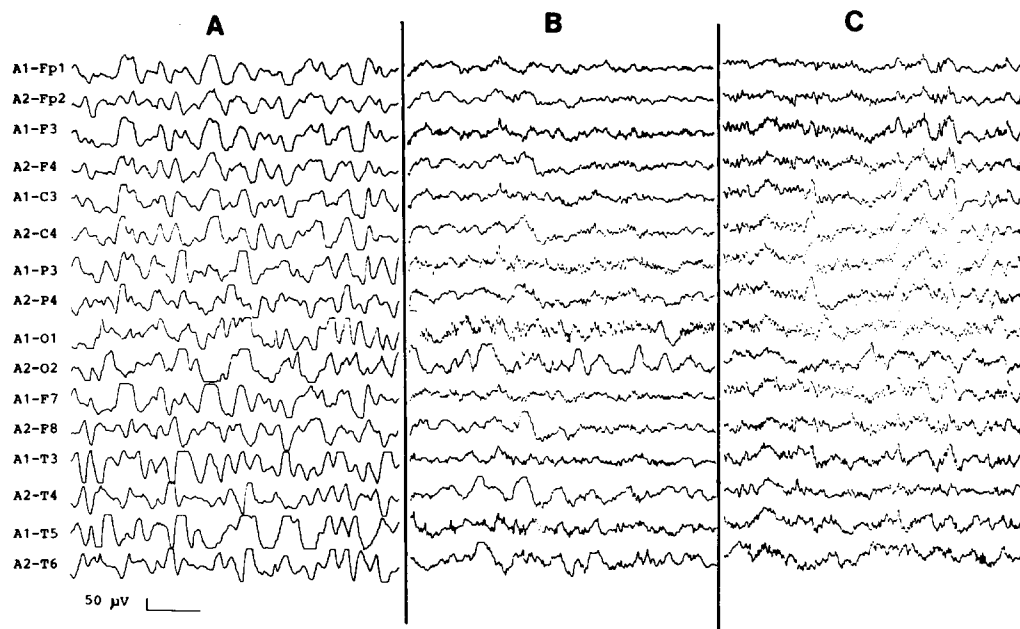


Figure 2. Electroencephalograms of Patient 1: (A) On admission: diffuse, slow waves and repetitive spikes are observed in the right occipital region. (B) Twelve days after seizures began: 1.5-3.0 Hz slow waves remain in the right hemisphere. (C) Forty-nine days after seizures began: slow waves have disappeared and no epileptic discharges are observed.

We report 2 AIH patients in whom SPECT was used for diagnosis and subsequent examinations.

Methods

The thyroid was blocked with iodine tablets before examination. IMP was obtained commercially (Japan Medipysics Co., Ltd.). The SPECT scanner was SET-030W (Shimazu) consisting of 3 detector rings, each having 128 sodium iodide crystals. ^{123}I -IMP, 1 mCi, was injected into a forearm vein. The patient was positioned in the gantry by aligning the bottom slice at 2 cm above the orbitomeatal (OM) line, so that 3 slices corresponding to 2, 5, and 8 cm above the OM line were obtained 5-20 min after injection, and 3 more slices corresponding to 3.5, 6.5, and 9.5 cm were obtained after another 15 min.

Case Reports

Patient 1. This 10-month-old boy was born at term with no perinatal complications. He developed normally and had no neurologic disorders until the onset of AIH. His paternal uncle had died during the infant's neonatal period of undetermined cause.

On the day before admission, the child developed a cough and rhinorrhea; on the morning of admission, he had a fever and diarrhea. That evening he had left clonic hemiconvulsions which continued for 30 min and were followed by postictal disturbed consciousness. Three hours later, left hemiconvulsions recurred and the eyes deviated to the left. Phenobarbital (100 mg) was administered by a local physician. Three hours later, the seizures subsided but the patient did not respond to his name and did not move his left arm or leg.

He was admitted to our hospital 7 hours after the onset of seizures. Temperature was 38.4°C. He did not cry but did move in response to pain. His face was apathetic and his eyes deviated to the left. The left extremities were flaccid and deep tendon reflexes were diminished on the left side. Neck stiffness was absent. Examination of blood, serum, urine, and cerebrospinal fluid (CSF) revealed no abnormalities. CT revealed slight cortical atrophy and slight ventricular dilatation with no lateralization (Fig 1A); contrast-enhanced CT demonstrated no lesion. Magnetic resonance imaging (MRI) demonstrated slight cortical atrophy, slight ventricular dilatation, and no pathologic lesions (Fig 1B). Subsequent CT also revealed no change when compared to the pre-

vious scan. Diffuse slow waves and repetitive right occipital spikes were observed on EEG (Fig 2A). Three days later, the fever ceased and erythema appeared. Exanthem subitum was diagnosed. The left hemiplegia gradually improved so that his left arm could move clumsily. Thereafter, this clumsiness disappeared. Twelve days after admission, EEG and ^{123}I -IMP-SPECT were performed. EEG still disclosed slow waves in the right hemisphere (Fig 2B) and the ^{123}I -IMP-SPECT revealed low, diffuse uptake of IMP in the right hemisphere (Fig 3A). Visual evoked potentials, somatosensory evoked potentials, and auditory brainstem responses were normal. Seven weeks after onset, EEG was normal (Fig 2C); however, the subsequent ^{123}I -IMP-SPECT revealed that a low uptake area remained in the area of the right anterior cerebral artery, although the laterality was markedly improved (Fig 3B). Seven months after onset, ^{123}I -IMP-SPECT demonstrated marked improvement; the low uptake of IMP in the right middle cerebral artery was unapparent, although the low uptake area remained in the area of the right anterior cerebral artery (Fig 3C).

Patient 2. This 11-month-old girl was the first of twins born at 34 weeks gestation, weighing 1,945 gm. There were no perinatal complications. She developed normally and there were no neurologic disorders until the onset of AIH. Family history was unremarkable. Eleven days before admission, she had fallen down a stairway from the second floor to the first floor and had cut the right side of her forehead. Her family physician observed no signs of intracranial hemorrhage. Five days before admission, her temperature rose to 39.5°C and she began to vomit. Vomiting was followed by brief, generalized clonic seizures every 3 sec. Her eyes deviated to the upper right. Four hours later, the seizures had changed into right hemiconvulsions with persistent eye deviation; she then was transported to our outpatient clinic.

She had right hemiplegia and could neither sit nor roll over. CT revealed compression of the trigone of the left lateral ventricle which may have been due to mild edema in the left hemisphere. Phenobarbital (40 mg/day) was administered. Two days before admission, her fever had dissipated and erythema had appeared. Exanthem subitum was diagnosed. The right hemiparesis improved the next day; EEG revealed δ -waves in the left hemisphere (Fig 4A).

She was admitted to our hospital because of prolonged right hemiparesis. She was alert and the right extremities were flaccid. Deep tendon reflexes were symmetric. The liver was palpable 4 cm below the costal margin. There were no other physical abnormalities. Blood,

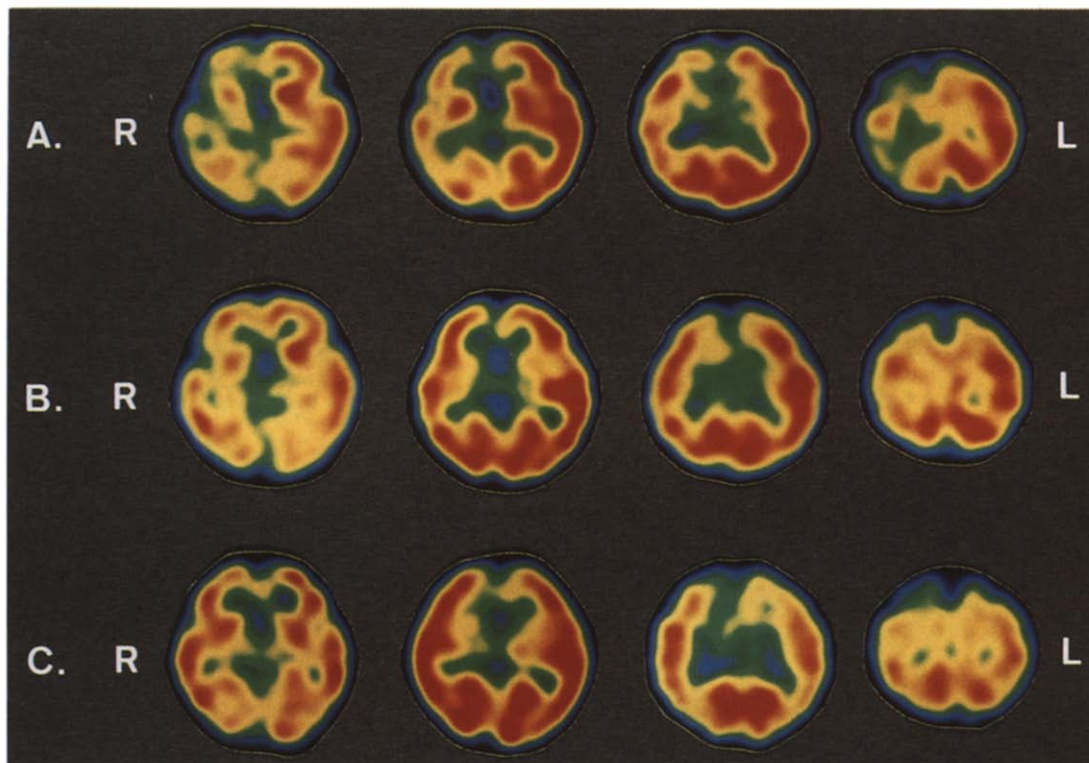


Figure 3. ^{123}I -IMP-SPECT of Patient 1. Slices are 3.5, 5.0, 6.5, and 8.0 cm above the OM line. The red-to-blue areas are indicative of high-to-low IMP uptake, respectively. (A) Twelve days after seizures began: IMP uptake is diffusely low in the right hemisphere. (B) Forty-six days after seizures began: IMP uptake laterality has markedly improved, but low uptake remains in the right anterior cerebral artery region. (C) Six months after seizures began: low IMP uptake in the right middle cerebral artery region has disappeared, but that in the right anterior cerebral artery region (superior frontal gyrus) remains.

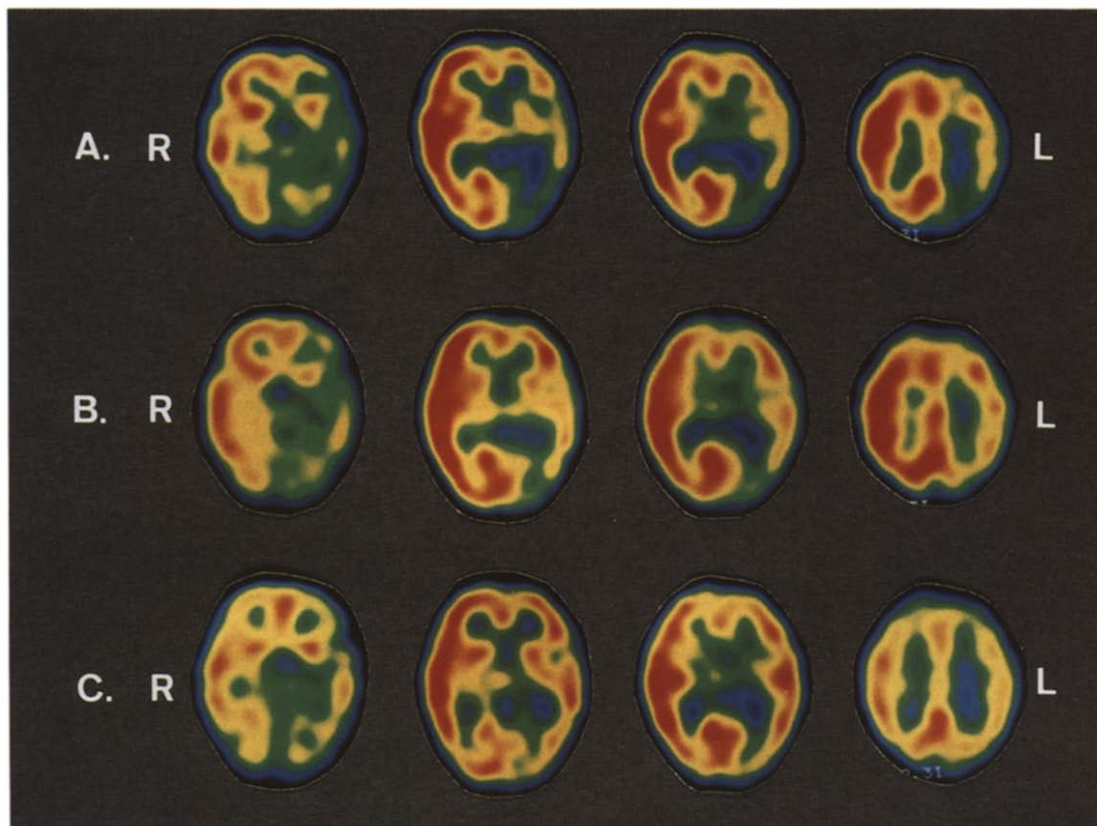


Figure 5. ^{123}I -IMP-SPECT of Patient 2. (A) Twelve days after seizures began: IMP uptake is low in the left parietal lobe, occipital lobe, part of the temporal lobe, and basal ganglia, especially in the thalamic region. (B) Thirty-nine days after seizures began: no laterality in the thalamus and IMP uptake remains low in the posterior portion of the left middle cerebral artery region. (C) Four months after seizures began: mild laterality, but marked improvement in IMP uptake.

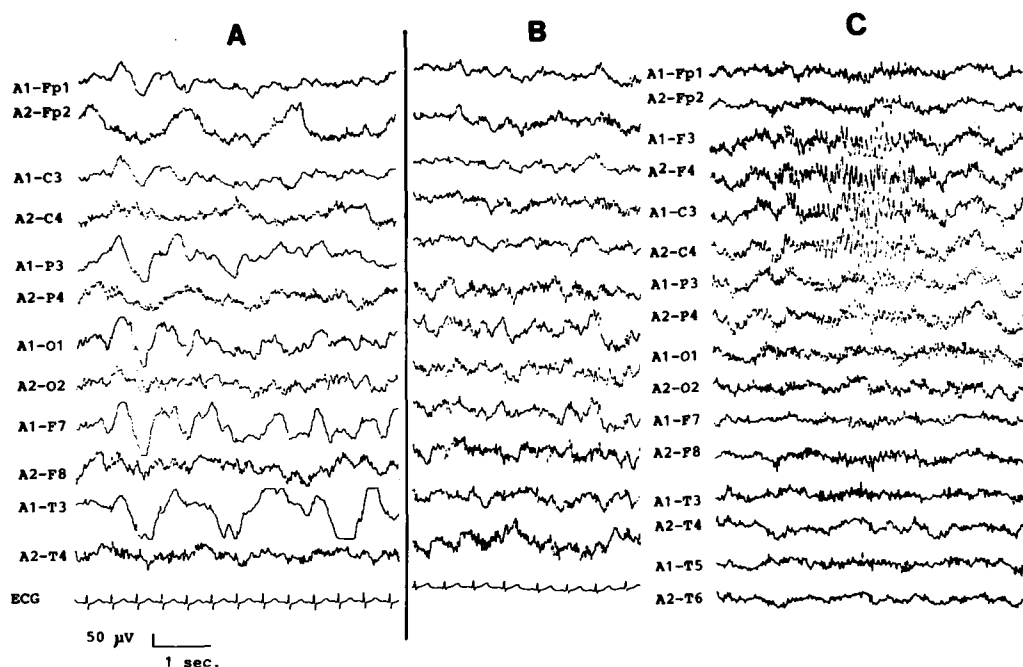


Figure 4. EEGs of Patient 2: (A) Four days after seizures began: diffuse δ -waves are observed in the left hemisphere. (B) Twelve days after seizures began: slow waves in the left hemisphere have decreased, but still remain. (C) Three months after seizures began: the findings are almost normal.

serum, urine, CSF, and electrocardiography (EKG) were normal. MRI performed 2 days after admission revealed no abnormalities. Her right arm and leg began to move on that day. EEG demonstrated improvement and the slow waves in the left hemisphere diminished (Fig 4B). ^{123}I -IMP-SPECT revealed that IMP uptake was low in the left temporal lobe and basal ganglia, especially in the thalamic region (Fig 5A). Two weeks later, the ^{123}I -IMP-SPECT revealed no laterality in the thalamus; however, IMP uptake in the posterior portion of left middle cerebral artery region remained low (Fig 5B). Two months later, EEG was almost normal (Fig 4C). ^{123}I -IMP-SPECT revealed marked improvement in the uptake in the left middle cerebral artery region (Fig 5C). Hemiplegia improved markedly, but slight clumsiness of her right hand remains. The latest CT revealed no asymmetry or other abnormality.

Discussion

In most AIH studies, EEG abnormalities are nonspecific [3]. When CT scans and MRIs are performed, frequently no specific abnormality is observed even later in the course. Angiography may reveal the etiology of brain ischemia in some AIH patients [4,11]; however, in some patients angiographic findings are normal even when CT scans and/or EEGs are abnormal [11,12]. Because angiography reveals only morphologic change in vessels, AIH with normal angiographic findings may be due to a functional vascular abnormality.

^{123}I -IMP-SPECT is a recently available technique by which changes in rCBF can easily be detected [10]. ^{123}I -IMP-SPECT has the advantage over positron emission tomography because of its lower cost and the absence of a need for a cyclotron [10]. Furthermore, it is superior to CBF scintigraphy because it is easier to use and provides an accurate picture of CBF distribution [9].

In our 2 patients, we found low IMP-uptake areas in regions that had been clinically suspected of being abnor-

mal, indicating the presence of focal ischemia. The clinical findings and results of blood, serum, urine, CSF, EKG, and EEG examinations did not reveal the cause of the ischemic insult [13]. The differential diagnosis includes Todd's palsy due to epileptic seizures because the uptake of IMP is low in the involved focal regions in the postictal state [9,10,14]; however, the absence of an epileptic history or epileptic discharges in the interictal EEGs, as well as prolonged, diffuse, low IMP uptake in a cerebral hemisphere, does not support this possibility. Although Patient 1 had no evidence of a preceding neurologic abnormality, CT and MRI scans demonstrated slight, diffuse cerebral atrophy. The possibility, thus, remains that these abnormalities may have some relation to the onset of AIH in this patient.

In our 2 patients, clinical signs and EEG abnormalities improved earlier than did ^{123}I -IMP-SPECT findings. Astrup et al. reported that there were 2 thresholds involved in the ischemic brain: the upper threshold involving electrical failure, which is expressed by EEG evidence of abnormal discharges, and the lower threshold involving energy and ion pump failure [15]. They hypothesized that CBF below the lower threshold would result in irreversible neuronal damage. In this instance, ^{123}I -IMP-SPECT can detect decreased CBF above the threshold of electrical failure. This finding indicates that even in the absence of clinical signs and EEG abnormalities, the occurrence of low IMP uptake indicates decreased CBF and the presence of a pathologic change in the cerebral vessels. Furthermore, ^{123}I -IMP-SPECT is a noninvasive and simple method of obtaining an accurate picture of the distribution of rCBF, proving to be most useful in the evaluation of AIH.

We wish to thank Dr. Sadataka Nishizawa and Dr. Yoshiharu Yonekura of the Radiology Department for their helpful comments and kind preparation of the radiologic records.

References

- [1] **Golden GS.** Cerebrovascular disease: Acute infantile hemiplegia. In: Swaiman KF, Wright FS, eds. *The practice of pediatric neurology*, 2nd ed. St. Louis: CV Mosby, 1982;773-6.
- [2] **Zilkha A, Mendelsohn F, Borofsky LG.** Acute hemiplegia in children complicating upper respiratory infections. *Clin Pediatr* 1976; 15:1137-42.
- [3] **Chiofalo N, Madson J, Fuentes A, Basauri L, Castro M.** Occlusive arterial disease of the child and young adult: Clinical electroencephalographical analysis of 26 cases. *Childs Brain* 1978;4:1-14.
- [4] **Hilal SK, Solomon GE, Gold AP, Carter S.** Primary cerebral arterial occlusion disease in children, Part I: Acute acquired hemiplegia. *Radiology* 1971;99:71-86.
- [5] **Okuno T, Takao T, Ito M, Konishi Y, Nakano S, Mikawa H.** Acute hemiplegia in childhood. *Prog Compt Tomogr* 1983;5:223-30.
- [6] **Winchell HS, Baldwin RM, Lin TH.** Development of I-¹²³-labeled amines for brain studies: Localization of I-¹²³-iodophenylalkyl amines in rat brain. *J Nucl Med* 1980;21:940-6.
- [7] **Kuhl DE, Barrio JR, Hung SC, et al.** Quantifying local cerebral blood flow by *N*-isopropyl-*p*-[¹²³I] iodamphetamine (IMP) tomography. *J Nucl Med* 1982;23:196-203.
- [8] **Hill TC, Holman BL, Lovett R, et al.** Initial experience with SPECT (single-photon-computed tomography) of the brain using *N*-isopropyl, I-¹²³-iodoamphetamine: Concise communication. *J Nucl Med* 1982;23:191-5.
- [9] **Uren RF, Magistretti PL, Royal HD, et al.** Single-photon emission computed tomography. A method of measuring cerebral blood flow in three dimensions (preliminary results of studies in patients with epilepsy and stroke). *Med J Aust* 1983;1:411-3.
- [10] **Maurer AH.** Nuclear medicine: SPECT comparisons to PET. *Radiol Clin North Am* 1988;26:1059-74.
- [11] **Zimmerman RA, Bilaniuk LT, Packer RJ, Goldberg HI, Grossman RI.** Computed tomographic arteriographic correlates in acute basal ganglionic infarction of childhood. *Neuroradiology* 1983; 24:241-8.
- [12] **Quagliari CE, Chun RWM, Cleeland C.** Movement disorders as a complication of acute hemiplegia of childhood. *Am J Dis Child* 1977;131:1009-10.
- [13] **Chatkupt S, Epstein LG, Rappaport R, Koenigsberger MR.** Cerebellar infarction of children. *Pediatr Neurol* 1987;3:363-6.
- [14] **Holman BL, Hill TC, Lee RGL, Zimmerman RE, Moore SC, Royal HD.** Brain imaging with radiolabeled amines. In: Freeman LM, Weissmann HS, eds. *Nuclear medicine annual*, 1983. New York: Raven Press, 1983;131-65.
- [15] **Astrup J, Siesjo BK, Syman L.** Thresholds in ischemia: The ischemic penumbra. *Stroke* 1981;12:723-5.