

SHORT REPORT

Acute Spontaneous Subdural Haematoma of Arterial Origin

GEORGE STEPHENSON & R. MYLES GIBSON

Department of Neurosurgery, The General Infirmary, Leeds, United Kingdom

Abstract

Spontaneous arterial subdural haematoma is arguably a rare condition. We report on three patients who presented with progressive neurological deficit or coma and who had been initially diagnosed as strokes. Explanations for the development of this condition are reviewed and it is suggested that it is not as rare as previously thought.

Key words: *Arterial origin, subdural haematoma, Sylvian fissure.*

Introduction

Sudden alteration of consciousness or development of neurological deficit in a previously healthy patient is commonly associated with a cerebrovascular event. Acute subdural haematoma is well known in head injured patients in association with traumatic laceration or contusion of the brain and tearing of bridging veins in the subdural space. Less frequent but well recognised is the acute subdural haematoma in the presence of cerebral aneurysm, arteriovenous malformation or coagulopathy. Less appreciated is the spontaneous variety associated with arterial rupture.

Here we add three further cases of spontaneous arterial subdural haematoma to the 20 cases so far reported in the literature.

Case 1

A previously well, 64-year-old male patient developed sudden severe headache while waiting to be served at his local bank. He sat down and subsequently collapsed on the floor. Witnesses thought he had a convulsion. He was taken to the casualty department of his local

hospital where he was found to be cyanosed and unresponsive to deep pain. His reflexes were brisk and his plantars upgoing. There was no external evidence of trauma to the head and his BP was recorded as 145/100 mmHg. He had no papilloedema or retinal haemorrhages on fundoscopy. He was admitted to the medical unit with a diagnosis of subarachnoid haemorrhage. Routine blood investigations, coagulation screen, chest radiograph and ECG were all reported as normal.

Three hours following admission he developed spontaneous extensor posturing and his pupils became pin point and unreactive. A computerised tomographic (CT) scan was obtained which revealed a right sided subdural haematoma with considerable midline shift (Fig. 1). There were no associated brain contusions or subarachnoid blood.

The patient was intubated and ventilated without any paralysing agents being required and transferred to the regional neurosurgical unit.

At emergency craniotomy the dura was found to be very adherent to bone. An extensive subdural clot was evacuated to reveal

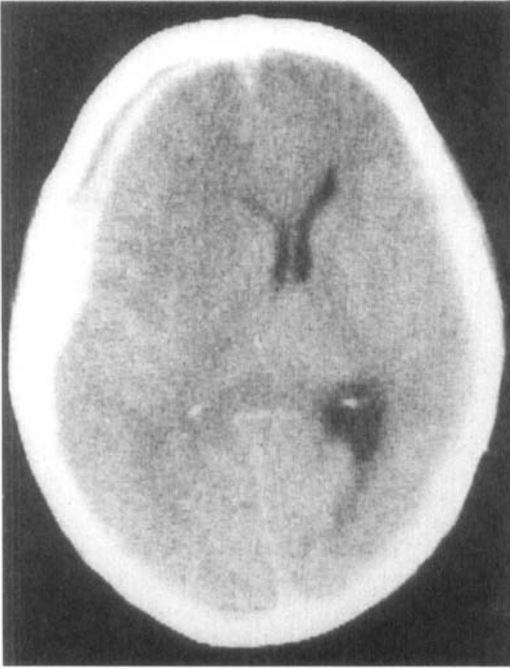


FIG. 1. Case 1: CT scan showing R sided subdural haematoma with brain shift.

a small bleeding cortical artery in the region of the Sylvian fissure. The rest of the brain appeared normal and no contusions or vascular malformations were noted.

The postoperative recovery was uneventful. The patient had a transient contralateral hemiparesis which resolved within days. Prior to discharge 3 weeks later the patient underwent four vessel angiography which did not reveal any abnormality.

Case 2

A 67-year-old male hospital inpatient awaiting myelography and suffering from polyarteritis nodosa was found on the floor by his bed at 3 a.m. He was conscious and orientated but had developed a left hemiparesis. He was not hypertensive and was taking prednisolone 10 mg per day. There was no sign of injury to his head and a skull radiograph did not show any abnormality. It was thought that he had suffered a stroke and neurological observations were commenced.

His condition deteriorated over the course of the next 6 hours and he became unrousable. A CT scan of the brain was obtained at this point which showed a right sided subdural haematoma with midline shift but no other brain injury.

He was transferred to the regional neurosurgical unit where an emergency craniotomy was performed. The dura was very adherent to the bone and the two were separated with the utmost difficulty. A subdural clot was evacuated to reveal a small spurting artery in the vicinity of the Sylvian fissure.

Postoperatively his hemiplegia rapidly resolved.

Case 3

A 66-year-old man, previously in good health, was observed standing reading his paper in the city railway station when he was seen to collapse on the floor. He was taken to the local Accident and Emergency department where he was found to be comatose with no response to external stimuli and to have small fixed pupils. No evidence of head injury could be elicited and a skull radiograph revealed no fractures. He was subsequently admitted to a general medical ward with the diagnosis of a cerebrovascular event. Three hours after admission his right pupil became fixed and dilated and a CT scan was obtained. This showed an extensive left parietal subdural haematoma with significant midline shift. Despite the evacuation of this as well as postoperative ventilation on the intensive care unit he succumbed 2 weeks later. A necropsy was performed which showed the cause of his death to be a subdural haematoma which was arterial in origin. It was assumed that this occurred as a spontaneous event as there was no associated brain laceration or contusion suggestive of trauma and no evidence of vascular malformation was found.

Discussion

Most subdural haematomas are thought to be venous in origin, secondary to torn bridging veins or venous sinuses. This view has been

challenged by a number of authors who propose that many acute and subacute traumatic subdural haematomas are arterial in origin¹⁻⁴. Shenkin⁵ found 61.5% were of arterial origin in his series of 39 traumatic subdural haematomas.

Non-traumatic or spontaneous arterial subdural haematoma may result from aneurysmal or arteriovenous malformation rupture^{6,7}, may be secondary to tumours of the dura mater^{8,9} or to Disseminated Intravascular Coagulation and other coagulopathies.

Spontaneous arterial subdural haematoma in the absence of the above conditions is a rarely reported event. Tokero *et al.*¹⁰ in a recent paper have proposed certain criteria that should be fulfilled before this diagnosis can be made. These are:

- (a) there should be no history of head trauma;
- (b) no damage to the underlying cortex;
- (c) no aneurysm or arteriovenous malformation around the affected artery; and
- (d) identification of a bleeding artery at operation.

Thus, reviewing the reported cases in the literature they concluded that only 20 could be identified which satisfied these criteria. They also noted that there was a male preponderance (80%) and the average age was 56 years (range 37-80). Only eight of the 20 were known hypertensives. Here we suggest a further three cases for inclusion in the list.

All our patients were over 60 years old and all were male which is in keeping with previously published reports. In two cases an arterial source in the region of the Sylvian fissure was found at operation and in our third case evidence of arterial bleeding was provided by *post mortem* studies.

Several hypotheses have been put forward to explain the development of these spontaneous subdural haematomas. Drake¹ in one of the earlier reports argued that spontaneous arterial rupture is impossible without some degree of trauma and suggests minor trauma that has gone unnoticed by the patient is responsible for the haemorrhage. He also considered but dismissed local arterial disease due to an

atheromatous plaque as a cause. There was no history of trauma in any of our cases.

Vance¹¹ coined the phrase 'firehose rupture' after a series of *post mortem* examinations in which he identified a cortical artery as the source of bleeding. He postulated that these rents were found in surface cortical arteries where a twig came off at right angles which represented an area of potential weakness. O'Brien² presented further histopathological evidence in support of the above hypothesis showing microscopic deficiency in the wall of the affected artery corresponding to the origin in a small branch. Moreover he found no evidence of previous adhesions between the dura and a cortical artery or of an arterial knuckle of a surface artery protruding through the arachnoid and adherent to the dura as suggested by Drake.

Finally although hypertension was present in some of the reported cases it is thought not to be an important predisposing factor¹².

None of our cases was a known hypertensive but in Case 3 the *post mortem* examination revealed changes in the heart consistent with chronic hypertension. In Cases 1 and 2 the dura was extremely adherent to the bone at craniotomy but no adhesions were noted between the dura and cortical vessels.

The mortality from this condition as judged by the hitherto reported cases is around 50%. This closely approximates that of its traumatic counterpart where the associated bruising and laceration of the brain combined with the resultant brain oedema soon lead to irreversible coma and tentorial herniation, whereas in the spontaneous variety the absence of brain oedema at the time of operation is a notable feature. One would expect the surgical treatment of spontaneous subdural haematoma from simple arterial rupture without associated brain injury to be more rewarding. The unexpectedly high mortality must be in part attributable to delay in recognition and prompt surgical treatment, and in part to the well recognised fact that the greatest surgical mortality in subdural haemorrhage occurs when the interval to coma is brief.

Talala & McKissock¹³ noted an ipsilateral

hemiparesis in all eight patients in their series. They attributed this to a supratentorial extra-axial mass causing compression of the contralateral pyramidal tracts against the tentorial edge (Kernohan's notch) in the absence of any intra-axial mass effect. They concluded that this constituted a clinical syndrome distinguishing the spontaneous subdural haematoma. This has not been our experience with two of our patients who had a hemiparesis.

The true incidence of non-traumatic subdural haematoma is not known at present. We believe it is not as rare as the reports so far have implied. We propose that this condition be considered in the differential diagnosis of the patient presenting with neurological deficit of sudden onset in whom no signs of a vascular aetiology such as previous hypertension, transient ischaemic attacks or myocardial infarction could be elicited. Features such as male sex, age over 55 and neurological deterioration should further alert one to the possibility of this diagnosis and lead to early investigation by computerised tomography scanning.

Address for correspondence: R. M. Gibson, M.D., F.R.C.S., Consultant Neurosurgeon, The General Infirmary at Leeds, Great George Street, Leeds LS1 3EX, U.K.

References

- 1 Drake CG. Subdural haematoma from arterial rupture. *J Neurosurg* 1961; 18:597-601.
- 2 O'Brien PK, Norris JW, Tator CH. Acute subdural haematoma of arterial origin. *J Neurosurg* 1974; 41:435-9.
- 3 Rengachary SS, Szymanski DC. Subdural haematoma of arterial origin. *Neurosurgery* 1981; 8:166-72.
- 4 Williams B. Subdural haematoma of arterial origin. *Lancet* 1971; 1:1074-5.
- 5 Shenkin HA. Acute subdural haematoma. *J Neurosurg* 1982; 57:254-7.
- 6 Clarke ES, Goody W. Ipsilateral third cranial nerve palsy as a presenting sign in acute subdural haematoma. *Brain* 1953; 76:266-78.
- 7 Kondziolka D, Bernstein M, Brugge K *et al.* Acute subdural haematoma from ruptured posterior communicating artery aneurysm. *Neurosurgery* 1988; 22:151-4.
- 8 Russel DS, Cairns H. Subdural false membrane or haematoma (pachymeningitis interna haemorrhagica) in carcinomatosis and sarcomatosis of the dura mater. *Brain* 1934; 57:32-48.
- 9 Turner DM, Graf CJ. Non-traumatic subdural haematoma secondary to dural metastasis. Case report and review of the literature. *Neurosurgery* 1982; 11:678-80.
- 10 Tokoro K, Nakajima F, Yamataki A. Acute spontaneous subdural haematoma of arterial origin. *Surg Neurol* 1988; 29:159-63.
- 11 Vance BM. Ruptures of surface blood vessels on cerebral hemispheres as a cause of subdural haemorrhage. *Arch Surg* 1950; 61:992-1006.
- 12 McDermott M, Fleming JFR, Vanderlinden G. *et al.* Spontaneous arterial subdural haematoma. *Neurosurgery* 1984; 14:13-18.
- 13 Talalla A, McKissock W. Acute spontaneous subdural haematoma. An unusual form of cerebrovascular accident. *Neurology* 1971; 21:19-25.